

Chronic Obstructive Pulmonary Disease in a Dressage Horse

Hyo-Hoon Jeong, Kei-Myung Ahn*, A-Ram Kim*, Ha-Jung Roh** and Tae-Ho OH¹

College of Veterinary Medicine, Kyungpook National University, Daegu 702-701, Korea

**Korea Racing Authority, Gwacheon 427-711, Korea*

*** Infectious Disease Department, College of Veterinary Medicine, University of Georgia, Athens, GA 30602, USA*

(Accepted: April 05, 2010)

Abstract : A 14-year-old gelded dressage horse weighing 500 kg was presented to the Equine Medical Center of the Seoul Racecourse of Korea Racing Authority (KRA) due to coughing and mucopurulent nasal discharge. The horse was initiated with empirical antibiotic in the first place. However, the clinical signs did not improve but were rather exacerbated even after 3 weeks of therapy. Extensive diagnostic procedures including transtracheal wash (TTW) fluid cytology were undertaken. The localized wheezes and crackles were auscultated and an increase in the amount of mucopurulent exudate in trachea was observed at endoscopy. Infiltration of neutrophils was observed in the TTW fluid cytology implying chronic obstructive pulmonary disease (COPD). Therefore, the systemic glucocorticoid therapy was to be given for 3 weeks with improved ventilation provided at the same time. The respiratory symptoms started to improve in 7 days of therapy and were fully resolved by when the therapy was terminated. The horse is clinically normal now and being monitored for development of any signs of chronic obstructive pulmonary disease.

Key words : Chronic obstructive pulmonary disease, glucocorticoid, horse, neutrophilic inflammation.

Introduction

Chronic obstructive pulmonary disease (COPD) is an allergic airway disease of horses which is also commonly called chronic alveolar emphysema, heaves, broken wind, recurrent airway obstruction (RAO) (1,2,11,12). The disease is generally associated with chronic cough, purulent nasal discharge, increased respiratory efforts, exercise intolerance and bronchial hypersecretion (1,5). The disease is known to be caused by exposure to various environmental allergens including moldy hay and straw (8,16) and they trigger an allergic reaction that is responsible for the clinical signs of COPD (12). The clinical signs of COPD are exacerbated when susceptible horses are exposed to organic dusts for a period of a few days, which is often the case when horses are housed in stables but the clinical signs and lung function usually return to baseline values within a week after being housed in a pasture (7,17). COPD is most frequently observed in mature subjects, which are riding horses mainly used for jumping, endurance, eventing and dressage implying horses working generally at submaximal intensities (1). The disease can be diagnosed based on the clinical signs, bronchoalveolar lavage (BAL), TTW and lung biopsy (14,18). COPD can be managed best if the host-allergen interactions are avoided (6). The topical and general glucocorticoids have been used to reduce the inflammatory cells involved in the immune reaction with bronchod-

ilators to reduce the bronchospasm and accelerate the removal of excess mucus production (18). A case of COPD of a dressage horse raised in Seoul Racecourse of Korea Racing Authority (KRA) is described in this report.

Case

A 14-year-old gelded dressage horse weighing 500 kg was presented to the Equine Medical Center of the Seoul Racecourse of KRA complaining coughing, mild tachypnea and mucopurulent nasal discharge with normal body temperature and pulse. CBC, serum chemistry, auscultation, upper respiratory endoscopy and bacterial culture were performed. The CBC and serum chemistry values were in normal ranges. Some mucopurulent discharge accumulation in trachea was observed at endoscopy. Adventitious wheezes and crackles were present at auscultation. Bacterial culture revealed some non pathogenic gram (+) and (-) bacteria with no clinical significance. The patient was initiated with empirical antibiotic, enrofloxacin at 5 mg/kg intramuscularly once a day in the first place. However, the clinical symptoms did not improve but were rather deteriorated even after 3 weeks of therapy. Coughing, heavy mucopurulent nasal discharge, tachypnea greater than 60/min even at rest, labored breathing during exercise and decreased performance were present. The body temperature and pulses were normal. The patient was alert and healthy other than the respiratory symptoms.

Extensive diagnostic procedures with additional transtracheal wash (TTW) fluid cytology were performed this time.

¹Corresponding author.
E-mail : thoh@knu.ac.kr

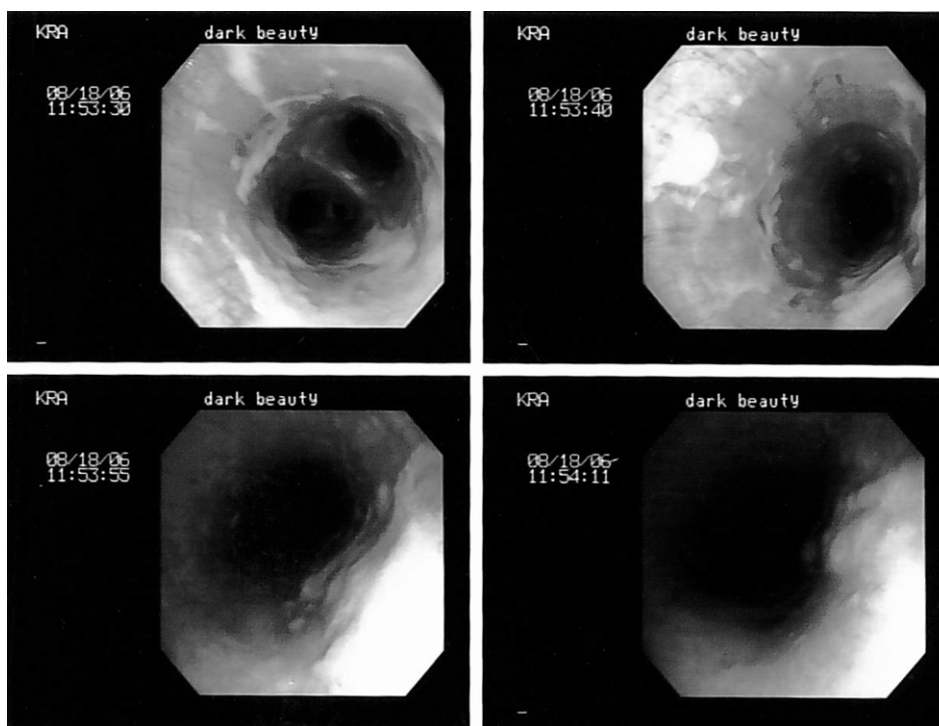


Fig 1. The endoscopic pictures of upper respiratory airway of the patient prior to the systemic glucocorticoid therapy. Note the heavy mucopurulent exudate throughout the entire trachea.

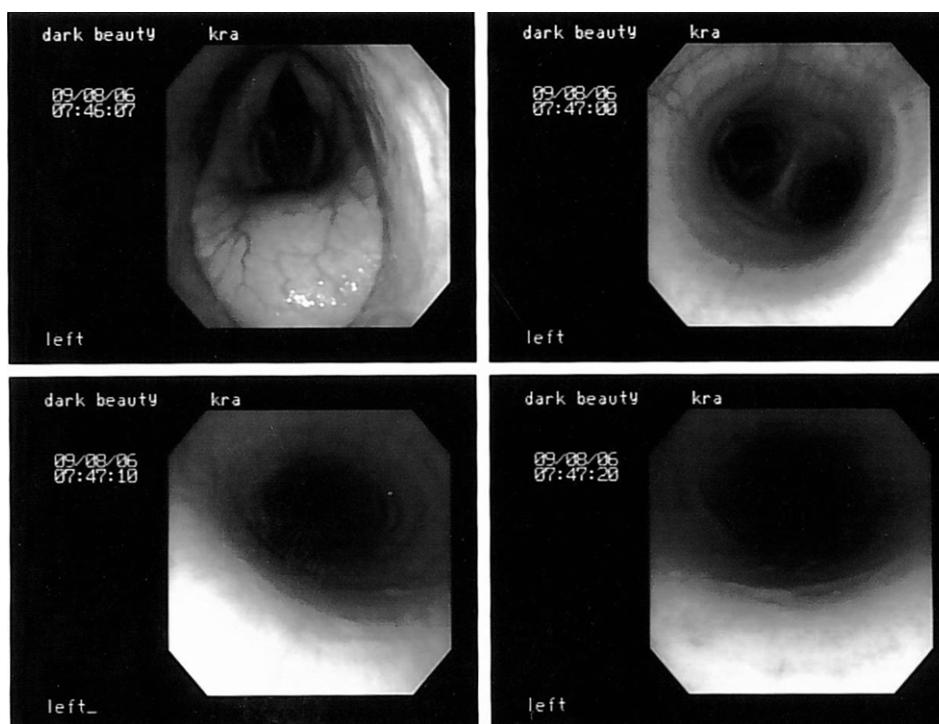


Fig 2. The endoscopic pictures of upper respiratory airway of the patient after 3 weeks of the systemic glucocorticoid therapy. Note the remarkable reduction in the amount of mucopurulent exudate.

Localized expiratory crackles and wheezes were still present at auscultation during rebreathing examination. Upper respiratory system examination utilizing the fiberoptic endoscopy

revealed increased amount of mucopurulent exudate in trachea compared to the first visit of the patient (Fig 1). The cytology of transtracheal wash (TTW) fluid contained numer-

ous neutrophils implying suppurative nonseptic inflammation. COPD was diagnosed based on the clinical signs and the results of the tests listed above.

The systemic glucocorticoid therapy was to be given for 3 weeks. Dexamethasone (Dexason[®], Handong Co., Korea) at 0.05 mg/kg was injected intramuscularly once a day for the initial 7 days, the dose was tapered to half for another week and then the medication was given alternate day basis for the rest of therapeutic period. At the same time, continuous efforts to improve air hygiene by increasing ventilation of the stables were made by the grooms. The clinical signs started to improve in 7 days of therapy and were fully resolved by when the therapy was terminated. The accumulation of mucopurulent exudate was remarkably reduced when confirmed by endoscopy after the therapy (Fig 2). The medication was given for one more week to prevent relapse of the symptoms. The horse is clinically normal now and being monitored for development of any signs associated with COPD.

Discussion

COPD can be diagnosed based on the clinical signs, auscultation, BAL, TTW and lung biopsy (9,15,18). The clinical signs of COPD vary with the severity of the condition. Horses with subclinical and mild COPD may have a chronic cough but have few abnormal findings on auscultation or endoscopy of the tracheobronchial tree (15). As the disease progresses, breathing sounds increase, there is an increase in tracheobronchial secretions that may contain an increased number of neutrophils, cough is more frequent, and horses become increasingly exercise intolerant. In the most severe form of COPD, cough is common, respiratory sounds are loud and wheezes develop, respiratory secretions are rich in neutrophils, and horses develop the characteristic expiratory abdominal effort known as heaves (2,4,10,13). In this case, the typical clinical signs of COPD including coughing with nasal mucopurulent discharge, tachypnea which was greater than 60/min even at rest, exercise intolerance with normal body temperature were observed. However, it is important that the clinicians consider the possibility of variations in the clinical symptoms when dealing with the COPD cases. In a previous study, the most common physical findings in horses with COPD were tachypnea and abnormal lung sounds but sometimes tachypnea was the only noticeable sign in a small percentage of horses with COPD (14).

TTW fluid analysis was useful for diagnosis of COPD in this case. In most cases of COPD, a neutrophilic inflammatory bronchiolitis results from hypersensitivity (type I and III) to inhaled antigens including molds and dusts existing in hay and beddings (14,18,19). The suppurative nonseptic inflammation indicated by neutrophilic infiltration in TTW fluid suggested us the possibility of COPD in this case. The TTW fluid cytology is considered to be worth to try in field when COPD is suspected.

Therapy of the disease usually comprises systemic and

inhalatory corticosteroids including dexamethasone or prednisolone and bronchodilators like clenbuterol and albuterol (18). The sole use of systemic dexamethasone at 0.05 mg/kg for 3 weeks provided an excellent clinical response without any adverse effect like laminitis which is a serious threat to the horses without any inhalation therapy or bronchodilators in this case.

In an effort to make improvements in air hygiene, the grooms were advised to increase ventilation of the stables it is believed that the clinical remission of the patient can be ascribed to this. The most important point to prevent COPD is thought to be elimination or reduction of exposure of the animals to the allergen that provokes the disease (12). There is an enormous variety of spores of molds and actinomycetes in hay and straw such as *Aspergillus fumigatus*, *Faenia rectivirgula* and *Thermoactinomyces vulgaris* (3). These spores have an aerodynamic diameter of 0.5-3.0 μm , small enough to be inhaled deep into the respiratory system. Thus, relocating the susceptible animals out of the stables to the pastures, providing less dusty bedding materials, feeding on hay with good quality, spraying or wetting hay fed, use of silage and haylage, pelleted and bracketed feed instead of hay and spraying grains with molasses to reduce the amount of dust in feed can decrease the animal-allergen interactions. The etiological agents as allergens which provoked the COPD could not be elucidated owing to lack of time and labors in this case. Further investigation on the environmental allergens in the stables of Seoul Racecourse is required to be able to improve the air hygiene more effectively

Although it's been known that COPD is more common in horses working generally at submaximal intensities, its incidence is highly variable affected by many factors (1). The clinicians are required to consider the possibility of COPD when dealing with horses with chronic respiratory inflammation although the incidence rate is thought to be low.

Conclusion

A chronic respiratory inflammation in a dressage horse was diagnosed as COPD based on the clinical signs and TTW fluid cytology. The systemic glucocorticoid therapy for 3 weeks was effective to control the clinical symptoms of COPD without any unwanted adverse effects. Further investigations on etiology and incidence rate are required to prevent the disease among horses raised in Seoul Racecourse of KRA.

References

1. Art T, Duvivier DH, Votion D, Anciaux N, Vandenput S, Bayly WM, Lekeux P. Does an acute COPD crisis modify the cardiorespiratory and ventilatory adjustments to exercise in horses? *J Appl Physiol* 1998; 84: 845-852.
2. Bracher V, Von Fellenberg R, Winder CN, Gruenig G, Hermann M, Kraehenmann A. An investigation of the incidence of chronic obstructive pulmonary disease (COPD) in random populations of Swiss horses. *Equine Vet J* 1991; 23:

- 136-141.
3. Clarke AF, Madelin T. Technique for assessing respiratory health hazards from hay and other source materials. *Equine Vet J* 1987; 19: 442-447.
 4. Cook WR. Chronic bronchitis and alveolar emphysema in the horse. *Vet Rec* 1976; 99: 448-451.
 5. Couetil LL, Rosenthal FS, DeNicola DB, Chilcoat CD. Clinical signs, evaluation of bronchoalveolar lavage fluid, and assessment of pulmonary function in horses with inflammatory respiratory disease. *Am J Vet Res* 2001; 62: 538-546.
 6. Cunningham FM, Dunkel B. Equine recurrent airway obstruction and insect bite hypersensitivity: Understanding the diseases and uncovering possible new therapeutic approaches. *Vet J* 2008; 177: 334-344.
 7. Derksen FJ, Robinson NE, Armstrong PJ, Stick JA, Slocombe RF. Airway reactivity in ponies with recurrent airway obstruction (heaves). *J Appl Physiol* 1985; 58: 598-604.
 8. Derksen FJ, Robinson NE, Scott JS, Stick JA. Aerosolized *Micropolyspora faeni* antigen as a cause of pulmonary dysfunction in ponies with recurrent airway obstruction (heaves). *Am J Vet Res* 1998; 49: 933-938.
 9. Freeman KP, Roszel JF, McClure JM, Mannsman R, Patton PE, Naile S. A review of cytological specimens from horses with and without clinical signs of respiratory disease. *Equine Vet J* 1993; 25: 523-526.
 10. Gillespie JR, Tyler WS. Chronic alveolar emphysema in the horse. *Adv Vet Sci Comp Med* 1969; 13: 59-99.
 11. Mair TS. Changing concepts of COPD. *Equine Vet J* 1995; 27: 402-403.
 12. Marinkovic D, Aleksic-Kovacevic S, Plamenac P. Cellular Basis of Chronic Obstructive Pulmonary Disease in Horses. *Int Rev Cytol* 2007; 257: 213-247.
 13. McPherson EA, Lawson GH, Murphy JR, Nicholson JM, Fraser JA, Breeze RG, Pirie HM. Chronic obstructive pulmonary disease (COPD): identification of affected horses. *Equine Vet J* 1978; 10: 47-53.
 14. Naylor JM, Clark EG, Clayton HM. Chronic obstructive pulmonary disease; Usefulness of clinical signs, bronchoalveolar lavage, and lung biopsy as diagnostic and prognostic aids. *Can Vet J* 1992; 33: 591-598.
 15. Reed SM, Bayly WM, Sellon DC. *Equine Internal Medicine* 2nd ed. St Louis: WB Saunders. 1998: 142-353.
 16. Robinson NE, Sorenson PR. Pathophysiology of airway obstruction in horses: a review. *J Am Vet Med Assoc* 1978; 172: 299-303.
 17. Tesarowski DB, Viel L, McDonel WN. Pulmonary function measurements during repeated environmental challenge of horses with recurrent airway obstructions (heaves). *Am J Vet Res* 1996; 57: 1214-1219.
 18. Viel L. Small airway disease as a vanguard for chronic obstructive pulmonary disease. *Vet Clin North Am Equine Pract* 1997; 13: 549-560.
 19. Ward MP, Couetil LL. Climatic and aeroallergen risk factors for chronic obstructive pulmonary disease in horses. *Am J Vet Res* 2005; 66: 818-824.

마장마술마에서 발생한 만성폐쇄성폐질환 증례

정효훈 · 안계명* · 김아람* · 노하정** · 오태호¹

경북대학교 수의과대학, *한국마사회 말보건원, **조지아대학교 수의과대학

요 약 : 14세의 거세 마장마술마가 기침, 빈호흡, 점액농성의 비루를 호소하여 한국마사회 말보건원 동물병원에 내원하였다. 일반적인 광범위 항생제 치료를 3주간 실시하였으나 임상증상은 오히려 악화되었다. 이후 환자는 심한 기침과 점액농성의 비루, 빈호흡을 동반한 노력성 호흡, 운동능력저하 등의 임상증상과 기관세척액세포검사에서 심한 호중구성 염증이 관찰되어 만성폐쇄성폐질환으로 진단되었다. 마방 내 공기정화 노력과 병행한 3주간의 전신 글루코코르티코이드 치료를 실시한 결과 치료 후 임상증상이 현저히 개선되었다. 본 증례는 국내 말에서 다발하는 만성호흡기질환 중 비감염성염증인 만성폐쇄성폐질환의 존재 가능성을 시사하였다. 향후 질병 발생 예방을 위해 말 사육 환경 내 존재하는 항원의 조사와 질병 발생을 조사가 필요할 것으로 판단된다.

주요어 : 만성폐쇄성폐질환, 글루코코르티코이드, 말, 호중구성염증.