

Occurrence of Goiter in Flowerhorn Cichlid (Family : Cichlidae) and Its Effect on Liver

Sang-Phil Shin, Hyang Jee*, Jee-Eun Han, Dennis K. Gomez, Ji-Hyung Kim, Casiano H. Choresca Jr.,
Jin-Woo Jun, Dae-Yong Kim* and Se-Chang Park¹

Laboratory of Aquatic Animal Medicine, College of Veterinary Medicine and Research Institute for Veterinary Science, Seoul
National University, Seoul 151-742, Korea

*Department of Veterinary Pathology, College of Veterinary Medicine, Seoul National University, Seoul 151-742, Korea

(Accepted: March 23, 2010)

Abstract : A flowerhorn fish with a subopercular mass, which had been reared in one of the private commercial aquaria was sent to the laboratory just before death. This fish began to show symptoms such as lethargy, anorexia, depression and dyspnea, and eventually died. The mass and intestinal organs were examined histopathologically. Thyroid showed variably sized follicles that contained abundant colloid and liver revealed steatosis. This report presents a case of goiter in the flowerhorn cichlid and its effect on the liver.

Key words : flowerhorn, goiter, histopathology, steatosis.

Introduction

Hyperplastic thyroid lesions and thyroid neoplasms have been observed in several fish species including, African cichlids (18), coho salmon *Oncorhynchus kisutch* (15), kelp bass *Paralabrax clathratus* (3), medaka *Oryzias latipes* (7), swordtails *Xiphophorus montezumae* (2), zebrafish *Danio rerio* (17), and large and small spotted dogfish *Scyliorhinus stellaris* and *Scyliorhinus canicula* (6). The criteria used to distinguish hyperplastic thyroid lesions from thyroid neoplasia in bony fishes have been the center of controversy for approximately 100 years (9). Because thyroid tissue in teleosts is not encapsulated and is capable of widespread ectopic growth (1,10). Thyroid hormones regulate the basal metabolic rate of cells, including hepatocytes and the liver plays a major role in the complex enzymatic processes of thyroxine (T₄) and triiodothyronine (T₃) conversion (4). Thus, the functions of these two organs are closely related. This case report describes a case of goiter in the flowerhorn cichlid and its effect on the liver.

Case

In May 2008, a flowerhorn fish (Family : Cichlidae) (total length = 19.2 cm, body weight = 338.7 g) was obtained from a private commercial aquarium in Seoul, South Korea. This species was believed to be a hybrid between the Midas cichlid *Amphilophus citrinellus* and the three spot cichlid *Cichlasoma trimaculatum*, which was first produced in Malaysia in

approximately 1996 (13). Thus, the flowerhorn cichlid does not exist in nature. The owner imported 10 flowerhorn fish from Southeast Asia. One of ten fish had a subopercular mass (3.84 cm, 13.43 g) (Fig 1), which had developed over a two month period. This fish began to show symptoms such as lethargy, anorexia, depression and dyspnea and eventually died. A laboratory examination was then conducted on the deceased fish.

The necropsy revealed anemia, a mass in the branchial cavity and a pale liver. The mass was intertwined among gill, skin and bone and looked as though it was liquid-filled and transparent. Vessels inside the mass were thus observed

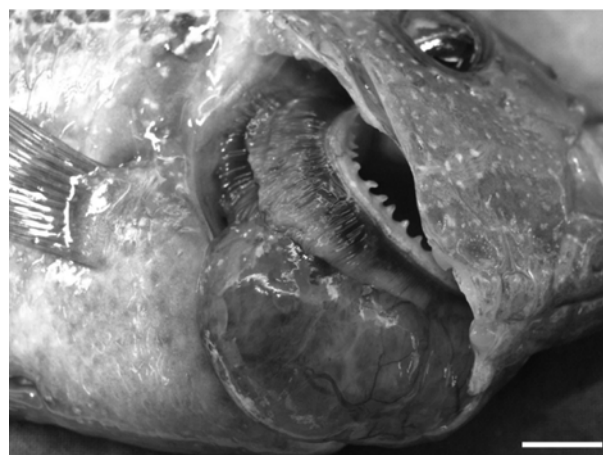

Fig 1. A fish showing a large, ovoid, semi-transparent mass located on the ventral branchial arches. Vessels had developed within the mass (bar = 1 cm).

¹Corresponding author.
E-mail : parksec@snu.ac.kr

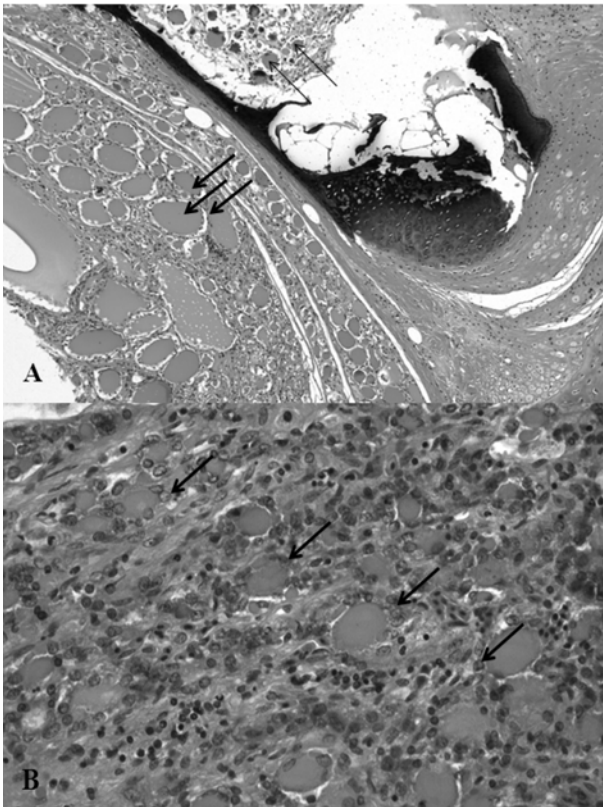


Fig 2. Sections of thyroid gland (A) a photomicrograph of a thyroid showing a discrete nodular hyperplastic lesion in a circumscribed area comprised of well-differentiated colloid-containing follicles (bold arrows). Some hyperplastic follicles were surrounded by bone (arrows) (H&E, $\times 100$). (B) The hyperplastic epithelial cells surrounded the follicles (bold arrows) (H&E, $\times 400$).

clearly. The mass and internal organs were removed, fixed in 10% neutral phosphate-buffered formalin, routinely processed, embedded in paraffin. Five-micrometer sections were then cut and stained with hematoxylin and eosin (H&E) for histopathological examinations. When examined microscopically, the thyroid had follicles of various size containing abundant colloid. The follicles were very well differentiated and formed discrete nodules. The epithelial cells were markedly hyperplastic. The hyperplastic follicles surrounded tissues such as muscle, gill and bone. In particular, tissues contained large numbers of follicles. The follicles surrounded by hyperplastic epithelial cells (Fig 2). The hepatocytes had lost their normal architecture, and a large number of these cells appeared to have pyknotic and karyorrhectic nuclei. The steatosis was characterized by intensive hepatocellular vacuolization. The lipid degeneration occurred in the hepatic parenchyma (Fig 3).

Discussion

Previous study proposed criteria for distinguishing proliferative thyroid lesions in bony fishes (5). By dividing lesions into two categories : neoplastic lesions and non-neoplastic

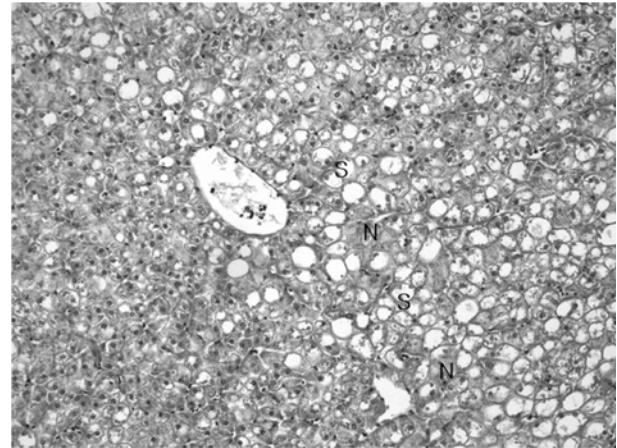


Fig 3. A photomicrograph of a liver showing intensive steatosis (S). The necrotic area (N) is surrounded by an area of lipid degeneration (H&E, $\times 100$).

lesions. Whereas neoplastic lesions include follicular cell adenomas and follicular cell carcinomas, non-neoplastic lesions include simple follicular cell hyperplasias, nodular follicular cell hyperplasias (goiter) and ectopic follicular cell hyperplasias. Neoplastic lesions should exhibit cellular pleomorphisms, nuclear atypia and/or an increase in mitotic activity. We did not observe any evidence of neoplasms in our sample. We also did not find any thyroid hyperplastic lesions in the kidney, spleen, liver or heart. Goiters are represented by the increased number of thyroid follicles within a discretely circumscribed area and well-differentiated hyperplastic follicles (5). However, simple follicular cell hyperplasias do not form discrete nodules or masses. This sample had a single mass, and well-differentiated hyperplastic thyroid follicles were observed in a circumscribed area. This case was thus confirmed to be a goiter based on the above description.

The etiology of goiter in this case is undetermined. However, causes to consider include iodine deficiency, nutritional imbalances, poor water quality, and exposure to goitrogenic substance. Further investigation of this problem could include the measurement of iodine and thyroid hormone levels in the flesh, food and water. Also, a search for goitrogenic substances such as pesticide residue in the water supply was needed.

Interactions between the thyroid gland and the liver are complex and can be severely affected by alterations in thyroid function. Thyroid hormones regulate the basal metabolic rate of cells, including hepatocytes (14). T3 negatively regulates lipogenesis by inhibiting the expression of the Sterol Regulatory Element-Binding Protein (SREBP)-1c (8). This means that SREBP-1c is up-regulated by hypothyroidism, increases triacylglycerol (TG) synthesis and causes steatosis in the liver. Although, this protein and its gene have not been much studied in fish, other protein which correlated with SREBP, such as SREBP cleavage-activating protein (SCAP) has been reported and analyzed in fish (16). And the availability of genomic sequences from fish at least will make it

possible to identify homologues of this important gene in fish (11). Moreover, hypothyroidism causes obesity by decreasing oxidative metabolism and energy expenditure and, also indirectly affects steatosis in the liver (12). Thus, we suggest that this fatty liver in this study might be caused by hypothyroidism. This explained the interactions between the thyroid gland and the liver that will provide the basic information on goiters and fatty livers in fish. Further examinations of goiters and fatty livers in fish are necessary to confirm these hypotheses.

Acknowledgment

This study was supported by a Korea Research Foundation Grant (KRF-2006-005-J02903) and the Research Institute for Veterinary Science, Seoul National University.

References

1. Baker KF. Heterotopic thyroid tissue in fishes. I. The origin and development of heterotopic thyroid tissue in platyfish. *J Morphol* 1958; 103: 91-103.
2. Berg O, Edgar M, Gordon M. Progressive growth stages in the development of spontaneous thyroid tumors in inbred swordtails, *Xiphophorus montezumae*. *Cancer Res* 1953; 13: 1-8.
3. Blasiola GC, Jr. Turnier JC, Hurst EE. Metastatic thyroid adenocarcinomas in a captive population of kelp bass, *Paralabrax clathratus*. *J Natl Cancer Inst* 1981; 66: 51-59.
4. Burcu KT, Sema İÜ, Özlem Ö. The effects of sodium perchlorate on the liver of Molly Fish (*Poecilia sphenops*, Cyprinidae, Teleostei). *Afr J Biotechnol* 2009; 8: 2640-2644.
5. Fournie JW, Wolfe MJ, Wolf JC, Courtney LA, Johnson RD, Hawkins WE. Diagnostic criteria for proliferative thyroid lesions in bony fishes. *Toxicol Pathol* 2005; 33: 540-551.
6. Gridelli S, Diana A, Parmeggiani A, Cipone M, Preziosi R. Goitre in large and small spotted dogfish, *Scyliorhinus stellaris* (L.) and *Scyliorhinus canicula* (L.). *J Fish Dis* 2003; 26: 687-690.
7. Harada T, Itoh H, Hatanaka J, Kamiya S, Enomoto M. A morphological study of a thyroid carcinoma in a medaka, *Oryzias latipes* (Temminck and Schlegel). *J Fish Dis* 1996; 19: 271-277.
8. Hashimoto K, Yamada M, Matsumoto S, Monden T, Satoh T, Mori M. Mouse sterol response element binding protein-1c gene expression is negatively regulated by thyroid hormone. *Endocrinology* 2006; 147: 4292-4302.
9. Hoover KL. Hyperplastic thyroid lesions in fish. *Natl Cancer Inst Monogr* 1984; 65: 275-289.
10. Leatherland JF. Reflection on the thyroidology of fishes: from molecules to humankind. *Guelph Ichthyol Rev* 1994; 2: 1-67.
11. Leaver MJ, Bautista JM, Björnsson BT, Jönsson E, Krey G, Tocher DR, Torstensen BE. Towards Fish Lipid Nutrigenomics: Current State and Prospects for Fin-Fish Aquaculture. *Rev Fish Sci* 2008; 16: 73-94.
12. Loria P, Carulli L, Bertolotti M, Lonardo A. Endocrine and liver interaction: the role of endocrine pathways in NASH. *Nat Rev Gastroenterol Hepatol* 2009; 6: 236-247.
13. Lutz CG. When hybrids attack. *Aquacult Mag* 2004; 30: 1-2.
14. Malik R, Hoodgson, H. The relationship between the thyroid gland and the liver. *Q J Med* 2002; 95: 559-569.
15. Moccia RD, Leatherland JF, Sonstegard RA. Increasing frequency of thyroid goiters in coho salmon (*Oncorhynchus kisutch*) in the great lakes. *Science* 1977; 198: 425-426.
16. Qiu H, Xia T, Chen X, Zhao X, Gan L, Feng S, Lei T, Yang Z. Cloning, comparative characterization of porcine SCAP gene, and identification of its two splice variants. *Mol Gen Genomics* 2006; 276: 187-196.
17. Spitsbergen JM, Tsai HW, Reddy A, Miller T, Arbogast D, Hendricks JD, Bailey GS. Neoplasia in zebrafish (*Danio rerio*) treated with 7, 12-dimethylbenz[a]anthracene by two exposure routes at different developmental stages. *Toxicol Pathol* 2000; 21: 139-143.
18. Wolf JC, Ginn PE, Francis-Floyd R. Goitre in a colony of African cichlids. *J Fish Dis* 1998; 21: 139-143.

플라워혼 시클리드에서 발생한 갑상선종과 간에 대한 영향

신상필 · 지향* · 김지형 · 데니스K.고메즈 · 카시아노 허모피아 추레스카Jr · 한지은 · 김대용* · 박세창¹

서울대학교 수의학과 수생동물질병연구실, *서울대학교 수의학과 병리학연구실

요약 : 아가미 덮개 아래에 종괴를 가진 플라워혼이 서울의 사설 수족관에서 사육되다가 폐사 전 진단이 되 되었다. 이 플라워혼은 무기력, 식욕부진, 침울 및 호흡곤란의 증상을 보인 후 폐사하였다. 종괴와 내장기관을 조직병리학적으로 조사한 결과, 갑상선에서 많은 양의 교질을 가진 다양한 크기의 낭포가 관찰되었고 간에서는 지방변성을 확인할 수 있었다. 본 증례는 플라워혼에서의 갑상선종 발생과 그것이 간에 미치는 영향을 보고하고자 한다.

주요어 : 플라워혼, 갑상선종, 병리조직검사, 지방변성.