

Direct Axillary Arterial Cannulation Using Seldinger's Technique in Aortic Dissection

Young Woo Do, M.D.*, Gun-Jik Kim, M.D.*, Il Park, M.D.*,
Joon-Yong Cho, M.D.*, Jong-Tae Lee, M.D.*

Background: The axillary artery is frequently used for cardiopulmonary bypass, especially in acute aortic dissection. We have cannulated the axillary artery using a side graft or by directly using Seldinger's technique. The purpose of this study was to assess the technical problems and complications of both cannulation techniques. **Materials and Methods:** From January 2003 to December 2009, 53 patients underwent operations using the axillary artery for arterial cannulation. The axillary artery was cannulated with a side graft in 35 patients (side graft group) and directly using Seldinger's technique in 18 patients (direct group). **Results:** The results were compared between two groups, focusing on cannulation-related morbidities including neurologic morbidity. Arterial damage or dissection of the axillary artery occurred in 1 (2.9%) patient in the side graft group and in 1 (5.6%) patient in the direct group. Malperfusion and insufficient flow did not occur in either group. There were no postoperative complications related to axillary cannulation, such as brachial plexus injury, compartment syndrome, or local wound infection, in either group. **Conclusion:** Technical problems and complications of the axillary arterial cannulation in both techniques were rare. Direct arterial cannulation using Seldinger's technique was done safely and more simply than the previous technique. It was concluded that both axillary arterial cannulation techniques are acceptable and it remains the surgeon's preference which technique should be used.

Key words: 1. Aortic dissection
2. Axillary artery
3. Cannulation

INTRODUCTION

The ascending aorta is the most common arterial cannulation site for cardiopulmonary bypass (CPB). When the ascending aorta has a cannulation problem, especially acute type A aortic dissection, many other sites such as the axillary artery, brachial artery, and femoral artery are substituted for the ascending aorta.

The axillary artery has been an especially attractive cannu-

lation site because it has many advantages, including that it is generally free from atherosclerosis [1], rarely affected by dissection, and provides antegrade perfusion of the true lumen during CPB. However, there is still debate over which technique of axillary artery cannulation should be used, the direct cannulation or the side graft technique [2].

Early in our experience, the axillary artery was cannulated directly. However, the direct axillary artery cannulation technique seemed to be associated with complications such as ar-

*Department of Thoracic and Cardiovascular Surgery, Kyungpook University Hospital

Received: March 1, 2011, Revised: June 22, 2011, Accepted: August 24, 2011

Corresponding author: Gun-Jik Kim, Department of Thoracic and Cardiovascular Surgery, Kyungpook University Hospital, 50, Samduck 2-ga, Jung-gu, Daegu 700-721, Korea

(Tel) 82-53-420-5671 (Fax) 82-53-426-4765 (E-mail) straightroot@knu.ac.kr

© The Korean Society for Thoracic and Cardiovascular Surgery. 2011. All right reserved.

© This is an open access article distributed under the terms of the Creative Commons Attribution Non-Commercial License (<http://creativecommons.org/licenses/by-nc/3.0>) which permits unrestricted non-commercial use, distribution, and reproduction in any medium, provided the original work is properly cited.

terial damage, dissections of the axillary artery or the aorta, and postoperative axillary arterial narrowing.

In our experience, direct femoral cannulation using Seldinger's technique is safe and results in minimal morbidity. Our experience with direct femoral cannulation using Seldinger's technique has suggested that direct axillary cannulation using Seldinger's technique may decrease the incidence of arterial injuries compared to the previous direct axillary cannulation technique. For these reasons, we adopted direct axillary cannulation using Seldinger's technique for aortic dissection in January 2003.

This report describes our initial experiences of direct axillary artery cannulation using Seldinger's technique and the short-term clinical outcomes compared to those of patients who underwent the side graft technique.

MATERIALS AND METHODS

1) Patients

We have been using the axillary artery as an arterial cannulation site in acute type A aortic dissection since 2003. From January 2003 to December 2009, 107 patients underwent an operation for acute type A aortic dissection at the Kyungpook National University Hospital. In these patients, the axillary artery for arterial cannulation was used in 53 patients and the femoral artery or ascending aorta in the remaining 54 patients.

The patients for which the axillary artery was used for arterial cannulation were evaluated as two groups. Thirty-five patients (66.0%) were cannulated with a side graft (side graft group) and 18 patients (34.0%) were cannulated directly with Seldinger's technique (direct group) by one of two surgeons.

The mean age of the patients was 56.7 ± 13.4 years in the side graft group and 54.8 ± 14.2 years in the direct group. There were 19 (54.3%) women in the side graft group and 8 (44.4%) women in the direct group.

The following risk factors were noted among the patients: hypertension (56.6%), smoking (37.7%), and Marfan syndrome (9.4%). The clinical characteristics of the patients are detailed in Table 1.

Table 1. Patient's profiles in the preoperative period

	Side graft group (n=35)	Direct group (n=18)	p-value
Female	19 (54.3%)	8 (44.4%)	0.497
Age (yr)	56.7 ± 13.4	54.8 ± 14.2	0.654
Risk factor (n)			
Marfan syndrome	3	2	0.765
Hypertension	21	9	0.487
Smoking	14	6	0.635
Preoperative malperfusion (n)	2	1	
Cerebral	0	1	0.340
Visceral	1	0	1.000
Lower extremity	1	0	1.000
IMH type (n)	11 (31.4%)	1 (5.6%)	0.041

IMH=Intramural hematoma.

2) Technique of axillary artery cannulation: direct vs side graft

To avoid malperfusion, all patients were evaluated for occlusive disease and dissection of the axillary artery by comparing both arms' blood pressure, oxymetric data, as well as images from computed tomography. If significant stenosis and dissection of the axillary artery was identified in preoperative examinations, the affected axillary artery was not cannulated.

Under general anesthesia, the patient was placed in the supine position as usual for cardiac surgery. The skin incision was made in the lateral subclavicular portion after median sternotomy. The pectoralis major muscle was split in the direction of the muscle fibers and the clavicopectoral fascia was cut, and then the small arteries and veins were ligated. Because the axillary artery usually lies deep between the subclavian vein and the brachial plexus, it is usually necessary to mobilize and retract the subclavian vein.

In the side graft group, a 6- or 8-mm Dacron or polytetrafluoroethylene (PTFE) graft was used for end-to-side anastomosis to the axillary artery and a 22 Fr open-ended arterial cannula was inserted into the graft. In the direct group, after a purse-string suture was made on the exposed axillary artery, a 17 Fr or 18 Fr percutaneous femoral arterial cannula was inserted into the axillary artery by Seldinger's technique. As mentioned, the axillary artery lies so deep that it is usually necessary to make another 0.5 cm skin incision for the can-

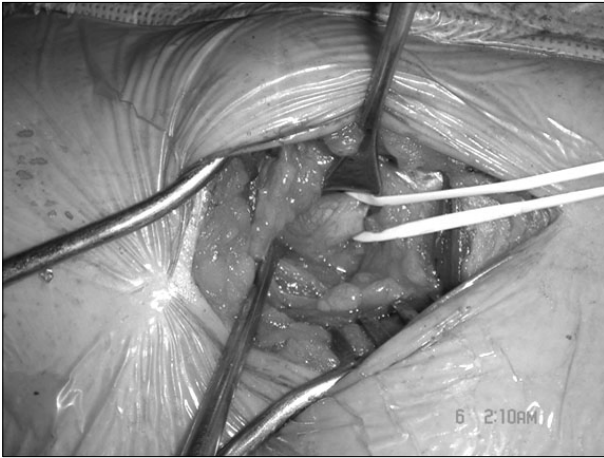

Fig. 1. Exposure of the axillary artery.

nula from approximately 2 to 3 cm lateral to the main skin incision to prohibit kinking of the cannula (Fig. 1, 2). The surgeon should check whether the guided wire for the arterial cannula was positioned in a true lumen by intraoperative transesophageal echocardiography during this procedure.

3) Surgical technique

All operations were performed through a median sternotomy. After arterial cannulation was performed in the axillary artery, venous cannulation was performed in the right atrium with a standard 34 Fr two-stage venous cannula. CPB was then initiated, and the patient was cooled down to 22~25°C, measured by rectal temperature. The ascending aorta was then clamped with a vascular clamp, the proximal part was incised longitudinally, and cardioplegic solution was directly infused through both coronary ostia. Next, the dissected ascending aorta was removed and proximal anastomosis of the ascending aorta was performed with a graft during the cooling phase.

The arch was then inspected and distal anastomosis was performed during hypothermic circulatory arrest. If needed, antegrade cerebral perfusion (ACP) was used by inserting two retrograde cardioplegia balloon catheters into the innominate artery and the left common carotid artery. Because the retrograde cardioplegia self-inflating balloon cannulas were inserted into the two arteries, it was unnecessary to clamp the innominate artery, whereas clamping would be necessary if an axillary cannula were used during ACP. If the innominate artery is preoperatively dissected in the majority of type A

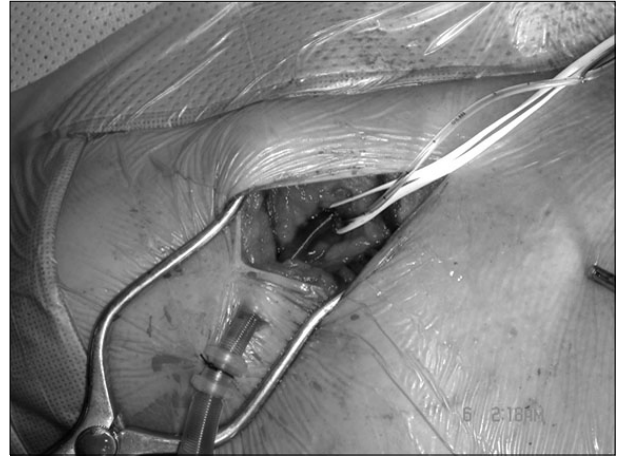


Fig. 2. Percutaneous femoral arterial cannula is inserted by Seldinger's technique.

aortic dissections, the artery could be injured during clamping and could be the cause of fatal results. Next, CPB was restarted using the axillary artery for arterial perfusion.

At the end of the procedure, after CPB was ceased and the hemodynamic state of the patient was stable, the axillary artery was decannulated and the artery was closed using an interrupted, reinforced 6-0 Prolene suture.

4) Data collection and statistical analysis

In the outpatient clinic or by telephone, patients were asked whether they had experienced any sensory symptoms, wound complications, or functional impairment of the forearm or hand since their surgeries.

Continuous variables were reported as the mean±standard deviation and range. Statistical analyses were done using the Student's t-test and chi-square test. A p-value of less than 0.05 was considered significant. All statistical analyses were done on SPSS 17.0 software (SPSS Inc., Chicago, IL, USA).

RESULTS

1) Operative and postoperative results

Hypothermic circulatory arrest (HCA) was used in all patients with moderate to deep hypothermia (at rectal temperature 22~25°C). In 33 (62.3%) patients, HCA was performed with ACP or retrograde cerebral perfusion (RCP), whereas in 20 (37.7%) patients it was performed without cer-

Table 2. Operative data in two groups

	Side graft group (n=35)	Direct group (n=18)
Operative procedure (n)		
Aortic replacement		
Ascending	26	13
Ascending aorta + hemiarch	1	1
Ascending aorta + arch	2	1
Ascending + AVR	2	0
Cabrol	1	0
Modified Bentall	0	3
Valve sparing	2	0
CPB time (min)	164.1±51.4	194.0±40.8
ACC time (min)	81.4±35.9	95.4±27.9
HCA + no cerebral perfusion (n)	16	4
HCA + RCP (n)	1	0
HCA + ACP (n)	18	14
ACP time (min)	33.1±18.7	31.7±18.7

AVR=Aortic valve replacement; CPB=Cardiopulmonary bypass; ACC=Aorta cross clamp; HCA=Hypothermic circulatory arrest; RCP=Retrograde cerebral perfusion; ACP=Antegrade cerebral perfusion.

bral perfusion. ACP was performed on 32 patients, with a mean ACP time of 32.5±18.4 minutes, RCP was performed on 1 patient (Table 2).

The mortality of the side graft group was 3 in 35 (8.6%)--one each due to aortic rupture, sepsis, and DIC)Disseminated intravascular cosgulopathy). There was no hospital mortality in the direct group.

In the side graft group, transient neurologic deficiency (TND) occurred in 3 (11.4%) patients, and in the direct group, 4 (22.2%) patients. There were 6 strokes (17.1%) in the side graft group, but no strokes in the direct group. There were no significant differences between the groups with respect to the neurologic results (Table 3).

2) Cannulation-related results

Arterial damage or dissection of the axillary artery occurred in 1 (2.9%) of the patients in the side graft group and in 1 (5.6%) of the patients in the direct group. In these cases the cannulation site was substituted with the femoral artery. Malperfusion and insufficient CPB flow did not occur in either group.

Table 3. Complications in the post-operative period

	Side graft group (n=35)	Direct group (n=18)	p-value
Cannulation-related			
Arm ischemia	0	0	
Brachial plexus injury	0	0	
Arterial dissection	1 (2.9%)	1 (5.6%)	1.000
TND	3 (11.4%)	4 (22.2%)	0.421
Stroke	6 (17.1%)	0 (0%)	

TND=Transient neurologic deficiency.

There were no postoperative complications related to axillary cannulation, such as brachial plexus injury, compartment syndrome, and local wound infection in either group.

DISCUSSION

The axillary artery and femoral artery are common sites of cannulation for CPB in type A dissection. The cannulation of the femoral artery is still widely used in aortic dissection. However, it theoretically has several disadvantages since retrograde perfusion through femoral arterial cannulation may dislodge atheroma and dissect intima in the descending aorta. This can result in neurologic injuries such as stroke and abdominal organ ischemia. Furthermore, femoral arterial cannulation is not possible in cases of peripheral disease (such as severe iliofemoral occlusive disease, distal extension of the aortic dissection into the femoral arteries, and arteriosclerosis of the femoral arteries) [1].

In aortic dissection surgeries, the preferred site for arterial cannulation is one in which is rarely dissected, relatively free from arteriosclerosis, provides antegrade perfusion into the true lumen at the beginning of CPB, and is not necessary to perform cannulation into the tube graft before restarting CPB [3-9].

Two different techniques may be used to perform axillary arterial cannulation: (1) an arterial cannula may be placed directly into the axillary artery or (2) the artery may be cannulated using a side graft. Several studies have shown that side graft cannulation has several advantages over direct arterial cannulation [10-12]. In these series, the exposed axillary artery was clamped for arteriotomy and the angled or straight

arterial cannula was inserted for direct cannulation. However, as the axillary artery is thin-walled and often fragile, the direct cannulation technique can create several complications and technical problems.

In this study, we adopted Seldinger's technique instead of the previous direct cannulation method, used transesophageal echocardiography to check that the guiding wire was in the true lumen, and used straight percutaneous femoral arterial cannula for the direct axillary arterial cannulation. With this technique, it is unnecessary to clamp the axillary artery during direct cannula insertion, whereas it is necessary in the previous direct cannulation technique and the side graft technique. During clamping of the axillary artery, the artery may be injured and dissected and this may be the cause of malperfusion. The other disadvantages of side graft cannulation are that it is apt to bleed from the graft suture line and ooze through the side graft itself during CPB, both of which can contaminate operative fields.

Yilik and associates reported that side graft cannulation avoided malperfusion of the vertebral artery and therefore attained better cerebral perfusion during ACP, but found no significant differences in neurologic results and complications in both groups [13].

The symptom complex known as temporary neurological dysfunction (TND) includes confusion, lethargy, agitation, psychosis, and parkinsonism according to the scale of Ergin and associates [14]. In our study, the number of TND is much greater in the side graft group than in the direct group. However, we could conclude that two procedures of the axillary artery cannulation are safe and should be performed according to the surgeons' preference. It also remains to be elucidated why these neurologic problems only occurred with patients who underwent the side graft technique.

CONCLUSION

This study suggests that both group's complications were similar. We experienced direct axillary cannulation using Seldinger's technique to be simple and reliable. We conclude that direct cannulation into the axillary artery using Seldinger's technique is as good as side graft cannulation; therefore, it should remain the surgeon's preference as to

which technique should be used for axillary arterial cannulation.

REFERENCES

1. Whitlark JD, Goldman SM, Sutter FP. *Axillary artery cannulation in acute ascending aortic dissection*. *Ann Thorac Surg* 2000;69:1127-9.
2. Schachner T, Nagiller J, Zimmer A, Laufer G, Bonatti J. *Technical problems and complications of axillary artery cannulation*. *Eur J Cardiothorac Surg* 2005;27:634-7.
3. Bortst HG. *Axillary artery for extracorporeal circulation*. *J Thorac Cardiovasc Surg* 1995;110:1775.
4. Yuiichi T, Koichi A, Satoshi K, et al. *Coexistent true aortic aneurysm as a cause of acute aortic dissection*. *Circ J* 2009;73:822-5.
5. Bortst HG. *Surgical tactics and techniques*. In: Borst HG, Heinemann MK, Stone CD. *Surgical treatment of aortic dissection*. New York: Churchill Livingstone. 1996;255-68.
6. Sabik JF, Lytle BW, McCarthy PM, Cosgrove DM. *Axillary artery: an alternative site of arterial cannulation for patients with extensive aortic and peripheral vascular disease*. *J Thorac Cardiovasc Surg* 1995;109:885-91.
7. Neri E, Massetti M, Capannini G, et al. *Axillary artery cannulation in type A aortic dissection operation*. *J Thorac Cardiovasc Surg* 1999;118:324-9.
8. Yavuz S, Goncu MT, Turk T. *Axillary artery cannulation for arterial inflow in patients with acute dissection of the ascending aorta*. *Eur J Cardiothorac Surg* 2002;22:313-5.
9. Mazzola A, Gregorini R, Villani C, Di Eusanio M. *Antegrade cerebral perfusion by axillary artery and Left carotid artery inflow at moderate hypothermia*. *Eur J Cardiothorac Surg* 2002;21:930-1.
10. Mitumasa H, Mitsunori S, Akira S, et al. *Outcome of less invasive proximal arch replacement with moderate hypothermic circulatory arrest followed by aggressive rapid re-warming in emergency surgery for type A acute aortic dissection*. *Circ J* 2009;73:69-72.
11. Sinclair MC, Singer RL, Manley NJ, Montesano RM. *Cannulation of the axillary artery for cardiopulmonary bypass: safeguards and pitfalls*. *Ann Thorac Surg* 2003;75:931-4.
12. Sabik JF, Neme H, Lytle BW, et al. *Cannulation of the axillary artery with a side graft reduces morbidity*. *Ann Thorac Surg* 2004;77:1315-20.
13. Yilik L, Emreca B, Kestelli M, et al. *Direct versus side-graft cannulation of the right axillary artery for antegrade cerebral perfusion*. *Tex Heart Inst J* 2006;33:310-5.
14. Ergin MA, Uysal S, Reich DL, et al. *Temporary neurological dysfunction after deep hypothermic circulatory arrest: A clinical marker of long-term functional deficit*. *Ann Thorac Surg* 1999;67:1887-90.