

## Cavernous Lymphangioma Arising in the Chest Wall 19 Years after Excision of a Cystic Hygroma

Woo Surng Lee, M.D.\*, Yo Han Kim, M.D.\*, Hyun Keun Chee, M.D.\*, Song Am Lee, M.D.\*, Jong Duk Kim, M.D.\*, Dong Chan Kim, M.D.\*

Lymphangioma is a congenital malformation of the lymphatic system and is thought to result from the failure of the lymphatic system to connect with the venous system. Lymphangioma of the chest wall is a very rare disease entity, and only a few cases have ever been documented in the literature. To the best of our knowledge, there have been few cases of recurrent cavernous lymphangioma after surgical excision of a cystic hygroma on the same side of the chest wall. Here, we report a case of a cavernous lymphangioma of the chest wall in a patient who had undergone surgical excision of a cystic hygroma 19 years earlier.

Key words: 1. Chest wall tumor  
2. Cavernous lymphangioma

### CASE REPORT

A 20-year-old woman presented at our hospital with a 2-month history of a palpable mass in the right chest wall. Physical examination revealed a movable non-tender mass located in the right chest wall measuring 2.0 cm in diameter. The patient had undergone a successful surgical excision of a 3.0-cm-diameter cystic hygroma of the right chest wall under general anesthesia at the age of 4 months. Thereafter, she was regularly followed up, and her postoperative course was uneventful until this recurrence. The mass was located approximately 5.0 cm from the operation scar and the skin overlying the mass was not distinct. The previous operation area had no direct communication with the newly developed lesion, and other changes were not noted in the area of the old cystic lymphangioma except for an old fibrotic scar. It was first noted 2 month prior to the visit, and became pro-

gressively larger for 2 weeks prior to presentation. When the mass was mobilized, the patient complained of mild pain.

A chest radiograph showed nonspecific findings, while chest computed tomography (CT) revealed a 2.0-cm round, homogeneous, low-attenuation mass with a regular margin and no calcification and without any other lesions or lymphadenopathies in the heart, lung, or mediastinum. No significant findings were detected on blood tests, and serum tumor markers were negative. Ultrasonography showed that the palpable mass was an approximately 2.0-cm ovoid lesion in the subcutaneous layer of the right chest wall with heterogeneous echotexture and some blood supply (Fig. 1A).

Surgical excision was performed under local anesthesia (Fig. 1B, C). Microscopically, the mass contained numerous cavernous and cystically dilated spaces lined by endothelial cells that were supported by prominent fibrocollagenous stroma (Fig. 2). The final histologic diagnosis was cavernous

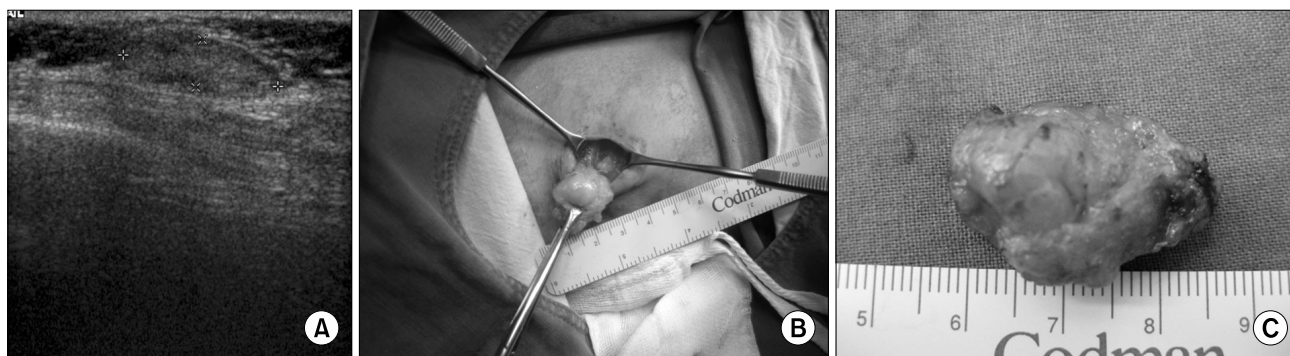\*Department of Thoracic and Cardiovascular Surgery, School of Medicine, Konkuk University

Received: January 28, 2011, Revised: May 19, 2011, Accepted: July 3, 2011

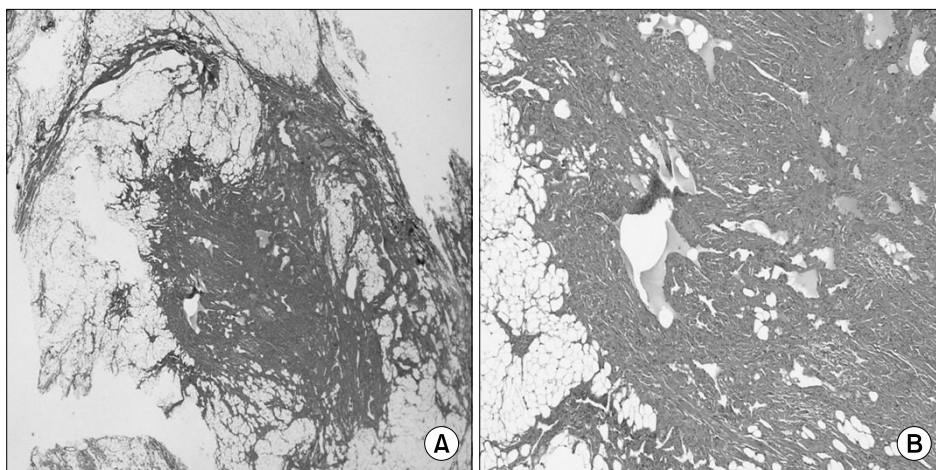
Corresponding author: Yo Han Kim, Department of Thoracic and Cardiovascular Surgery, Konkuk University Chungju Hospital, School of Medicine, Konkuk University, 620-5, Kyohyun-dong, Chungju 380-704, Korea  
(Tel) 82-43-840-8841 (Fax) 82-43-847-8665 (E-mail) yonaa@kku.ac.kr

© The Korean Society for Thoracic and Cardiovascular Surgery. 2011. All right reserved.

© This is an open access article distributed under the terms of the Creative Commons Attribution Non-Commercial License (<http://creativecommons.org/licenses/by-nc/3.0>) which permits unrestricted non-commercial use, distribution, and reproduction in any medium, provided the original work is properly cited.



**Fig. 1.** (A) Chest wall sonographic finding showing a 2.0-cm chest wall mass. (B) Photograph of operative findings. (C) Specimen showing a 2.0-cm chest wall mass.



**Fig. 2.** Microscopic appearance of the cavernous lymphangioma showing dilated lymphatic channels lined by endothelial cells (hematoxylin-eosin, original magnification  $\times 12.5$  &  $\times 40$ ).

lymphangioma of the chest wall. At an 8-month follow-up, her postoperative course was uneventful without any recurrence.

## DISCUSSION

Lymphangioma is produced by sequestered primitive lymphatic tissue that fails to communicate with peripheral drainage pathways [1,2]. The tumor is a rare benign congenital malformation containing focal proliferations of well-differentiated lymphatic tissues that present as multicystic or sponge-like accumulations. Most tumors appear as a swelling in the head, neck, or axilla [3,4]. About 1% of all lymphangiomas are confined to the chest wall, most of which are found in the mediastinum, accounting for 0.7~4.5% of all mediastinal tumors [3,4]. However, as noted above, cavernous

lymphangioma rarely presents as a chest wall tumor. To the best of our knowledge, few cases of cystic hygroma-the most common type of lymphangioma-have been reported in the literature, especially in adults.

Histologically, lymphangioma can be divided into 3 types depending on the size of the lymphatic channels: cystic (macrocytic), capillary (super-microcytic) and cavernous (microcytic). The cystic type is the most common, whereas the cavernous type is relatively rare. Cystic lymphangioma is also called cystic hygroma, and this tumor is a soft lymph-filled mass within a thin-walled "sac" generally appearing on the neck (75%), axilla (20%), or trunk/extremity (5%). The tumor usually presents as a swollen bulge underneath the skin. While the tumor generally presents at birth, it may appear at any time up to the age of 3 years. Cavernous lymphangioma is an uncommon type that generally arises during

infancy. The tumor is seated deep beneath the dermis, but the external skin is not involved. Because it is deep-seated, it forms a bulging, painless mass [5]. Some patients present with symptoms, such as dysphagia, dyspnea, coughing or chest pain, due to compression of vital structures by the mass. The tumor usually appears as a homogeneous, low-attenuation mass, similar in appearance to that of water on chest CT, but may show a higher attenuation or be comprised of a combination of fluid, solid tissue, and fat [6]. MRI is helpful in the diagnosis of lymphangioma, which has heterogeneous signal intensity on T1-weighted images and high signal intensity on T2-weighted images, reflecting its fluid content [7].

The primary treatment of lymphangioma is surgical excision. Park et al. [8] reported that surgical excision of lymphangioma has the best chance of cure and that there is an increased possibility of recurrence if excision is not performed completely. Alternative treatments have been reported in attempts to treat those who are poor surgical candidates. These treatments include laser therapy, radiation therapy, chemotherapy and use of sclerosing agents. However, it may be difficult to obtain safe margins because of the tendency of these lesions to infiltrate into the surrounding tissue. The probability of recurrence is low if the tumor is completely excised. Sometimes, percutaneous sclerosis or a combination of percutaneous sclerosis and surgical excision is successful [8]. We reported an unusual case of cavernous lymphangioma presenting as a chest wall mass. Although the incidence of cavernous lymphangioma of the chest wall is extremely rare in adults, this kind of tumor should be considered during the evaluation of chest wall masses. It is thought that wide surgical excision after a precise evaluation of the tumor extent is

the most effective treatment modality. This case has 3 clinical implications. First, cavernous lymphangioma, the rarest type of lymphangioma, presented as a solitary lesion in the chest wall. Second, most lymphangiomas occur in the neonatal period and before adolescence, but this case occurred in a 20-year-old adult. Third, the patient underwent surgical removal of a cystic hygroma of the chest wall in the neonatal period but presented with a cavernous lymphangioma that occurred 19 years after the operation.

## REFERENCES

1. Chung SY, Oh KK, Kim DJ. *Mammographic and sonographic findings of a breast cystic lymphangioma*. J Ultrasound Med 2003;22:307-9.
2. Singh S, Baboo ML, Pathak LC. *Cystic lymphangioma in children: report of 32 cases including lesions at rare sites*. Surgery 1971;69:947-51.
3. Ardenghy M, Miura Y, Kovach R, Hochberg J. *Cystic hygroma of the chest wall: a rare condition*. Ann Plast Surg 1996;37:211-3.
4. Kennedy TL, Whitaker M, Pellitteri P, Wood WE. *Cystic hygroma/lymphangioma: a rational approach to management*. Laryngoscope 2001;111:1929-37.
5. Faul JL, Berry GJ, Colby TV, et al. *Thoracic lymphangiomas, lymphangiectasis, lymphangiomatosis, and lymphatic dysplasia syndrome*. Am J Respir Crit Care Med 2000;161:1037-46.
6. Jeung MY, Gasser B, Gangi A, et al. *Imaging of cystic masses of the mediastinum*. Radiographics 2002;22:79-93.
7. Shaffer K, Rosedo-de-Christenson ML, Patz EF Jr, Young S, Farver CF. *Thoracic lymphangioma in adults: CT and MR imaging features*. AJR Am J Roentgenol 1994;162:283-9.
8. Park JG, Aubry MC, Godfrey JA, Midthum DE. *Mediastinal lymphangioma: Mayo clinic experience of 25 cases*. Mayo Clin Proc 2006;81:1197-203.