

## Clinical Article

# Influence of Clinical and Anatomic Features on Treatment Decisions for Anterior Communicating Artery Aneurysms

Jae-Hyung Choi, M.D.,<sup>1</sup> Myung-Jin Kang, M.D.,<sup>2</sup> Jae-Taeck Huh, M.D., Ph.D.<sup>1</sup>

Departments of Neurosurgery,<sup>1</sup> Neuroradiology,<sup>2</sup> Busan-Ulsan Regional Cardiocerebrovascular Center, Medical Science Research Center, College of Medicine, Dong-A University, Busan, Korea

**Objective :** The purpose of this study was to analyze the clinical and anatomic features involved in determining treatment modalities for anterior communicating artery (AcoA) aneurysms.

**Methods :** The authors retrospectively evaluated 112 AcoA aneurysms with pretreatment clinical features including age, Hunt and Hess grade, medical or neurological comorbidity, and anatomical features including aneurysm size, neck size, dome-to-neck ratio, vessel incorporation, multiple lobulation, and morphologic scoring system. Post-treatment clinical results were classified according to the Glasgow Outcome Scale, and anatomic results in coiled patients were classified according to the modified Raymond scale. Using multivariate logistic regression, the probabilities for decision making between surgical clipping and coil embolization were calculated.

**Results :** Sixty-seven patients (60%) were treated with surgical clipping and 45 patients (40%) with endovascular coil embolization. The clinical factor significantly associated with treatment decision was age ( $\geq 65$  vs.  $< 65$  years) and anatomical factors including aneurysm size (small or large vs. medium), dome-to-neck ratio ( $< 2$  vs.  $\geq 2$ ), presence of vessel incorporation, multiple lobulation, and morphologic score ( $\geq 2$  vs.  $< 2$ ). In multivariate analysis, older patients (age,  $> 65$  years) had significantly higher odds of being treated with coil embolization relative to clipping (adjusted OR=3.78; 95% CI, 1.39-10.3;  $p=0.0093$ ) and higher morphological score patients ( $\geq 2$ ) had a higher tendency toward surgical clipping than endovascular coil embolization (OR=0.23; 95% CI, 0.16-0.93;  $p=0.0039$ ).

**Conclusion :** The optimal decision for treating AcoA aneurysms cannot be determined by any single clinical or anatomic characteristics. All clinical and morphological features need to be considered, and a collaborative neurovascular team approach to AcoA aneurysms is essential.

**Key Words :** Anterior communicating artery aneurysm · Clipping · Coiling · Morphology.

## INTRODUCTION

The anterior communicating artery (ACoA) is the most common site of intracranial aneurysms, as reported in some large surgical or endovascular series<sup>11,19</sup>. The standard method for treating ACoA aneurysms was craniotomy and microsurgical clip ligation. However, since the introduction of Guglielmi detachable coil embolization, endovascular treatment for ACoA aneurysms has become a safe alternative to microsurgical clip occlusion<sup>2,4,5</sup>.

Furthermore, various adjunctive techniques have been used to facilitate coil embolization of these lesions, including neck re-

modeling using balloons or stent-assisted embolization<sup>14,15,17,18</sup>, and several papers have reported good outcomes of endovascular coil embolization of ACoA aneurysms<sup>20,23</sup>.

Patients with ACoA aneurysms, either ruptured or unruptured, are frequently eligible for both open surgery ("clipping") and endovascular repair ("coiling"). Although randomized trials comparing clipping and coiling for the treatment of ruptured aneurysms have been published<sup>13,27</sup>, decision making between clipping and coiling for individual patients is complex.

Factors such as aneurysm size, location, geometry, patient age, clinical status, comorbidity, and institutional factors such as the availability of skilled open and endovascular surgeons can all be important in individual treatment decisions<sup>1,22,25,29,30</sup>. Deciding whether to clip or coil a cerebral aneurysm is important in modern cerebrovascular surgery, but appropriate patient selection remains a key issue.

The purpose of our study was to analyze the factors that determine treatment choice (coiling or clipping) for ACoA aneurysms.

• Received : December 9, 2010 • Revised : June 1, 2011

• Accepted : August 16, 2011

• Address for reprints : Jae-Taeck Huh, M.D., Ph.D.  
Department of Neurosurgery, College of Medicine, Dong-A University  
1 Dongdaesin-dong 3-ga, Seo-gu, Busan 602-715, Korea  
Tel : +82-51-240-2869, Fax : +82-51-242-6714  
E-mail : jthuh@dau.ac.kr

## MATERIALS AND METHODS

### Patient population

We performed a retrospective review of 112 medical records of patients who underwent surgical clipping or coil embolization for AcoA aneurysms in our hospital from March 2007 to March 2010. Fifty-eight patients were female (52%) and 54 patients were male (48%). Their ages ranged from 27 to 76 years (mean age, 55.6 years). Sixty-seven patients (60%) were treated with surgical clipping and 45 (40%) were treated with endovascular coil embolization (Table 1).

### Clinical analysis

We analyzed the initial Hunt and Hess (H-H) grade, presence of medical or neurological comorbidity, presence of intracerebral hemorrhage, and Glasgow Outcome Scale (GOS). We separated patients into 2 clinical groups according to pre- and post-treatment clinical condition. "Good" was defined as H-H grade of 0, 1, or 2 and GOS of 4 or 5. "Poor" was defined as H-H grade 3 or 4 and GOS of 1, 2, or 3. "Medical comorbidity" was defined as patients who had medical illness that can affect general anesthesia or a life expectancy as cardiovascular disease, malignancy, liver cirrhosis, or thyroid disease. "Neurological comorbidity" was defined as patients who had suffered from previous stroke (Table 1).

In the clinical analysis, we defined neurological deterioration dichotomously from initial good grade to poor grade at discharge. Decisions regarding microsurgical or endovascular treatment were made on an individual basis in conjunction with our multidisciplinary team, which included faculty members of the vascular neurosurgery, neurointerventional radiology and neurovascular neurology department. Aneurysm morphology, presenting neurological condition, medical comorbidities, and predicted treatment risks were considered in each decision.

**Table 1.** Patients' baseline clinical characteristics

Variable	Overall (%)	Method (%)		p-value	
		Clip	Coil		
All cases	112 (100)	67 (60)	45 (40)		
Age	Mean±SD	55.6±10.0	53.9±10.0	58.1±9.5	0.031
	Range	27-76	27-76	36-76	
Sex	Female	58 (52)	37 (55)	21 (47)	0.44
	Male	54 (48)	30 (45)	24 (53)	
H-H grade	Good (0-2)	72 (64)	46 (69)	26 (58)	0.68
	Poor (3-5)	40 (36)	21 (31)	19 (42)	
Neurological comorbidity	Yes	34 (30)	17 (25)	17 (38)	0.21
	No	78 (70)	50 (75)	28 (62)	
Medical comorbidity	Yes	8 (7)	6 (9)	2 (4)	0.47
	No	104 (93)	61 (91)	43 (96)	
GOS	Good	95 (85)	58 (87)	37 (82)	1.00
	Poor	17 (15)	9 (13)	8 (18)	

GOS : Glasgow Outcome Scale, H-H grade : Hunt and Hess grade

### Anatomical analysis

All of the aneurysm morphology were analyzed by using the digital subtraction angiography with three dimensional reconstruction. Morphological analysis involved aneurysm size, neck size, dome-to-neck ratio, vessel incorporation, multiple lobulation, and patency of the AcoA. Small aneurysms were defined as having a dome of <3 mm. Medium aneurysms had domes of 3-10 mm. Large aneurysms had domes >10 mm. Small necks were defined as <4 mm; large necks, as ≥4 mm. Dome-to-neck ratios were categorized into ≥2 and <2. Patency of the AcoA was checked by contralateral compression view (Table 2).

Several anatomic characteristics were collected to make a morphological scoring system. This scoring system was made to analyze the effect of multiple anatomical factors for determining treatment modality. The scoring system has 5 anatomical factors that affect decision making include aneurysm size, dome-to-neck ratio, neck size, vessel incorporation, and multiple lobulation. When favorable to coiling, the score is 0; when unfavorable to coiling, the score is 1. The score is calculated by the summation of the morphologic variables (Table 3) (Fig. 1).

We separated patients into 2 anatomical groups according to score : 0 or 1 unfavorable factor (score <2) and more than 2 unfavorable factors (score ≥2).

### Treatment outcome

Hunt and Hess grades were used to determine baseline neurological condition, and neurological outcomes were determined by the GOS at discharge<sup>10</sup>.

The angiographic results were evaluated in immediate post-operative 3-dimensional computed tomography angiography in clipped patients and immediate post-embolization angiography in coiled patients. Post-embolization angiographic results were classified using modified Raymond scale<sup>25</sup>. An embolization was considered complete (grade I) if there was no contrast filling of the dome, body, or neck. Residual fillings (grade II) were defined as being neck remnants when residual filling of part of the aneurysm neck was present and incomplete (grade III) if there was some contrast filling of the dome or sac.

We separated patients into 2 groups who were treated by coil embolization according to post-embolization angiographic result. Modified Raymond scale grade I was defined as "Good anatomical outcome" and grade II and III was defined as "Poor anatomical outcome".

### Statistical method

Clinical characteristics of patients were summarized as whole and described specifically for subgroups by descriptive statistics. After descriptive analyses were

performed, a Fisher’s exact test was used to compare categorical variables between groups, while a Student’s t-test was used to compare continuous variables between groups.

The odds ratios (ORs) for comparison between groups was summarized with its 95% confidence interval and *p*-value using logistic regression. The multivariate model was created using a backward elimination method and the probability was set at 0.10 for removal. ORs were also adjusted for factors affecting the response variable.

*p*-values <0.05 were considered statistically significant. This study was retrospective in nature; therefore, no adjustment for significance level was applied. All statistical analyses were carried out using SAS version 9.1 statistical software.

**RESULTS**

**Aneurysm morphology**

Seventeen patients had small aneurysms, 88 patients had medium aneurysms, and 7 patients had large aneurysms. In the surgical clipping group, 19 patients (28%) had small or large aneurysms; in the coil embolization group, 5 patients (11%) had small or large aneurysms. Eighty-one patients had aneurysms with small necks, and 24 patients had aneurysms with wide necks. In the surgical group, 18 patients (27%) had aneurysms with wide necks; in the coil embolization group, 13 patients (29%) had aneurysms with wide necks. A total of 88 aneurysms had a dome-to-neck ratio ≥2, while 24 had a dome-to-neck ratio <2. In the surgical clipping group, 59 aneurysms (88%) had a dome-to-neck ratio <2; in the coil embolization group, 29 aneurysms (64%) had a dome-to-neck ratio <2. Twenty-five patients had vessel-incorporated aneurysms : 22 of these patients (88%) were treated by surgical clipping and 3 patients (22%) were treated by coil embolization.

Morphologic scores were measured in all patients. Each of the 5 anatomic factors can independently affect treatment modality decisions (Fig. 1). Eleven patients had no unfavorable anatomic factors to coil embolization (score 0); among them, 2 patients (18%) were treated with surgical clipping and 9 patients (82%) were treated with coil embolization.

Of the 38 patients with one unfavorable characteristic (score 1),

**Table 2.** Patients’ baseline anatomic characteristics

Variable	Overall (%)	Method (%)		<i>p</i> -value	
		Clip	Coil		
ACoA patency	+	69 (62)	38 (57)	31 (69)	0.24
	-	43 (38)	29 (43)	14 (31)	
ICH	+	14 (12)	5 (7)	9 (20)	0.078
	-	98 (88)	62 (93)	36 (80)	
AN size	Small : <3 mm	17 (15)	15 (22)	2 (4)	0.024
	Medium : ≥3 to <10 mm	88 (79)	48 (72)	40 (89)	
	Large : ≥10 mm	7 (6)	4 (6)	3 (7)	
D to N ratio	<2	88 (79)	59 (88)	29 (64)	0.0044
	≥2	24 (21)	8 (12)	16 (36)	
Vessel incorporation	Yes	25 (22)	22 (33)	3 (7)	0.0020
	No	87 (78)	45 (67)	42 (93)	
Multiple lobulation	Yes	41 (37)	28 (42)	13 (29)	0.17
	No	71 (63)	39 (58)	32 (71)	
AN neck size	<4 mm	81 (72)	49 (73)	32 (71)	0.83
	≥4 mm	31 (28)	18 (27)	13 (29)	
Morphologic score	0	11 (10)	2 (3)	9 (20)	0.27
	1	38 (34)	21 (31)	17 (38)	
	2	32 (28)	20 (30)	12 (27)	
	3	18 (16)	12 (18)	6 (13)	
	4	12 (11)	11 (16)	1 (2)	
	5	1 (1)	1 (1)	0 (0)	
Morphologic score	<2	49 (44)	23 (34)	26 (58)	0.031
	≥2	63 (56)	44 (66)	19 (42)	
Morphologic score	<3	81 (72)	43 (64)	38 (84)	0.031
	≥3	31 (28)	24 (36)	7 (16)	

ACoA : anterior communicating artery, ICH : intracerebral hemorrhage, D : dome, N : neck, AN size : aneurysm size

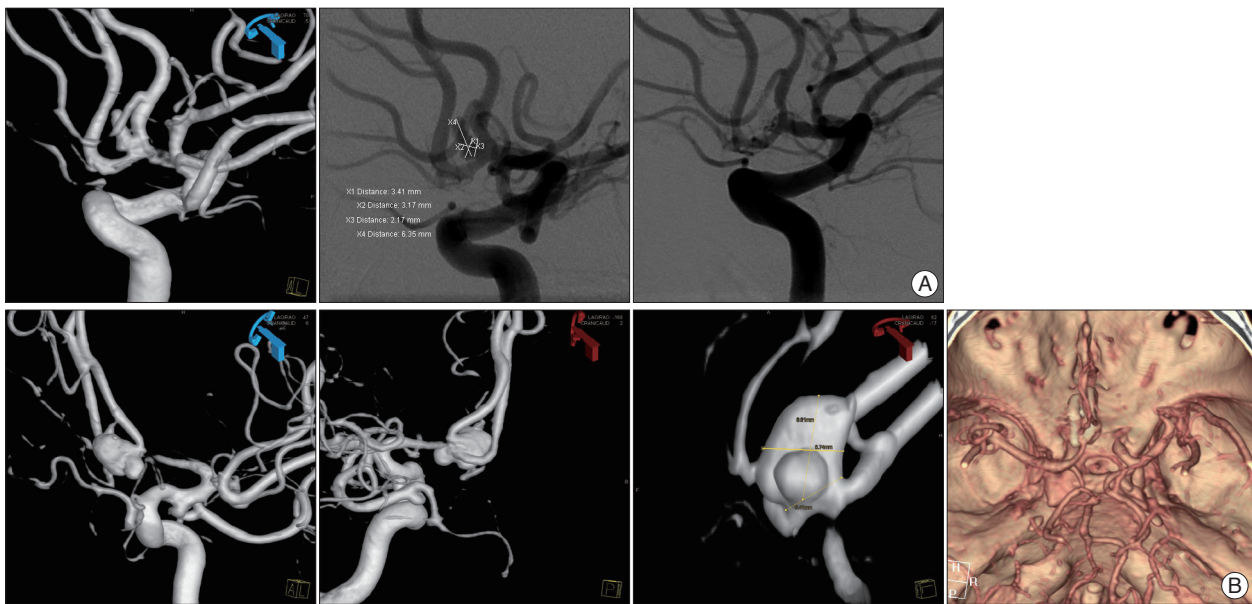
**Table 3.** Morphological scoring system

Variable	0	1
AN size	Medium	Small or large
D to N ratio	≥2	<2
Vessel incorporation	No	Yes
Multiple lobulation	No	Yes
Neck	<4	≥4

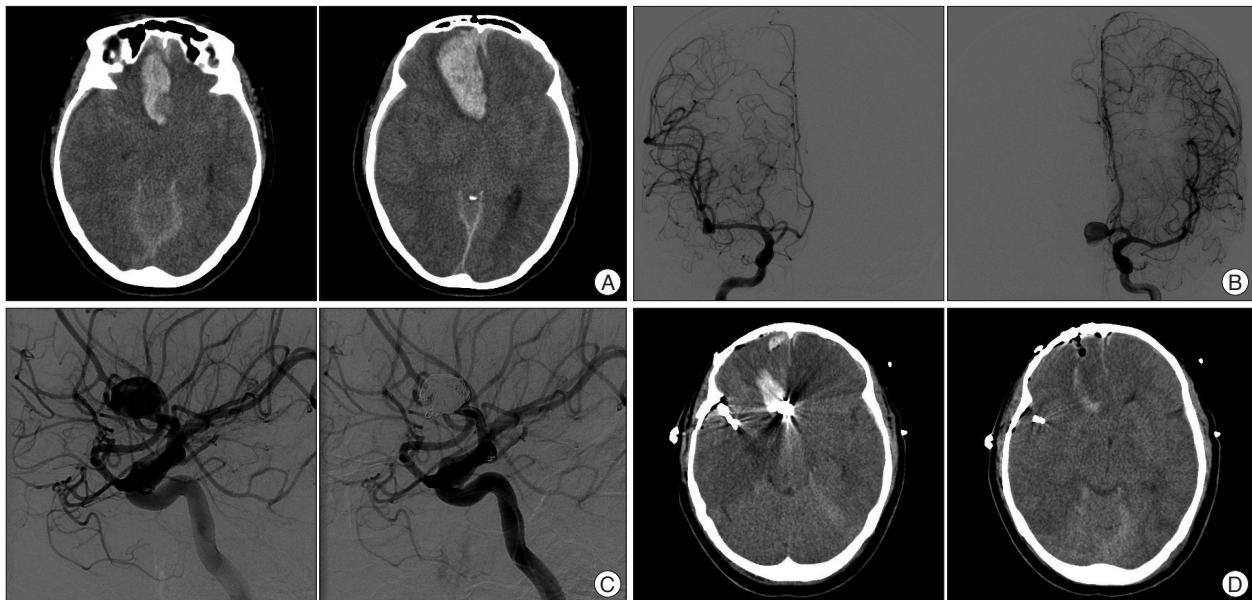
The score is calculated by the summation of the all variables. AN size : aneurysm size, D : dome, N : neck

21 (56%) were treated with surgical clipping and 17 (44%) were treated with coil embolization. Of the 32 patients with 2 unfavorable characteristics (score 2), 20 (63%) were treated with surgical clipping and 12 (37%) were treated with coil embolization. Of the 18 patients with 3 unfavorable characteristics (score 3), 12 (67%) were treated with surgical clipping and 6 (33%) were treated with coil embolization. Of the 12 patients with 4 unfavorable characteristics (score 4), 11 (92%) were treated with surgical clipping and 1 (8%) was treated with coil embolization. The 1 patient (100%) who had 5 unfavorable characteristics (score 5) was treated with surgical clipping (Table 2).

We experienced 14 (17%) patients with intracerebral hematoma (ICH) out of 81 patients with ruptured AcoA aneurysms.



**Fig. 1.** The morphologic score is calculated by the summation of the five anatomical characteristics. A : Three dimensional and digital subtraction angiography (working angle) shows elongated shape anterior communicating artery aneurysm. The morphologic score is 0 [aneurysm size (0)+dome to neck ratio (0)+neck size (0)+vessel incorporation (0)+multiple lobulation (0)]. This patients was treated by coil embolization. B : Three dimensional angiography shows multilobulated anterior communicating artery aneurysm. The morphologic score is 4 [aneurysm size (0)+dome to neck ratio (1)+neck size (1)+vessel incorporation (1)+multiple lobulation (1)]. This patient was treated by surgical clipping.



**Fig. 2.** A ruptured anterior communicating artery aneurysm of a 60-year-old woman. A : Initial CT scan shows subarachnoid hemorrhage (SAH) with intracerebral hemorrhage (ICH). She was initially assessed with Hunt and Hess (H-H) grade 4 and right frontal intracerebral hemorrhage (ICH) is measured 20 mL volume. B : Cerebral angiography shows right middle cerebral artery aneurysm and ACoA aneurysm with the dominant A1 on the left side. C : Endovascular coiling of ACoA aneurysm was performed with 2 catheter method. D : Subsequently, right craniotomy with clipping of middle cerebral artery aneurysm and evacuation of right frontal intracerebral hematoma was performed. She was discharged with Glasgow Outcome Scale (GOS) 3. ACoA : anterior communicating artery.

They had frontal ICHs with 3 mL to 20 mL volumes. Among them, 5 patients were treated with surgical clipping and 9 patients were treated with coil embolization (Table 2). Three patients were treated by surgical clipping with simultaneous ICH evacuation, and one patients underwent endovascular coiling with subsequent ICH evacuation with contralateral craniotomy

(Fig. 2). Remaining 10 patients were treated conservatively.

### Clinical results

A total of 112 with AcoA aneurysms were treated with surgical clipping or coil embolization, 72 of whom (64%) were in good pretreatment neurological condition and 40 of whom (36%) were

in poor condition. In the good neurological condition group, 70 patients (97%) were neurologically intact or unchanged after treatment; in the poor neurological condition group, 12 patients (88%) showed poor neurological outcome (Table 4).

In the group of patients treated by surgical clipping, 46 patients had good initial neurological condition; 44 of these patients (96%) showed a good clinical outcome, whereas 2 patients (4%) showed neurological deterioration. Both of the latter patients' initial H-H grades were 2 and GOS at discharge were 3.

In the group of patients treated with coil embolization, 26 patients had a good initial neurological condition, and no patients presented with new neurological deficit or deterioration (Table 5). Only 1 patient had a procedural complication (procedural rupture of aneurysm without complete occlusion); fortunately, there were no associated neurological complications (Fig. 3).

**Analysis of data**

Uni- and multivariate analyses summarized the clinical and morphological factors affecting treatment decisions. The OR compared coiled patients and clipped patients. By univariate analysis, prognostic factors affecting treatment decisions included age (OR, 2.57; CI, 1.02-6.47), aneurysm size (OR, 0.32; CI, 0.11-0.92), dome-to-neck ratio (OR, 0.25; CI, 0.094-0.64), vessel-incorporated aneurysm (OR, 0.15; CI, 0.018-1.17), and morphologic score (OR, 0.35; CI, 0.14-0.90).

In multivariate analysis, age was the only clinical factor identified as affecting treatment decisions. Older patients had significantly higher odds of being treated with coil vs. clipping (adjusted OR, 3.78; 95% CI, 1.39-10.3;  $p=0.0093$ ). Morphological score was the only anatomical factor identified as affecting treatment decisions (Table 6).

The 5 variables used to calculate the scores were excluded from multivariate analysis to reduce bias due to multicollinearity, a statistical phenomenon in which 2 or more predictor variables in

a multiple regression model are highly correlated.

For analysis of the clinical results between the surgical clipping group and the coil embolization group, the Breslow-Day test was used to investigate homogeneity of the OR between the 2 methods. The result indicates that the association between H-H grade and clinical outcome was similar between the 2 methods ( $p$ -value=0.31) (Table 5).

In coil embolization group, we analyzed anatomical outcomes according to morphologic score. twenty-five patients (96%) showed good anatomic results among 26 patients who had initially favorable anatomic condition (morphologic score <2) and 12 patients (63%) showed good anatomic results among 19 patients who had initially unfavorable anatomic condition (morphologic score  $\geq 2$ ) ( $p$ -value=0.0064). Only 2 patients (28%) showed good anatomical results among 7 patients who had more than 3 unfavorable factors ( $p$ -value <0.0001) (Table 7).

**DISCUSSION**

The ACoA is the most common site of cerebral aneurysms, accounting for as many as 36% of aneurysms<sup>3</sup>. Treatment of these aneurysms includes microsurgical clipping and coil embolization. Since the introduction of the Guglielmi detachable

**Table 4.** Clinical outcomes according to initial neurological state

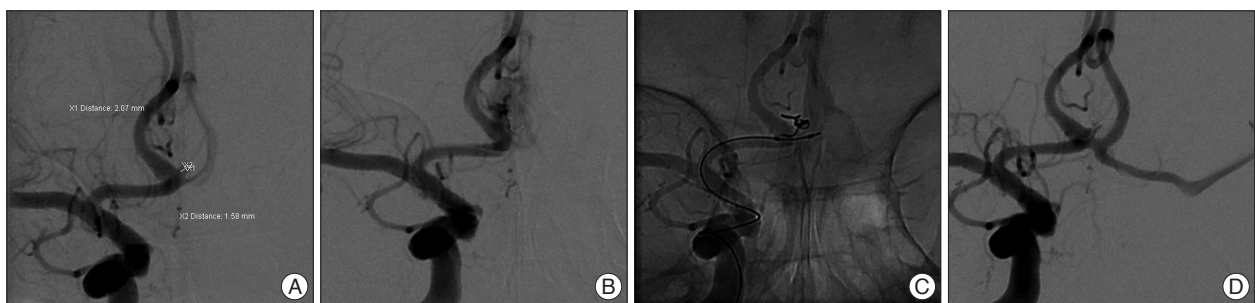
		GOS (%)		Total	<i>p</i> -value
		Good	Poor		
H-H grade	Good	70 (73)	2 (12)	72	<0.0001
	Poor	25 (27)	12 (88)	40	
Total		95	17	112	

GOS : Glasgow Outcome Scale, H-H grade : Hunt and Hess grade

**Table 5.** Comparison of clinical outcomes between clipped and coiled patients

		Clip			Coil		
		GOS (%)		<i>p</i> -value	GOS (%)		<i>p</i> -value
		Good	Poor		Good	Poor	
H-H grade	Good	44 (76)	2 (22)	0.0039	26 (70)	0 (0)	0.0060
	Poor	14 (24)	7 (78)		11 (30)	8 (100)	

Breslow-Day test for homogeneity of the odds ratio,  $p$ -value=0.31. GOS : Glasgow Outcome Scale, H-H grade : Hunt and Hess grade



**Fig. 3.** A ruptured anterior communicating artery aneurysm of a 63-year-old woman. A : Right carotid angiogram showing a small (2×1.6 mm) aneurysm in the anterior communicating artery. B : During coil embolization, the aneurysm is perforated upon insertion of the first frame coil. C : The HyperForm balloon is positioned across the neck and inflated for rescue. D : Tamponade of the perforating site using the HyperForm balloon. After a few minutes, there is no bleeding.

**Table 6.** Uni- and multivariate analyses of clinical and anatomical factors determining treatment decision

Variable	Univariate			Multivariate		
	OR*	95% CI	p-value	OR	95% CI	p-value
Score (≥2 vs. <2)	0.35	(0.14, 0.90)	0.030	0.23	(0.16, 0.93)	0.0039
Age (≥65 vs. <65)	2.57	(1.02, 6.47)	0.044	4.26	(1.42, 12.8)	0.0099
H-H grade (poor vs. good)	1.28	(0.57, 2.88)	0.55			
Neurological comorbidity (yes vs. no)	1.79	(0.79, 4.04)	0.16			
Medical comorbidity (yes vs. no)	0.47	(0.091, 2.46)	0.37			
GOS (poor vs. good)	0.95	(0.29, 3.06)	0.93			
ACoA patency (+ vs. -)	1.69	(0.76, 3.74)	0.20			
AN size (small or large vs. medium)	0.32	(0.11, 0.92)	0.035			
D to N ratio (<2 vs. ≥2)	0.25	(0.094, 0.64)	0.0041			
Vessel incorporation (yes vs. no)	0.15	(0.018, 1.17)	0.0041			
Multiple lobulation (yes vs. no)	0.57	(0.25, 1.27)	0.17			
Neck (<4 vs. ≥4)	1.11	(0.48, 2.56)	0.81			

\*OR refers to odds ratio of coiled patients vs. clipped patients. ACoA : anterior communicating artery, AN size : aneurysm size, GOS : Glasgow outcome scale, H-H grade : Hunt and Hess grade, D : dome, N : neck, OR : odds ratio, CI : confidence interval

**Table 7.** Anatomical outcomes according to morphological score

Score	Outcome (%)*		Total	p-value
	Good (1)	Poor (2, 3)		
<2	25 (96)	1 (4)	26	0.0064
≥2	12 (63)	7 (37)	19	
<3	35 (92)	3 (8)	38	<0.0001
≥3	2 (28)	5 (72)	7	

\*Outcome were classified using modified Raymond scale

**Table 8.** Comparison of odds ratios between different score criteria

Variable	Multivariate		
	OR*	95% CI	p-value
Score (≥2 vs. <2)	0.23	(0.16-0.93)	0.0039
Score (≥3 vs. <3)	0.19	(0.057-0.64)	0.0072

\*OR refers to odds ratio of coiled patients vs. clipped patients. CI : confidence interval

coils in 1991 for the treatment of intracranial aneurysms, a growing number of ruptured and unruptured cases have been treated using endovascular techniques<sup>8,9,21,28</sup>.

Several clinical trials comparing the use of endovascular coil embolization vs. microsurgical clipping have produced results that have been the object of numerous discussions and interpretations<sup>19,30</sup>, but generalizations based on our current knowledge are inappropriate and underestimate the complexity of intracranial aneurysms and their treatment.

Choosing between endovascular and microsurgical approach should be done cautiously because they have wide heterogeneous factors like patient age, clinical and neurological condition, anatomic abnormalities surrounding aneurysms, morphological

characteristics of the aneurysm itself, and the patient's and family's opinion.

Several papers have reported endovascular treatment of AcoA aneurysms<sup>21,23</sup> and emphasized the close correlation between the vessel and the aneurysm's anatomic architecture and the need for a more meticulous anatomic analysis. Treatment of ACoA aneurysms has some definite characteristics compared to that of other aneurysms.

The surgical approach may be difficult because of the complex arterial relationship, perforator preservation, frequent association between aneurysms and AcoA anomaly, and the potential for cognitive dysfunction. Especially, the high positioned ACoA aneurysms or posterior superior directed AcoA aneurysms have an additional complicating features. They need more brain retraction or their neck is usually associated intimately with the hypothalamic or infundibular perforators and frequently, one or both A2 segments densely adherent to the body of the aneurysm<sup>5,7,20,23</sup>.

With regard to the endovascular technique, firstly, many AcoA aneurysms have very small sacs, which makes it difficult to distinguish between the aneurysm neck and the microcatheter selection, leading to a few disadvantages. In our cases, 17 of 112 aneurysms (15%) had very small sacs, and 15 of these patients (88%) were treated with surgical clipping. The second disadvantage of endovascular treatment for AcoA aneurysms is poor controllability and trackability due to arterial morphology and the acute angle during the endovascular

procedure. Moret et al.<sup>20</sup> reported that the main causes of failure to embolize were loops in the cervical and intracranial vessels despite using the cervical approach when necessary and acute angle changes of the posterior projection of the aneurysm<sup>23</sup>.

Furthermore, the lumen of the AcoA is relatively small, and remodeling neck techniques using balloons or stents is particularly difficult when treating wide neck or complex aneurysms. In our cases, we used the neck remodeling technique in 10 of 45 (22%) patients of the coil embolization group.

The authors supposed that the treatment modality of AcoA aneurysms is affected more by anatomic factors than other aneurysms. However, optimal treatment for AcoA aneurysms cannot be determined by any one anatomic characteristic; rath-

er, all of the morphological features and clinical factors must be considered.

Many papers have emphasized the need for a collaborative approach to treatment strategies and have shown varying tendencies toward coiling or clipping<sup>6,12,16,24,26</sup>.

Our decision-making process during recent years has become increasingly more based on collaboration. All patient cases are discussed by a team including at least one endovascular specialist, one neurosurgeon, and one neurologist. Those presenting acutely are always routinely reviewed by both a surgeon and an endovascular radiologist.

In our study, we correlated 5 clinical factors and 5 anatomical factors related to determining treatment modality with clinical and anatomical outcomes. Of the 5 clinical factors, age was the important factor in both uni- and multivariate analysis. Older patients (age, >65 years) had significantly higher odds of being treated with coil embolization vs. clipping (adjusted OR, 3.78; 95% CI, 1.39-10.3;  $p=0.0093$ ). The anatomical factors that affected initial treatment modality decision included aneurysm size (small or large vs. medium), neck size (<4 vs.  $\geq 4$ ) dome-to-neck ratio (<2 vs.  $\geq 2$ ), vessel incorporation, multiple lobulation, and morphologic score. Among these 5 anatomical factors, small or large size, dome-to-neck ratio <2, vessel incorporation, and morphologic score  $\geq 2$  were statistically significant in univariate analysis. In multivariate analysis, only morphologic score was statistically significant. Patients with more than 2 unfavorable factors were treated with surgical clipping 4.34 times more often than with coil embolization. Furthermore, higher scoring patients had a higher tendency to be treated with surgical clipping (Table 8).

In the clinical analysis, there was no significant statistical discrepancy between the surgical clipping and coil embolization groups. Anatomically, coil embolization patients with higher morphologic scores had poorer anatomical results. The quantitative results of our evaluation demonstrate the lower success rate of endovascular treatment as the favorable anatomic characteristics dissipate.

This score model demonstrated that a comprehensive morphological factor is more important than an isolated anatomical feature for determining treatment modality; furthermore, these factors influenced not only decision making but also treatment results.

The limitations of this study include the retrospective design, the lack of long-term follow-up results, the difference of evaluation method in the anatomical results between surgical clipping and coil embolization group, and the absence of other factors that might influence decision making such as demand of patient or patient's family.

## CONCLUSION

In our analysis, age was the important clinical factor for determining treatment modality; from the anatomical viewpoint,

3 factors were independent variables that affected decision making. In multivariate analysis, morphologic score was the only anatomic factor that affected treatment decisions. These findings suggest that the optimal decision for the treatment of ACoA aneurysms cannot be determined by any one anatomic characteristic but all morphological features need to be considered, and that microsurgical clipping remains a valid treatment modality for patients with multiple unfavorable factors for coil embolization.

A detailed morphological analysis should be performed to select the best treatment modality; therefore, a collaborative neurovascular team approach is essential for treating ACoA aneurysms.

## • Acknowledgements

This work was supported by the Dong-A University Research Fund.

## References

- Barker FG 2nd, Amin-Hanjani S, Butler WE, Hoh BL, Rabinov JD, Pryor JC, et al : Age-dependent differences in short-term outcome after surgical or endovascular treatment of unruptured intracranial aneurysms in the United States, 1996-2000. *Neurosurgery* 54 : 18-28; discussion 28-30, 2004
- Bendok BR, Hanel RA, Hopkins LN : Coil embolization of intracranial aneurysms. *Neurosurgery* 52 : 1125-1130; discussion 1130, 2003
- Brisman JL, Song JK, Newell DW : Cerebral aneurysms. *N Engl J Med* 355 : 928-939, 2006
- Byrne JV, Sohn MJ, Molyneux AJ, Chir B : Five-year experience in using coil embolization for ruptured intracranial aneurysms : outcomes and incidence of late rebleeding. *J Neurosurg* 90 : 656-663, 1999
- Cognard C, Weil A, Spelle L, Piotin M, Castings L, Rey A, et al : Long-term angiographic follow-up of 169 intracranial berry aneurysms occluded with detachable coils. *Radiology* 212 : 348-356, 1999
- Cowan JA Jr, Ziewacz J, Dimick JB, Upchurch GR Jr, Thompson BG : Use of endovascular coil embolization and surgical clip occlusion for cerebral artery aneurysms. *J Neurosurg* 107 : 530-535, 2007
- Fertl E, Killer M, Eder H, Linzmayer L, Richling B, Auff E : Long-term functional effects of aneurysmal subarachnoid haemorrhage with special emphasis on the patient's view. *Acta Neurochir (Wien)* 141 : 571-577, 1999
- Graves VB, Strother CM, Duff TA, Perl J 2nd : Early treatment of ruptured aneurysms with Guglielmi detachable coils : effect on subsequent bleeding. *Neurosurgery* 37 : 640-647; discussion 647-648, 1995
- Guglielmi G, Viñuela F, Dion J, Duckwiler G : Electrothrombosis of saccular aneurysms via endovascular approach. Part 2 : Preliminary clinical experience. *J Neurosurg* 75 : 8-14, 1991
- Jennett B, Bond M : Assessment of outcome after severe brain damage. *Lancet* 1 : 480-484, 1975
- Kassel NF, Torner JC, Haley EC Jr, Jane JA, Adams HP, Kongable GL : The International Cooperative Study on the Timing of Aneurysm Surgery. Part 1 : Overall management results. *J Neurosurg* 73 : 18-36, 1990
- Khandelwal P, Kato Y, Sano H, Yoneda M, Kanno T : Treatment of ruptured intracranial aneurysms : our approach. *Minim Invasive Neurosurg* 48 : 325-329, 2005
- Koivisto T, Vanninen R, Hurskainen H, Saari T, Hernesniemi J, Vapalahti : Outcomes of early endovascular versus surgical treatment of ruptured cerebral aneurysms. A prospective randomized study. *Stroke* 31 : 2369-2377, 2000
- Kwon OK, Kim SH, Oh CW, Han MH, Kang HS, Kwon BJ, et al : Embolization of wide-necked aneurysms with using three or more micro-

- catheters. *Acta Neurochir (Wien)* 148 : 1139-1145; discussion 1145, 2006
15. Levy DI : Embolization of wide-necked anterior communicating artery aneurysm : technical note. *Neurosurgery* 41 : 979-982, 1997
  16. Lubicz B, Balériaux D, Lefranc F, Brotchi J, Bruneau M, Levivier M : Endovascular treatment of intracranial aneurysms as the first therapeutic option. *J Neuroradiol* 34 : 250-259, 2007
  17. Lubicz B, Leclerc X, Levivier M, Brotchi J, Pruvo JP, Lejeune JP, et al. : Retractable self-expandable stent for endovascular treatment of wide-necked intracranial aneurysms : preliminary experience. *Neurosurgery* 58 : 451-457; discussion 451-457, 2006
  18. Lylyk P, Ferrario A, Pasbón B, Miranda C, Doroszuk G : Buenos Aires experience with the Neuroform self-expanding stent for the treatment of intracranial aneurysms. *J Neurosurg* 102 : 235-241, 2005
  19. Molyneux A, Kerr R, Stratton I, Sandercock P, Clarke M, Shrimpton J, et al. : International Subarachnoid Aneurysm Trial (ISAT) of neurosurgical clipping versus endovascular coiling in 2143 patients with ruptured intracranial aneurysms : a randomised trial. *Lancet* 360 : 1267-1274, 2002
  20. Moret J, Pierot L, Boulin A, Castaings L, Rey A : Endovascular treatment of anterior communicating artery aneurysms using Guglielmi detachable coils. *Neuroradiology* 38 : 800-805, 1996
  21. Murayama Y, Viñuela F, Duckwiler GR, Gobin YP, Guglielmi G : Embolization of incidental cerebral aneurysms using the Guglielmi detachable coil system. *J Neurosurg* 90 : 207-214, 1998
  22. Nguyen TN, Hoh BL, Amin-Hanjani S, Pryor JC, Ogilvy CS : Comparison of ruptured vs unruptured aneurysms in recanalization after coil embolization. *Surg Neurol* 68 : 19-23, 2007
  23. Proust F, Debono B, Hannequin D, Gerardin E, Clavier E, Langlois O, et al. : Treatment of anterior communicating artery aneurysms : complementary aspects of microsurgical and endovascular procedures. *J Neurosurg* 99 : 3-14, 2003
  24. Quadros RS, Gallas S, Noudel R, Rousseaux P, Pierot L : Endovascular treatment of middle cerebral artery aneurysms as first option : a single center experience of 92 aneurysms. *AJNR Am J Neuroradiol* 28 : 1567-1572, 2007
  25. Raymond J, Guilbert F, Weill A, Georganos SA, Juravsky L, Lambert A, et al. : Long-term angiographic recurrences after selective endovascular treatment of aneurysms with detachable coils. *Stroke* 34 : 1398-1403, 2003
  26. Sakowitz OW, Raabe A, Vucak D, Kiening KL, Unterberg AW : Contemporary management of aneurysmal subarachnoid hemorrhage in germany : results of a survey among 100 neurosurgical departments. *Neurosurgery* 58 : 137-145; discussion 137-145, 2006
  27. van der Schaaf I, Algra A, Wermer M, Molyneux A, Clarke M, van Gijn J, et al. : Endovascular coiling versus neurosurgical clipping for patients with aneurysmal subarachnoid haemorrhage. *Cochrane Database Syst Rev* : CD003085, 2005
  28. Viñuela F, Duckwiler G, Mawad M : Guglielmi detachable coil embolization of acute intracranial aneurysm : perioperative anatomical and clinical outcome in 403 patients. *J Neurosurg* 86 : 475-482, 1997
  29. Weir B, Amidei C, Kongable G, Findlay JM, Kassell NF, Kelly J, et al. : The aspect ratio (dome/neck) of ruptured and unruptured aneurysms. *J Neurosurg* 99 : 447-451, 2003
  30. Wiebers DO, Whisnant JP, Huston J 3rd, Meissner I, Brown RD Jr, Piepgras DG, et al. : Unruptured intracranial aneurysms : natural history, clinical outcome, and risks of surgical and endovascular treatment. *Lancet* 362 : 103-110, 2003