

Clinical Article

Position Change of the Neurovascular Structures around the Carpal Tunnel with Dynamic Wrist Motion

Jae Yoel Kwon, M.D.,¹ Ji Young Kim, M.D.,² Jae Taek Hong, M.D., Ph.D.,¹ Jae Hoon Sung, M.D.,¹ Byung Chul Son, M.D.,¹ Sang Won Lee, M.D.¹

Departments of Neurosurgery,¹ Diagnostic Radiology,² St. Vincent's Hospital, The Catholic University of Korea College of Medicine, Suwon, Korea

Objective : The purpose of this study was to determine the anatomic relationships between neurovascular structures and the transverse carpal ligament so as to avoid complications during endoscopic carpal tunnel surgery.

Methods : Twenty-eight patients (age range, 35-69 years) with carpal tunnel syndrome were entered into the study. We examined through wrist magnetic resonance imaging in three different positions (neutral, radial flexion, and ulnar flexion) and determined several anatomic landmark (distance from the hamate hook to the median nerve, ulnar nerve, and ulnar vessel) based on the lateral margin of the hook of the hamate. The median nerve and ulnar neurovascular structure were studied with the wrist in the neutral, ulnar, and radial flexion positions.

Results : The ulnar neurovascular structures usually passed just over or ulnar to the hook of the hamate. However, in 12 hands, a looped ulnar artery coursed 0.6-3.3 mm radial to the hook of the hamate and continued to the superficial palmar arch. The looped ulnar artery migrates on the ulnar side of Guyon's canal (-5.2-1.8 mm radial to the hook of the hamate) with the wrist in radial flexion. During ulnar flexion of the wrist, the ulnar artery shifts more radially beyond the hook of the hamate (-2.5-5.7 mm).

Conclusion : It is appropriate to transect the ligament greater than 4 mm apart from the lateral margin of the hook of the hamate without placing the edge of the scalpel toward the ulnar side. We would also recommend not transecting the transverse carpal ligament in the ulnar flexed wrist position to protect the ulnar neurovascular structure.

Key Words : Carpal tunnel syndrome · Ulnar neurovascular structures · Wrist position.

INTRODUCTION

Carpal tunnel syndrome (CTS) is the most frequent compressive peripheral neuropathy. Surgical treatment of CTS continues to be one of the most frequently performed operations for peripheral neuropathy^{2,3,14}. Open carpal tunnel release (OCTR) has been the standard treatment for CTS that has failed non-surgical treatment and has provided excellent results, but could be associated with post-operative pillar pain, delayed improvement of pinch strength, and a slow return to work^{7,11,24}.

Many investigators have described various types of endoscopic carpal tunnel release (ECTR) procedures to decrease post-operative pillar pain and the duration of the hospital stay^{5,6,20}. Although the learning curve of ECTR could be rather steep and complications in ECTR are not less frequent than OCTR, acceptable clinical outcomes of median nerve decompression after ECTR have been reported^{10,15}.

Understanding the anatomic relationship of the neurovascular structures to the carpal tunnel is critical in preventing damage, thus leading to decreased morbidity.

Some investigators have studied the anatomic variations of the carpal tunnel contents and the anatomic relationship of the carpal tunnel to Guyon's canal based on cadaveric specimens^{3,7,8,11,14} and reported positional variability of ulnar neurovascular structures with different wrist positions^{4,8,9,13,17,22}. However, results about deviation of neurovascular structures are based upon dissected specimens which may not entirely represent intra-operative situations when normal anatomy is not violated.

Thus, the purpose of this study was to demonstrate the relationship between carpal tunnel and neurovascular structures in Guyon's canal in a group of patients with CTS and to confirm the change in location of the ulnar neurovascular structures with different wrist motions in patients with CTS when the normal anatomy is not violated.

MATERIALS AND METHODS

Twenty-eight patients with CTS were examined through wrist magnetic resonance (MR) imaging in three different positions (neutral, radial flexion, and ulnar flexion) from 2004 to 2007. The patients ranged 35 to 69 in age (mean, 51.2 years old) and

• Received : March 16, 2011 • Revised : August 23, 2011

• Accepted : October 13, 2011

• Address for reprints : Jae Taek Hong, M.D., Ph.D.

Department of Neurosurgery, St. Vincent's Hospital, The Catholic University of Korea College of Medicine, 93 Jungbu-daero, Paldal-gu, Suwon 442-723, Korea

Tel : +82-31- 249-7190, Fax : +82-31-245-5208

E-mail : jatagi15@paran.com

consisted of 4 males and 24 females. All imaging was done on a 1.5-T signa scanner (General Electric, Milwaukee, WI, USA) with a wrist coil. Spin echo T1- and T2-weighted images of the carpal tunnel region were obtained with the wrist in a neutral position, and also in 25 degree radially-flexed and 50 degree ulnarly-flexed positions. Our MR imaging study included the performance of a routine protocol set of transverse T1-weighted (repetition time msec/echo time msec, 700/11; matrix, 256×256; number of signals acquired, one; field of view, 12 cm; imag-

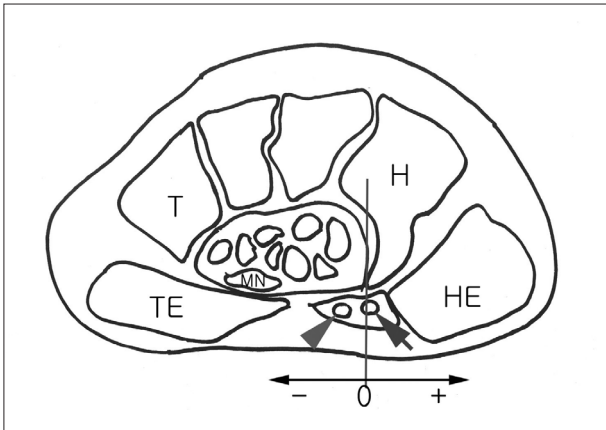


Fig. 1. Diagrammatic image of magnetic resonance scan showing reference measurements of neurovascular structures. MN : median nerve, HE : hypothenar eminence, TE : thenar eminence, H : hamate, T : trapezium, arrowhead : ulnar artery, arrow : ulnar nerve.

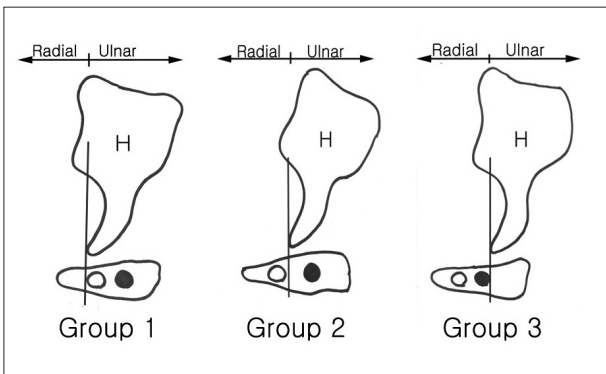


Fig. 2. Illustration reveals three different groups of overlap of Guyon's canal contents with the hook of the hamate (H).

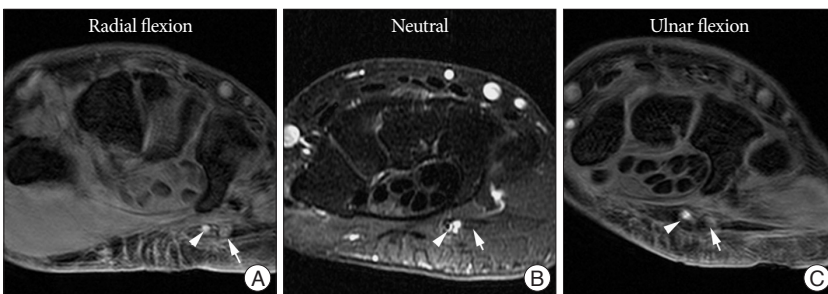


Fig. 3. Magnetic resonance imaging with different wrist position reveals a dynamic displacement of the contents of Guyon's canal with changing wrist positions and a progressive radial migration of the ulnar neurovascular structures as the wrist position moved from radial flexion (A) through neutral (B), and then to ulnar flexion (C) (arrowhead : ulnar artery, arrow : ulnar nerve).

ing time, 2 minutes 29 seconds) and T2- and intermediate-weighted (2,000/20, 70; matrix, 256×256; number of signals acquired, one; field of view, 12 cm; imaging time, 6 minutes 48 seconds) dual spin-echo sequences in which the section thickness was 4 mm without an intersection gap. In addition, we performed a coronal contrast-enhanced frequency selective fat-suppressed 3D fast SPGR (spoiled gradient-recalled acquisition in the steady state) sequence (20.9/2.2; flip angle, 15°; matrix, 256×192; number of signals acquired, one; field of view, 12 cm). We performed MRIs in 28 patients to determine how far the vital neurovascular structures of Guyon's canal were located radially and whether the vital neurovascular structures of Guyon's canal overlap the carpal tunnel at the hook of the hamate.

The axial images were obtained with a slice thickness of 3 mm, and the lateral margin of the hamate hook was used as a reference point to perform measurements on the structures in the distal Guyon's canal. Linear measurements were made using m-view 5.4 software (Marosis Technologies, Inc., Seoul, Korea).

The distance between the midpoints of the neurovascular structures and the lateral margin of the hamate hook was measured with the wrist in neutral, radial, and ulnar flexion. With respect to the relationship between the hook of the hamate and adjacent structures, and based on the lateral margin of the hook of the hamate, Guyon's canal side (ulnar side) was designated as positive and the carpal tunnel side (the radial side) was designated as negative (Fig. 1).

We classified the patients into three groups based on the degree of overlapping of the contents of Guyon's canal with the carpal tunnel. Group 1 included patients in whom the ulnar nerve and artery were located ulnar side to the hook of the hamate. Group 2 included patients in whom the ulnar artery was located radial side to the hook of the hamate, while the ulnar nerve was located ulnar side to the hook of the hamate. Group 3 included patients in whom both ulnar neurovascular structures were radial side to the hook of the hamate (Fig. 2).

RESULTS

There was a dynamic displacement of the contents of Guyon's canal with a change in wrist position. Progressive radial migration of the ulnar neurovascular structures was noted as the wrist position moved from radial flexion through neutral, and then to ulnar flexion (Fig. 3).

The ulnar nerve was usually positioned ulnar to the hook of the hamate with the wrist held in the neutral position. However, there was an unusual case in which the ulnar nerve was located radial (-1.1 mm) to the hook of the hamate. The ulnar artery was on average located near the carpal tunnel, with the average position only 0.1 mm ulnar to the hamate.

The median nerve was progressively migrated radially as the wrist position moved from radial flexion through neutral, and then to ulnar flexion.

In 12 of 28 patients the ulnar artery was positioned radial to the hook of the hamate, even in the neutral position, and in 1 of the patients the ulnar artery was 3.3 mm radial to the hamate hook, which was displaced as far as 5.7 mm radial to the hamate hook on ulnar flexion (Table 1).

The contents of Guyon's canal overlapped the superficial surface of the carpal tunnel by 43% in the neutral position. With ulnar flexion, the overlap of Guyon's canal relative to the carpal tunnel was maximal (85%) (Table 2).

DISCUSSION

Carpal tunnel surgery has evolved to decrease the rate of complications, and minimally invasive surgical techniques have become widespread compared with open surgery²³.

The avoidance of surgical complications lies in proper knowledge of anatomy of the wrist and the surgeon's experience^{1,21}. There are several anatomic structures prone to be injured during carpal tunnel release surgery, such as the recurrent motor and palmar cutaneous branches of the median nerve, the superficial palmar arch, Beretini's branch, and the ulnar neurovascular structures¹⁸.

According to a recent report, there are differences between open surgery and endoscopic surgery, in terms of complications¹⁷. Palmer et al.¹⁷ reviewed complications of ECTR and OCTR over a 5-year period and found that in contrast with OCTR, vessel structures are more prone to be injured during ECTR. Such injuries might be due to the fact that the ulnar artery and nerve in the distal Guyon's canal are deviated radially and overlap the carpal tunnel^{4,9,16}. In the distal portion of the canal, splayed ulnar neurovascular structures might be more vulnerable to injury during carpal tunnel release surgery.

In the current study there was substantial overlap of the contents of Guyon's canal across the transverse carpal ligament in a high proportion of patients.

With ulnar flexion of the wrist, there is a further radial displacement of these ulnar neurovascular structures, which may be more vulnerable to be injured in both open and endoscopic surgery. These anatomical relationships are important for endoscopists because the wrist position can change unintentionally during surgery when using local anesthesia. Therefore, this information about the dynamic changes in the location of the neurovascular structures will help to ensure optimal placement of the incision site for endoscopy and mini-open surgery, as well

Table 1. Dynamic location change of the neurovascular structures with different wrist position

Wrist position	Median nerve	Ulnar nerve	Ulnar artery
Neutral	-9.7 mm (-6.5 to -13.2)	2.0 mm (-1.1 to 7.8)	0.1 mm (-3.3 to 4.7)
Radial flexion	-7.6 mm (-4.9 to -12.9)	3.0 mm (0.7 to 7.8)	0.5 mm (-1.8 to 5.2)
Ulnar flexion	-11.1 mm (-8.1 to -15.5)	1.2 mm (-1.7 to 5.8)	-1.9 mm (-5.7 to 2.5)

Table 2. The contents of Guyon's canal overlap the superficial surface of the carpal tunnel

Position	Group		
	Group 1	Group 2	Group 3
Neutral	16 (57%)	9 (32%)	3 (11%)
Ulnar flexion	4 (14%)	18 (64%)	6 (21%)
Radial flexion	19 (68%)	9 (32%)	0 (0%)

Group 1 included patients in whom the ulnar nerve and artery were located ulnar side to the hook of the hamate. Group 2 included patients in whom the ulnar artery was located radial side to the hook of the hamate, while the ulnar nerve was located ulnar side to the hook of the hamate. Group 3 included patients in whom both ulnar neurovascular structures were radial side to the hook of the hamate (Fig. 2).

as to facilitate the least intrusive positioning of the endoscope.

ECTR is a surgical procedure with a rather steep learning curve^{12,19}. Thus, a thorough knowledge of hand anatomy is critical to avoid complications during the procedure.

CONCLUSION

The optimal technique that avoids injury to blood vessels caused by anatomic variations of the ulnar artery may occur during resection of the TCL. The MR findings indicates that transecting the ligament approximately 4 mm radial to the radial margin of the hook of the hamate may minimize post-operative bleeding and help avoiding iatrogenic injury of the ulnar neurovascular structures which is more prone to be caused as the scalpel is withdrawn when the wrist is placed in ulnar flexion and when the edge of the blade is placed toward the ulnar side during ECTR.

References

- Alizadeh K, Lahiji F, Phalsaphy M : Safety of carpal tunnel release with a short incision. A cadaver study. *Acta Orthop Belg* 72 : 415-419, 2006
- Bártová V : [The carpal tunnel syndrome, its diagnosis and therapy.] *Vnitř Lek* 39 : 476-480, 1993
- Bland JD : Carpal tunnel syndrome. *Curr Opin Neurol* 18 : 581-585, 2005
- Boughton O, Adds PJ, Jayasinghe JA : The potential complications of open carpal tunnel release surgery to the ulnar neurovascular bundle and its branches : a cadaveric study. *Clin Anat* 23 : 545-551, 2010
- Chow JC, Hantes ME : Endoscopic carpal tunnel release : thirteen years' experience with the Chow technique. *J Hand Surg Am* 27 : 1011-1018, 2002
- Fabiano AJ, Rigual NR, Belber CS, Fenstermaker RA : Endoscopic sellar floor reconstruction with concha bullosa bone autograft and nasal septal flap : technical case report. *Minim Invasive Neurosurg* 52 : 86-88, 2009
- Filippi R, Reisch R, El-Shki D, Grunert P : Uniportal endoscopic surgery of carpal tunnel syndrome : technique and clinical results. *Minim Invasive Neurosurg* 45 : 78-83, 2002
- Goetz JE, Thedens DR, Kunze NM, Lawler EA, Brown TD : Day-to-day variability of median nerve location within the carpal tunnel. *Clin Bio-*

- mech (Bristol, Avon) 25** : 660-665, 2010
9. Hong JT, Lee SW, Han SH, Son BC, Sung JH, Park CK, et al. : Anatomy of neurovascular structures around the carpal tunnel during dynamic wrist motion for endoscopic carpal tunnel release. **Neurosurgery 58** : ONS127-ONS133; discussion ONS127- ONS133, 2006
 10. Karaeminoğullari O, Oztürk A, Tüzüner T, Ozturan KE : [Endoscopic carpal ligament release using the Chow technique : early clinical results.] **Acta Orthop Traumatol Turc 37** : 226-232, 2003
 11. Kıymaz N, Cırak B, Tuncay I, Demir O : Comparing open surgery with endoscopic releasing in the treatment of carpal tunnel syndrome. **Minimum Invasive Neurosurg 45** : 228-230, 2002
 12. Kretschmer T, Antoniadis G, Richter HP, König RW : Avoiding iatrogenic nerve injury in endoscopic carpal tunnel release. **Neurosurg Clin N Am 20** : 65-71, vi-vii, 2009
 13. Lanz U : Anatomical variations of the median nerve in the carpal tunnel. **J Hand Surg Am 2** : 44-53, 1977
 14. Miller BK, Gregory M : Carpal tunnel syndrome. **AORN J 38** : 525, 528, 530 passim, 1983
 15. Nagle DJ : Endoscopic carpal tunnel release. In favor. **Clin Plast Surg 23** : 477-486, 1996
 16. Netscher D, Polsen C, Thornby J, Choi H, Udeh J : Anatomic delineation of the ulnar nerve and ulnar artery in relation to the carpal tunnel by axial magnetic resonance imaging scanning. **J Hand Surg Am 21** : 273-276, 1996
 17. Park MJ, Namdari S, Yao J : Anatomic variations of the palmaris longus muscle. **Am J Orthop (Belle Mead NJ) 39** : 89-94, 2010
 18. Pollack HJ : [Risks in the surgical treatment of carpal tunnel syndrome.] **Beitr Orthop Traumatol 25** : 410-414, 1978
 19. Ryu SJ, Kim IS : Pseudoaneurysm of ulnar artery after endoscopic carpal tunnel release. **J Korean Neurosurg Soc 48** : 380-382, 2010
 20. Schmelzer RE, Della Rocca GJ, Caplin DA : Endoscopic carpal tunnel release : a review of 753 cases in 486 patients. **Plast Reconstr Surg 117** : 177-185, 2006
 21. Schmidt HM : [Surgical anatomy of the carpal tunnel.] **Handchir Mik-rochir Plast Chir 38** : 283-295, 2006
 22. Siegel JL, Davlin LB, Aulicino PL : An anatomical variation of the palmar cutaneous branch of the median nerve. **J Hand Surg Br 18** : 182-183, 1993
 23. Steinberg DR : Surgical release of the carpal tunnel. **Hand Clin 18** : 291-298, 2002
 24. Vasen AP, Kuntz KM, Simmons BP, Katz JN : Open versus endoscopic carpal tunnel release : a decision analysis. **J Hand Surg Am 24** : 1109-1117, 1999