

Inter-Rater Reliability of Abdominal Muscles Thickness Using Ultrasonography for Different Probe Locations and Thickness Measurement Techniques

One-bin Lim, B.H.Sc., P.T.

Ji-a Hong, B.H.Sc., P.T.

Dept. of Physical Therapy, The Graduate School, Yonsei University

Chung-hwi Yi, Ph.D., P.T.

Heon-seock Cynn, Ph.D., P.T.

Dept. of Physical Therapy, College of Health Science, Yonsei University

Dept. of Ergonomic Therapy, The Graduate School of Health and Environment, Yonsei University

Doh-heon Jung, B.H.Sc., P.T.

Il-woo Park, B.H.Sc., P.T.

Dept. of Physical Therapy, The Graduate School, Yonsei University

Abstract

Ultrasonography (US) is a recent technique that has proven to be useful for assessing muscle thickness and guiding the rehabilitation decision-making of clinicians and researchers. The purpose of this study was to determine the inter-rater reliability of the US measurement of transversus abdominis (TrA), internal oblique (IO), and external oblique (EO) thicknesses for different probe locations and measurement techniques. Twenty healthy volunteers were recruited in this study. Muscle thicknesses of the transversus TrA, IO, and EO were measured three times in the hook-lying position. The three different probe locations were as follows: 1) Probe location 1 (PL1) was below the rib cage in direct vertical alignment with the anterior superior iliac spine (ASIS). 2) Probe location 2 (PL2) was halfway between the ASIS and the ribcage along the mid-axillary line. 3) Probe location 3 (PL3) was halfway between the iliac crest and the inferior angle of the rib cage, with adjustment to ensure the medial edge of the TrA. The two different techniques of thickness measurement from the captured images were as follows: 1) Muscle thickness was measured in the middle of the muscle belly, which was centered within the captured image (technique A; TA). 2) Muscle thickness was measured along a horizontal reference line located 2 cm apart from the medial edge of the TrA in the captured image (technique B; TB). The intraclass correlation coefficient (ICC [3,k]) was used to calculate the inter-rater reliability of the thickness measurement of TrA, IO and EO using the values from both the first and second examiner. In all three muscles, moderate to excellent reliability was found for all conditions (probe locations and measurement techniques) (ICC=.70~.97). In the PL1-TA condition, inter-rater reliability in the three muscle thicknesses was good to excellent (ICC=.85~.96). The reliability of all measurement conditions was excellent in IO (ICC=.95~.97). Therefore, the findings of this study suggest that TA can be applied to PL1 by clinicians and researchers in order to measure the thickness of abdominal muscles.

Key Words: External oblique; Internal oblique; Inter-rater reliability; Muscle thickness; Transversus abdominis; Ultrasonography.

Introduction

Many clinicians and researchers have used ultra-

sonography (US) for therapeutic intervention aimed at improving neuromuscular function, and clinical rehabilitative research to inform clinical practice (Costa et

al, 2009; Teyhen, 2006; Whittaker et al, 2007). Recently, researchers have increasingly studied associations between underlying neuromuscular control deficits and neuromusculoskeletal disorders such as low back pain (LBP) (Ferreira et al, 2007; Hodges and Moseley, 2003; Teyhen, 2006; Teyhen, 2007; Whittaker et al, 2007). However, valid and reliable non-invasive measurement methods to assess neuromuscular control deficits that could be employed in a clinical setting have been insufficient (Teyhen, 2011). Evidence supporting the use of US as a method to assist patients with neuromusculoskeletal disorders is growing (Teyhen, 2011).

Although US is less sophisticated in terms of resolution than computed tomography (CT) and magnetic resonance imaging (MRI), it has advantages as a non-invasive, inexpensive, portable, safe, and clinically accessible method for gathering data about the static characteristics of muscle and muscle behavior during dynamic activities (Hides et al, 2001; Kiesel et al, 2007; Koppenhaver et al, 2009; Teyhen, 2011; Whittaker et al, 2007). As such, it shows promise as a measurement in musculoskeletal examination, evaluation, and intervention. Furthermore, in contrast with CT, US does not expose the patient to ionizing radiation and is well tolerated by patients (Whittaker et al, 2007). A characteristic unique to US is its dynamic capability to scan in real time, which makes it superior to CT and MRI for evaluating movable structures such as muscles, nerves, and tendons, and it may become an important tool for directing suitable clinical decision-making. Still, US is not without weaknesses, and is very examiner dependent. Possibly the most promising characteristics of US is its feasibility and accessibility, as it is easy for clinicians to acquire the skills needed to incorporate its use into clinical practice. Nevertheless, before widespread routine clinical use can be promoted, the evidence of validity and reliability for the use of US in different applications within rehabilitation is needed (Whittaker et al, 2007).

US is useful for evaluating the function of deep abdominal muscles (Critchley and Coutts, 2002; Henry

and Westervelt, 2005; Rankin et al, 2006). The transversus abdominis (TrA), internal oblique (IO), and external oblique (EO) are deep segmental muscles responsible for lumbar stability (Rankin et al, 2006). It is not possible to take direct force measurements to compare the strength of the abdominal muscles, but their thicknesses may provide an indirect measurement of force-generating capacity (Rankin et al, 2006). US has been used to measure abdominal muscle thickness in respiratory and biomechanical research (Krag et al, 1987; McGill et al, 1996).

Studies on the measurement of abdominal muscle thickness have used different probe locations and measurement techniques (Ferreira et al, 2004; Koppenhaver et al, 2009; Rankin et al, 2006; Springer et al, 2006; Teyhen et al, 2011). Rankin et al (2006) introduced two different probe locations: One probe was located immediately below the rib cage in direct vertical alignment with the anterior superior iliac spine (ASIS), whereas the other probe was located halfway between the ASIS and the rib cage along the mid-axillary line. Ferreira et al (2004) located a probe halfway between the iliac crest and the inferior angle of the rib cage, and then adjusted it to ensure the medial edge of the TrA. Springer et al (2006) and Teyhen et al (2011) measured the thickness of the abdominal muscles at the middle of the muscle belly, centered within the captured image. Ferreira et al (2004) determined the thickness of the abdominal muscles along a horizontal reference line located 2 cm apart from the medial edge of the TrA.

Although studies have been conducted on abdominal muscle thickness measurement, however, the inter-rater reliability of US measurements of TrA, IO, and EO thicknesses using different probe locations and measurement techniques have not been reported in the literature. Therefore, the purpose of this study was to compare the inter-rater reliability of the US measurement of TrA, IO, and EO thicknesses for different probe locations and measurement techniques.

Methods

Subjects

Twenty healthy subjects (8 males, 12 females) were recruited in this study. Subjects were excluded if they had a history of neurological, neuromuscular, dermatological, or systemic disease; previous or current LBP with symptoms of the severity that interfered with activities of daily living or that required treatment; previous surgery involving abdominal incisions; any history of lumbar surgery or spinal or pelvic fracture; or a history of taking medication that could affect muscle size (Rankin et al, 2006). Written informed consent was obtained from all subjects before the beginning of the study. The study was approved by the university's institutional review board. Table 1 summarizes the mean age, height, weight, and body mass index of the subjects.

Examiners

Prior to muscle thickness measurement, to reduce measurement error, two examiners participated in 20 hours of hands-on training for the specific US proto-

col including precise probe location, location of anatomical landmarks, pressure application, and the cursor marking point (Stokes et al, 2005). A proficiency evaluation was completed for each examiner before data collection. The examiners worked in pairs. One examiner was designated as the recorder, and the other examiner was designated as the imager. The imager was responsible for positioning the probe for best visualization of the musculature (Teyhen et al, 2011). Both the recorder and the imager had to agree on image placement and quality. After on-screen measurements were captured, the recorder recorded the image and measurement information. Throughout the test session, the imager was blinded to all probe locations (Teyhen et al, 2011).

Procedures

Images of the abdominal muscles were acquired at 25 Hz computerized US¹⁾, with a 50 mm 7.5 MHz linear array probe. The subjects were asked to assume the hook-lying position on an examination table. Prior to the study, subjects were asked to indicate their dominant side. The right side was dominant in all

Table 1. General characteristics of subjects

(N=20)

Characteristics	Mean±SD
Age (yrs)	21.2±2.4
Height (cm)	167.2±8.0
Weight (kg)	58.0±9.4
BMI ^a (kg/m ²)	20.6±2.1

^aBody Mass Index.

Table 2. Inter-rater reliability of the thickness measurement according to three probe locations and two measurement techniques for the lateral abdominal muscles

(N=20)

	TrA ^a	IO ^b	EO ^c
	ICC ^d (3,k) (95% CI ^e)	ICC (3,k) (95% CI)	ICC (3,k) (95% CI)
Probe location 1-Technique A	.85(.62~.94)	.96(.90~.98)	.92(.84~.97)
Probe location 2-Technique A	.70(.16~.89)	.96(.88~.99)	.95(.86~.98)
Probe location 3-Technique A	.72(.25~.90)	.95(.88~.98)	.84(.57~.94)
Probe location 3-Technique B	.74(.35~.90)	.97(.93~.99)	.89(.73~.96)

^atransversus abdominis, ^binternal oblique, ^cexternal oblique, ^dintra-class correlation coefficient, ^e95% confidence interval.

1) SonoAce X8, Medison Co Ltd, Seoul, Korea.

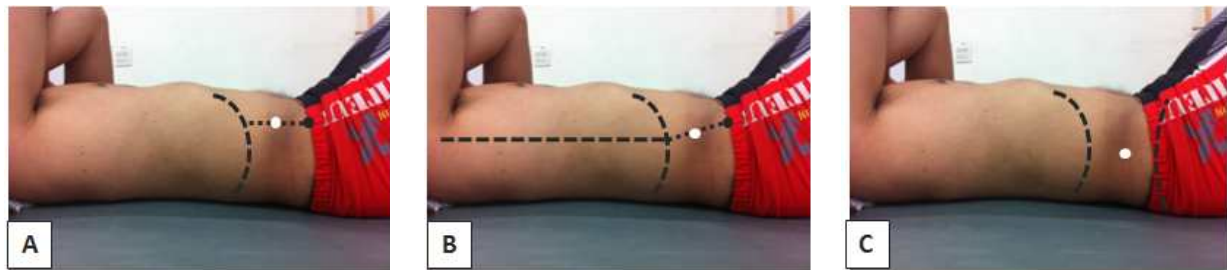

Figure 1. Three different probe locations. A: probe location 1 (PL1)–below the rib cage in direct vertical alignment with the anterior superior iliac spine (ASIS), B: probe location 2 (PL2)–halfway between the ASIS and the ribcage along the mid-axillary line, C: probe location 3 (PL3)–halfway between the iliac crest and the inferior angle of the rib cage and then adjusted to ensure the medial edge of the TrA.

subjects. Thus, right lateral abdominal muscles were captured by US. The probe location was marked by a marker pen so that the identical probe location was used in the test session (Ferreira et al, 2004). Images of each TrA, IO, and EO were acquired three times, and the mean value was used for data analysis (Costa et al, 2009). Examiners were randomly selected to control the order effect (Springer et al, 2006; Teyhen et al, 2011). After the first examiner finished the measurement, the subjects rested for 5 minutes to minimize fatigue. For consistency across subjects, images were collected directly at the end of inspiration at rest, as determined by visual inspection of the abdominal content (Springer et al, 2006). A total of 18 images were assessed for each subject, and a total of 360 images were analyzed.

Probe locations

Figure 1 depicts three different probe locations. Probe location 1 (PL1) was immediately below the rib cage in direct vertical alignment with the ASIS (Rankin et al, 2006). Probe location 2 (PL2) was halfway between the ASIS and the ribcage along the mid-axillary line (Rankin et al, 2006). Probe location 3 (PL3) was halfway between the iliac crest and the inferior angle of the rib cage; this was then adjusted to ensure the medial edge of the TrA (Ferreira et al, 2004).

Muscle thickness measurement techniques

Images captured by US revealed three distinct

muscle layers of the TrA, IO, and EO muscles on a monitor. Figure 2 illustrates the two different measurement techniques of the thickness of each muscle layer from the captured image: in the middle of the muscle belly, which was centered within the captured image (technique A; TA) (Springer et al, 2006; Teyhen et al, 2011) vs. along a horizontal reference line located 2 cm apart from the medial edge of the TrA in the captured image (technique B; TB) (Ferreira et al, 2004).

Statistical Analysis

For statistical analysis, the intraclass correlation coefficient (ICC [3,k]) with 95% confidence intervals was used to calculate the inter-rater reliability of the thickness measurement of TrA, IO, and EO using the values from both the first and second examiner. Each ICC was interpreted according to the following of the criteria proposed by Portney and Watkins (2009): $ICC < .50$, poor; $ICC = .50 \sim .75$, moderate; $ICC .75 < r < .90$, good; and $ICC > .90$, excellent. Data management and statistical analysis were performed using SPSS version 18.0 software.

Results

After the images were captured at PL1 and PL2, TB was not used, because the medial edge of the TrA was not found in the images. The medial edge

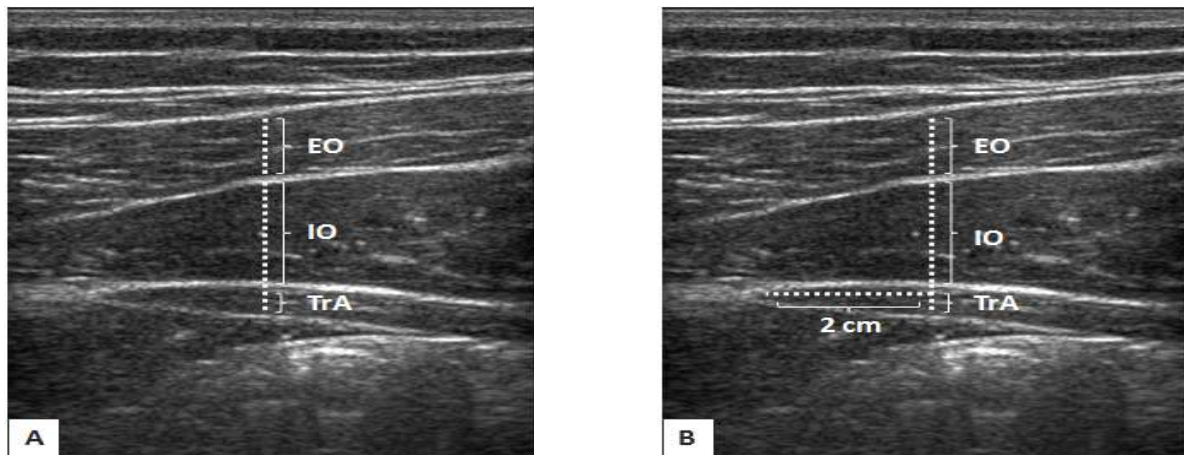


Figure 2. Two different measurement techniques. A: technique A, B: technique B (TrA: transversus abdominis, IO: internal oblique, EO: external oblique).

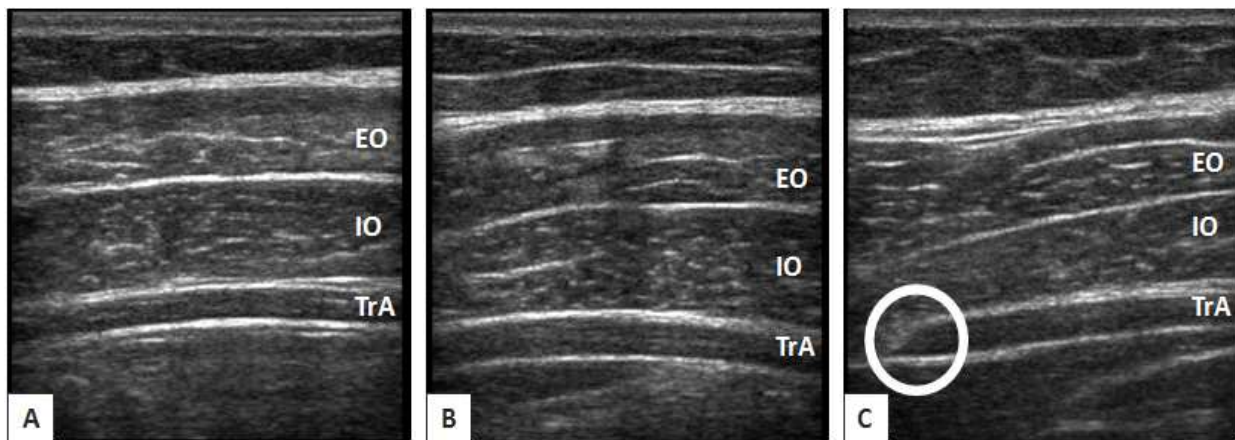


Figure 3. Captured images of the three different probe locations. A: probe location 1 (PL1), B: probe location 2 (PL2), C: probe location 3 (PL3), the medial edge of the TrA in the circle. (TrA: transversus abdominis, IO: internal oblique, EO: external oblique).

of the TrA was observed in the PL3 images; therefore, TB was used only for PL3 (Figure 3). Inter-rater reliability of the thickness measurement of the abdominal muscles for three probe locations and two measurement techniques is outlined in Table 2. In all three muscles, moderate to excellent reliability was found for all conditions (probe locations and measurement techniques) ($ICC=.70\sim.97$). In the PL1-TA condition, reliability in the three muscle thicknesses was good to excellent ($ICC=.85\sim.96$). The reliability of all measurement conditions was excellent in IO ($ICC=.95\sim.97$).

Discussion

The purpose of this study was to determine the inter-rater reliability of the US measurement of abdominal muscles for different probe locations and thickness measurement techniques. Overall, the results of this study showed moderate to excellent reliability for the different probe locations and thickness measurement techniques in TrA, IO, and EO. In particular, in IO, reliability for all measurement conditions was excellent. When the PL1-TA condition was applied, reliability was good to excellent in each

of the three muscle thickness. These findings are consistent with the previously published systematic reviews by Teyhen et al (2011) and validate the use of US imaging for reliable measurements of abdominal muscle thickness. Although previous studies have reported inter-rater reliability of the lateral abdominal muscles, the studies have been limited to TrA and total abdominal muscle thickness at the inspiration phase at rest (Springer et al, 2006). Our results also added to the existing literature by demonstrating the inter-rater reliability of the TrA, IO, and EO muscle thicknesses separately.

Teyhen et al (2007) demonstrated that many potential sources of measurement error in terms of muscle thickness could be attributed to image acquisition. The hypothesis of this study was largely influenced by the variability in probe locations on the body (Whittaker et al, 2007). Scant evidences exist to determine whether different locations used for digital measurement could influence inter-rater reliability. Therefore, one of the purposes of our study was to determine the optimal probe location for assessing lateral abdominal muscle thickness. The results of our study suggested that PL1 (where the probe was located below the rib cage in direct vertical alignment with ASIS) represents well three layers of muscles (TA, IO, and EO), relating well to the intermuscular fascial layer. Optimal interpretation of US requires a clear understanding of anatomical factors, including muscle origin, insertion, size, shape, depth, and fiber orientation (Teyhen et al, 2007). As the probe was positioned more anteriorly, where the center of the probe was along the anterior axillary line, the position allowed for visualization of the anterior reach of the lateral abdominal wall to be visible the TrA, IO, and EO (Teyhen et al, 2007).

In Korea, TB (muscle thickness measurement along a horizontal reference line located 2 cm apart from the medial edge of the TrA in the captured image) is more common than TA (muscle thickness measurement in the middle of the muscle belly centered within the captured image). In this study, while

using TB, the medial edge of TrA could not be determined at PL1 and PL2. Thus, we could only compare TA and TB at PL3. In our study, both TA and TB at PL3 showed moderate to excellent reliability, although the reliability of TB was higher than that of TA. The drawbacks of TB are that it is not only more time-consuming and less clinically feasible compared to TA, but also that it is not possible to consistently visualize the medial edge of the TrA. On the other hand, TA had a measurement error associated with the examiner estimating the middle of the muscle belly; however this error is probably minimal because the fascial lines are relatively parallel in the captured images (Teyhen et al, 2007).

To the best of our knowledge, this is the first study to demonstrate that an US can provide reliable measurements of the thickness of the TrA, IO, and EO muscles in healthy subjects. This study has also proven that non-invasive US can be used as an inexpensive, portable, safe, and clinically accessible method for clinicians and researchers.

Several limitations existed within this study. First, the thickness measurements of the TrA, IO, and EO muscles were conducted only at the inspiration phase at rest; thus, the degree of TrA, IO, and EO muscle thicknesses change during the expiration phase of respiration could not be identified in this study. Second, this study recruited only 20 subjects, so reliability studies with a large sample group need to be conducted. Third, this study was conducted in healthy young adults without LBP; further research is needed to assess the generalizability of these findings to those with more chronic LBP and geriatric populations. Fourth, the inter-rater reliability assessed in this study was conducted within a day. The influence of larger time intervals on reliability needs to be assessed. Finally, reliability in the three muscle thicknesses was good to excellent when we used the TA-PL1, and the reliability of IO for all measurement conditions was excellent; further study is needed to obtain the validity of the thickness measurements of the TrA, IO, and EO muscles using a gold standard.

Conclusion

In conclusion, moderate to excellent reliability was shown for all conditions (probe locations and measurement techniques) in TrA, IO, and EO muscles, (ICC=.70~.97). In the PL1-TA condition, reliability in the three muscle thicknesses was good to excellent (ICC=.85~.96). The reliability of all measurement conditions was excellent in IO (ICC=.95~.97). Thus, the results of the present study indicate that the PL1-TA can be used to measure abdominal muscle thickness in order to aid in clinicians and researchers' clinical decisions in diagnosis and research.

References

- Costa LO, Maher CG, Latimer J, et al. Reproducibility of rehabilitative ultrasound imaging for the measurement of abdominal muscle activity: A systematic review. *Phys Ther.* 2009;89(8):756-769.
- Critchley DJ, Coutts FJ. Abdominal muscle function in chronic low back pain patients: Measurement with real-time ultrasound scanning. *Physiotherapy.* 2002;88(6):322-332.
- Ferreira PH, Ferreira ML, Hodges PW. Changes in recruitment of the abdominal muscles in people with low back pain: Ultrasound measurement of muscle activity. *Spine (Phila Pa 1976).* 2004;29(22):2560-2566.
- Ferreira ML, Ferreira PH, Latimer J, et al. Comparison of general exercise, motor control exercise and spinal manipulative therapy for chronic low back pain: A randomized trial. *Pain.* 2007;131(1-2):31-37.
- Henry SM, Westervelt KC. The use of real-time ultrasound feedback in teaching abdominal hollowing exercises to healthy subjects. *J Orthop Sports Phys Ther.* 2005;35(6):338-345.
- Hides JA, Jull GA, Richardson CA. Long-term effects of specific stabilizing exercises for first-episode low back pain. *Spine (Phila Pa 1976).* 2001;26(11):E243-E248.
- Hodges PW, Moseley GL. Pain and motor control of the lumbopelvic region: Effect and possible mechanisms. *J Electromyogr Kinesiol.* 2003;13(4):361-370.
- Kiesel KB, Uhl TL, Underwood FB, et al. Measurement of lumbar multifidus muscle contraction with rehabilitative ultrasound imaging. *Man Ther.* 2007;12(2):161-166.
- Koppenhaver SL, Hebert JJ, Parent EC, et al. Rehabilitative ultrasound imaging is a valid measure of trunk muscle size and activation during most isometric sub-maximal contractions: A systematic review. *Aust J Physiother.* 2009;55(3):153-169.
- Krag MH, Byrne KB, Haugh LD, et al. Objective determination of trunk muscle dimensions using ultrasound. *IEEE Eng Med Biol Mag.* 1987;6(3):27-30.
- McGill SM, Jucker D, Axler C. Correcting trunk muscle geometry obtained from MRI and CT scans of supine postures for use in standing postures. *J Biomech.* 1996;29(5):643-646.
- Portney LG, Watkins MP. *Foundations of Clinical Research: Applications to practice.* 3rd ed. Upper Saddle River, NJ, Prentice Hall Inc., 2009.
- Rankin G, Stokes M, Newham DJ. Abdominal muscle size and symmetry in normal subjects. *Muscle Nerve.* 2006;34(3):320-326.
- Springer BA, Mielcarek BJ, Nesfield TK, et al. Relationships among lateral abdominal muscles, gender, body mass index, and hand dominance. *J Orthop Sports Phys Ther.* 2006;36(5):289-297.
- Stokes M, Rankin G, Newham DJ. Ultrasound imaging of lumbar multifidus muscle: Normal reference ranges for measurements and practical guidance on the technique. *Man Ther.* 2005;10(2):116-126.
- Teyhen DS. Rehabilitative ultrasound imaging symposium San Antonio, TX, May 8-10, 2006. *J Orthop Sports Phys Ther.* 2006;36(8):A1-3.
- Teyhen DS. Rehabilitative ultrasound imaging: The roadmap ahead. *J Orthop Sports Phys Ther.* 2007;37(8):431-433.
- Teyhen DS. Rehabilitative ultrasound imaging for assessment and treatment of musculoskeletal

conditions. *Man Ther.* 2011;16(1):44-45.
Teyhen DS, Gill NW, Whittaker JL, et al. Rehabilitative ultrasound imaging of the abdominal muscles. *J Orthop Sports Phys Ther.* 2007;37(8):450-466.
Teyhen DS, George SZ, Dugan JL, et al. Inter-rater reliability of ultrasound imaging of the trunk musculature among novice raters. *J Ultrasound Med.* 2011;30(3):347-356.

Whittaker JL, Teyhen DS, Elliott JM, et al. Rehabilitative ultrasound imaging: Understanding the technology and its applications. *J Orthop Sports Phys Ther.* 2007;37(8):434-449.

This article was received September 26, 2011, was reviewed October 6, 2011, and was accepted October 28, 2011.