

Arterial Switch Operation in Patients with Intramural Coronary Artery: Early and Mid-term Results

Hyungtae Kim, M.D.*, Si Chan Sung, M.D.**, Si-Ho Kim, M.D.**, Yun Hee Chang, M.D.***, Hyo Yeong Ahn, M.D.**, Hyoung Doo Lee, M.D.****

Background: The intramural coronary artery has been known as a risk factor for early death after an arterial switch operation (ASO). We reviewed the morphological characteristics and evaluated the early and mid-term results of ASO for patients with an intramural coronary artery. **Materials and Methods:** From March 1994 to September 15th 2010, 158 patients underwent ASO at Dong-A and Pusan National University Hospitals for repair of transposition of the great arteries and double outlet right ventricle. Among these patients, 14 patients (8.9%) had an intramural coronary artery. Mean age at operation was 13.4 ± 10.2 days (4 to 39 days) and mean body weight was 3.48 ± 0.33 kg (2.88 to 3.88 kg). All patients except one were male. Eight patients had TGA/IVS and 4 patients had an aortic arch anomaly. Two patients (14.3%) had side-by-side great artery relation, of whom one had an intramural right coronary artery and the other had an intramural left anterior descending coronary artery. Twelve patients had anterior-posterior relation, all of whom had an intramural left coronary artery (LCA). The aortocoronary flap technique was used in coronary transfer in 8 patients, of whom one patient required a switch to the individual coronary button technique 2 days after operation because of myocardial ischemia. An individual coronary button implantation technique was adopted in 6, of whom 2 patients required left subclavian artery free graft to LCA during the same operation due to LCA injury during coronary button mobilization and LCA torsion. **Results:** There was 1 operative death (7.1%), which occurred in the first patient in our series. This patient underwent an aortocoronary flap procedure for coronary transfer combining aortic arch repair. Overall operative mortality for 144 patients without an intramural coronary artery was 13.2% (19/144). There was no statistical difference in operative mortality between the patients with and without an intramural coronary artery ($p > 0.1$). There was no late death. The mean follow-up duration was 52.1 ± 43.0 months (0.5 to 132 months). One patient who had a subclavian artery free graft required LCA stenting 6.5 years after surgery for LCA anastomotic site stenosis. No other surviving patient needed any intervention for coronary problems. All patients had normal ventricular function at latest echocardiography and were in NYHA class 1. **Conclusion:** The arterial switch operation in Transposition of Great Arteries or Double Outlet Right Ventricle patients with intramural coronary can be performed with low mortality; however, there is a high incidence of intraoperative or postoperative coronary problems, which can be managed with conversion to the individual coronary button technique and a bypass procedure using a left subclavian free graft. Both aortocoronary flap and individual coronary button implantation techniques for coronary transfer have excellent mid-term results.

*Department of Thoracic and Cardiovascular Surgery, Ajou University Hospital

**Department of Thoracic and Cardiovascular Surgery, School of Medicine, Pusan National University

***Department of Thoracic and Cardiovascular Surgery, St. Mary's Hospital, The Catholic University of Korea, School of Medicine

****Department of Pediatrics, School of Medicine, Pusan National University

†This work was supported for two years by Pusan National University Research Grant.

Received: September 25, 2010, Revised: November 11, 2010, Accepted: November 12, 2010

Corresponding author: Si Chan Sung, Department of Thoracic and Cardiovascular Surgery, School of Medicine, Pusan National University, Beomeo-ri, Mulgeum-eup, Yangsan 626-770, Korea
(Tel) 82-55-360-2560 (Fax) 82-55-360-2157 (E-mail) scsung21@hanmail.net

© The Korean Society for Thoracic and Cardiovascular Surgery. 2011. All right reserved.

© This is an open access article distributed under the terms of the Creative Commons Attribution Non-Commercial License (<http://creativecommons.org/licenses/by-nc/3.0>) which permits unrestricted non-commercial use, distribution, and reproduction in any medium, provided the original work is properly cited.

Key words: 1. Congenital heart disease
2. Transposition of the great arteries
3. Arterial switch operation
4. Coronary artery
5. Coronary artery anatomy

INTRODUCTION

An arterial switch operation (ASO) is becoming a standard treatment for transposition of the great arteries (TGA) and some cases of a double outlet right ventricle (DORV) due to good long term results and a low mortality rate. The most important element for successful ASO is accurate coronary artery implantations. However, the origin or course of an unusual coronary artery can make it difficult to perform ASO and can produce poor surgical results in some cases. Among the unusual coronary arteries, the intramural coronary artery is well known for being difficult to transplant and a risk factor for postoperative coronary artery complications [1-4]. In this study, we analyzed the incidence of the intramural coronary artery, its morphological characteristics, operative techniques, and postoperative early and mid-term results.

MATERIALS AND METHODS

Among the 158 patients who had undergone ASO at our-hospital between March of 1994 and September 15, 2010, we retrospectively reviewed the medical records of the 14 patients (8.9%) with intramural coronary artery. The mean age was 13.4 ± 10.2 days (4 to 39 days), and the mean body weight was 3.48 ± 0.33 kg (2.88 to 3.88 kg). All patients but one were male. Eight patients (57.1%) had TGA with an intact ventricular septum, three patients (21.4%) had TGA with ventricular septal defect (VSD), and three patients had a Taussig-Bing anomaly. Among the latter patients, 4 patients (28.6%) had aortic arch anomaly simultaneously. Preoperative mechanical ventilation was performed in 4 patients (28.6%), Prostaglandin E1 was infused in 12 patients (85.7%), and balloon atrioseptostomy was performed in 6 patients (42.9%) (Table 1). 12 patients (85.7%) had an anterior-posterior great

arterial relation, and all of them had interamural left coronary arteries. Two patients (14.3%) showed a side-by-side arterial relation. One of them had an intramural right coronary artery and the other, an intramural left anterior descending coronary artery (Fig. 1). There was no case of definite diagnosis of intramural coronary artery preoperatively, the diagnosis was confirmed in an operating room. The aortocoronary flap technique was applied to 8 patients and the individual coronary button technique to 6 patients. There were no special indications for the aortocoronary flap technique or individual coronary button technique. The aortocoronary flap technique tended to be applied more frequently in the earlier cases of ASO, while the individual coronary button technique was used more often in the recent ASO procedures. In all cases, we performed the aortocoronary flap technique or individual coronary button technique after detaching the facing aortic commissure from the posterior aortic wall and two or three coronary arteries as one button from the aorta. In the cases of the aortocoronary flap technique, we anastomosed the coronary artery flap to the main pulmonary artery at the same level as the coronary artery flap after removing a rectangular portion of the incised main pulmonary artery adjacent to the coronary artery flap as wide as the coronary artery flap. After that, we fully covered the coronary artery flap with autologous pericardium and attached the coronary artery flap to the distal aorta, which allowed blood to run from the aorta to the coronary artery flap (Fig. 2).

In order to cover the coronary artery flap, we used fresh autologous pericardium in 5 cases, autologous pericardium fixed with Glutaldehyde in 2 cases, and bovine pericardium in the one earliest case. In the cases of the aortocoronary flap technique, we did not unroof the anterior wall of the intramural coronary artery at all. In the cases of the individual coronary artery button technique, after dissecting some of the

Table 1. Patient profiles

Age (days)	13.4±10.2 (4~39)
Sex (M:F)	13:1
Weight (kg)	3.48±0.33 (2.88~3.88)
Diagnosis	
TGA with IVS	8 (57%)
TGA with VSD	3 (21%)
Taussig-Bing anomaly	3 (21%)
Aortic arch anomaly	4 (29%)
Preoperative ventilator	4 (29%)
Preoperative PGE1 infusion	12 (86%)
Preoperative atrial septostomy	6 (43%)

TGA=Transposition of the great arteries; IVS=Intact ventricular septum; VSD=Ventricular septal defect; PGE1=Prostaglandin E1.

facing commissure from the aortic wall, we fully unroofed the anterior wall of the intramural coronary arteries and then divided them into one button from the aorta. After that, we divided this button into two and performed the reconstruction of a neo-aorta following the Lecompte maneuver. Relieving an aortic clamp could inflate the neo-aorta. Therefore, we could identify and mark the site for the two coronary buttons and transfer them (Fig. 3).

Postoperative management was done in the same way as normal ASO, and we performed delayed sternal closures in 11 of 13 patients who had survived after their operations. The mean cardiopulmonary bypass time was 256.9±45.0 minutes (157 to 319 minutes) and aortic cross clamp time was 154.4±39.7 minutes (82 to 209 minutes). Mean postoperative mechanical ventilation time was 162.7±120.5 hours (40 to 408 hours), and mean postoperative hospitalization time was 18.7±7.6 days (12 to 34 days). All mean values are presented as mean±SD and the difference of frequency was analyzed with the Chi-square test using MedCalc version 7.0 (MedCalc Software bvba, Belgium) program. We regarded a p-value less than 0.05 as statistically significant.

RESULTS

There was one operative death (7.1%). The case was the first patient in this series who had undergone the aortocoronary flap technique with the correction of the aortic arch anomaly. The operative mortality of the 144 patients who did not have an intramural coronary artery was 13.2% (19 of

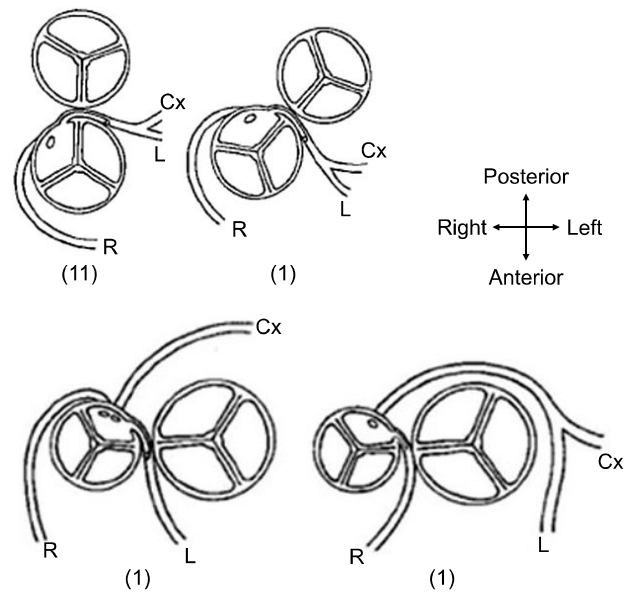


Fig. 1. Great artery relation and coronary artery patterns. ()= Number of patients.

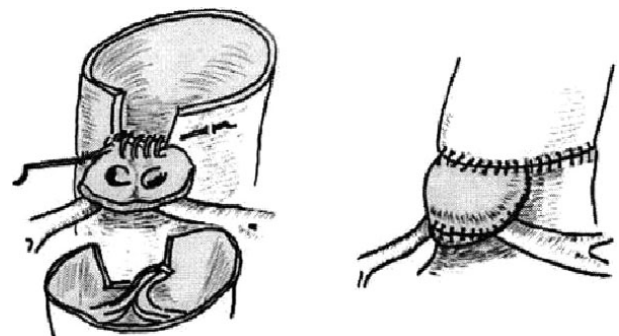


Fig. 2. Aortocoronary flap technique.

144), and there was no significant statistical difference ($p > 0.1$). One of 8 patients who had undergone the operation with the aortocoronary flap technique had a coronary artery re-implantation using the individual coronary button technique due to myocardial ischemia on postoperative day 2. There were 2 failures of the left coronary artery transfer among the 6 patients undergoing the individual coronary button technique. There was one intramural left coronary artery injury while dividing the coronary artery button from the aorta, so a coronary bypass graft was done by using a left subclavian artery free graft to the left main coronary artery. The other patient suffered from left ventricular ischemia after the individual coronary button technique, so a coronary bypass

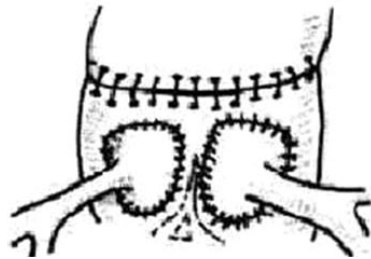


Fig. 3. Individual coronary button technique.

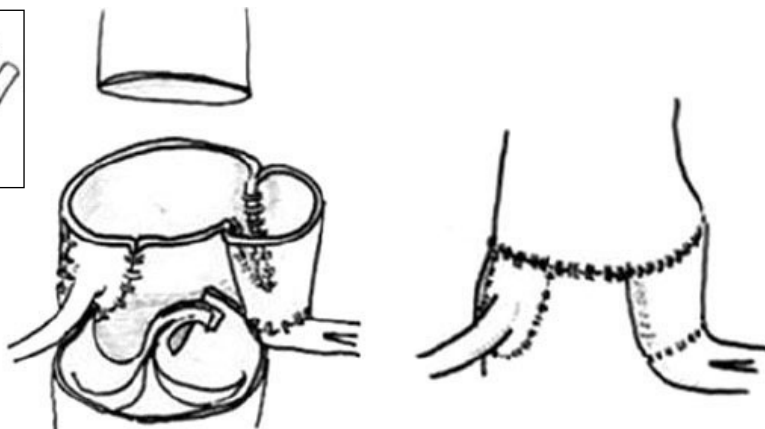
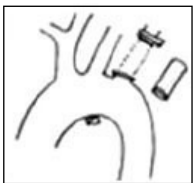


Fig. 4. Coronary artery bypass using a left subclavian artery free graft.

graft was performed using a left subclavian artery free graft to the left main coronary artery (Fig. 4). For these reasons, there were three failures of planned coronary artery transfer among the total of 14 patients, and other surgical techniques were needed. The mean follow-up period was 52.1 ± 43.0 months (0.5 to 132 months), and there was no long term death during the period. The patient who had undergone coronary artery bypass grafting using a left subclavian artery free graft had a stent graft insertion in the left coronary artery due to the stenosis of the anastomotic site 6.5 years later; now the patient is maintaining good ventricular function without any problems. There was no invasive treatment or re-operation by complications of the coronary artery in the re-

maining survivors. All the surviving patients showed normal ventricular function in their last echocardiography, and they are now in the state of NYHA class 1. Four patients had postoperative cardiac catheterizations, in one case by the aortocoronary flap technique at postoperative 18 months, in 2 cases by a left subclavian artery free graft at postoperative 21 months and 78 months, and in one case by the individual coronary button implantation technique at postoperative 22 months. In one case in which a left subclavian artery free graft was performed, left main coronary artery stenosis was identified, so a stent graft insertion was performed. The remaining three patients had no stenosis of the coronary artery (Fig. 5). Recently, multislice CT scans (SOMATOM defi-

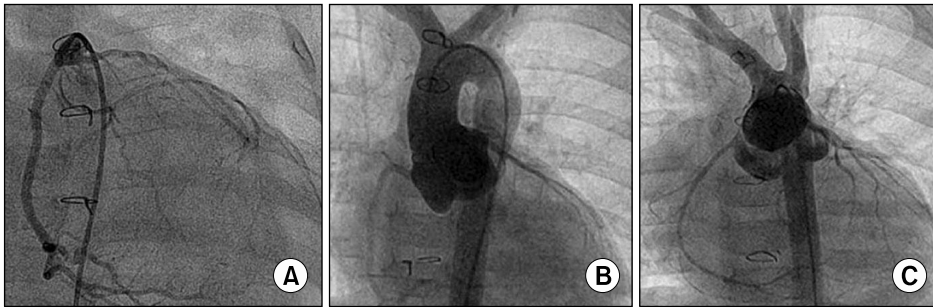


Fig. 5. Postoperative coronary angiography. (A) 18 months after an aortocoronary flap, (B) 21 months after a left subclavian free graft bypass, (C) 22 months after the double button technique.

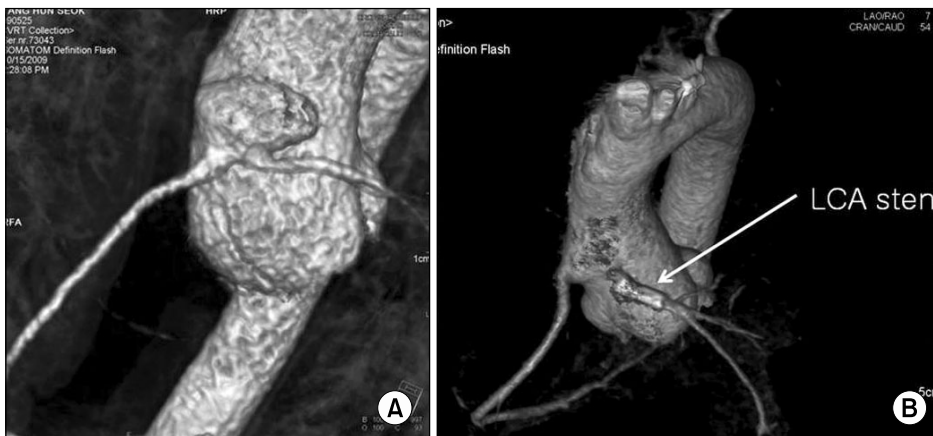

Fig. 6. Postoperative multislice CT scan. (A) 10.4 years after the aortocoronary flap procedure, (B) 11.4 years after a left subclavian artery free graft bypass and 4.9 years after left coronary artery stenting.

nition flash, Siemens) were performed in the 4 patients. One patient who had undergone a coronary artery bypass graft using the left subclavian artery free graft and a stent insertion 6.5 years later underwent a CT scan at postoperative 11.4 years and the remaining three patients who had undergone the aortocoronary flap technique had scans at postoperative 10.4 years, 5.6 years, and 2.6 years. None of the CT scans showed any stenosis of the coronary artery (Fig. 6). Therefore, we could observe the postoperative state of the coronary arteries in 7 of the 14 patients by cardiac catheterizations or multislice CT scans, and there was no coronary artery stenosis except in one patient who had undergone a coronary artery bypass graft using the left subclavian artery free graft.

DISCUSSION

An intramural coronary artery is a case in which some of the coronary artery is inside the aortic wall, that is, a form of the coronary artery in which its media is attached to the aorta

without separation from the adventitia. An intramural coronary artery is very rare in a normal ventricular – great vessel relation; however, a frequency of 3 to 7% in TGA has been reported [2,4-6]. In our series, 14 intramural coronary arteries were identified among 158 TGA patients (8.9%), which showed a little higher incidence. Metton et al. [2] reported that 46 of 919 patients who had undergone ASOs (5%) had an intramural coronary artery, and the ratio of males to females was 35 to 11, which demonstrated predilection of TGA toward males. On the other hand, in our series, the ratio of male to female among all cases of ASO was 23 to 8, or about 75% male; all but one patient were male; that is, there was a strong predilection of intramural coronary artery toward males.

Intramural coronary artery can appear in the right coronary artery or the left coronary artery, but it usually appears in the left main coronary artery or the left anterior descending coronary artery. Among our cases, the majority of cases were in the left main coronary artery and each case was detected in the left anterior descending coronary artery and the right cor-

onary artery respectively. In terms of the great arteries' relation and the morphology of the intramural coronary artery, most intramural coronary arteries can be detected between the great arteries. In our series, 12 patients of 14 who had an intramural coronary artery had an anterior-posterior great arterial relation and the left coronary artery came from sinus 2 and ran between the great arteries in all of them. The remaining 2 patients had a side-by-side great arterial relation. In one of them, the right coronary artery came from sinus 2 and ran between the great arteries, while the left anterior descending artery came from sinus 2 and ran between the great arteries in the other case. Moreover, all the cases had a right and left coronary artery ostia which came from the coronary sinus 2 (Fig. 1) Asou et al. [5] reported 5 types of intramural coronary artery in 12 cases, which were more varied than ours. They reported as many as 5 forms of the left main coronary artery from sinus 2 and 4 forms of the left anterior descending coronary artery from sinus 2. Six of 9 patients had stenosis in the left main coronary artery or the left main coronary artery. Two other patients had intramural coronary arteries originating not from the wrong aortic sinus but from the normal aortic sinus, but they originated from a site a bit higher than usual and ran intramurally. The remaining patient had intramural left and right coronary arteries with only one ostium in the facing commissure superiorly. However, in our series, all of the intramural coronary arteries originated from the wrong aortic sinus and had a separate coronary ostium. Metton et al. [2] reported that among 46 cases, there were intramural main coronary arteries in 61%, intramural left anterior descending arteries in 26%, intramural right coronary arteries in 6.5% and intramural left and right coronary arteries in 6.5%.

In cases in which the intramural left main coronary artery or intramural left anterior descending coronary artery originated from between the great arteries, during the dissection of the coronary artery from the aorta, inexperienced surgeons can damage the left main or anterior descending coronary artery, which looks like a normal coronary artery from sinus 1. For that reason, Metton et al. [2] noted that in case of transverse aortotomy, a safe region should first be incised partially and the rest of aortotomy should then be performed after the identification of the coronary arteries. Asou et al. [5] strongly

suspected the existence of an intramural coronary artery in cases where there was no outward typical ostial bulging. The authors believe that if the left coronary artery does not originate from the aortic sinus bulging outwardly, there is a possibility of an intramural coronary artery. Furthermore, if after a transverse aortomy, there isn't a left coronary artery ostium in sinus 1, we strongly suspect an intramural left coronary artery, and we also consider the possibility of a small hiding left coronary artery ostium immediately right to the facing commissure. These are important factors that unexperienced surgeons must keep in mind. In fact, the authors experienced many difficulties with the coronary artery transfer of intramural coronary arteries during the earlier cases of ASO. In the first case of our series, we caused damage to the left coronary artery during division of the coronary artery from the aortic wall, and thus repaired the damage and performed a coronary artery bypass graft using an aortocoronary flap technique. Nonetheless, the patient died. In the other one case, we caused an injury to the left main coronary artery, but overcame the difficult situation by performing a coronary artery bypass graft using a left subclavian artery free graft.

We found we could not safely detach a coronary artery from the aortic sinus without removal of some portion of the facing commissure because intramural coronary arteries usually originate from the wrong aortic sinus and they are located very close to the facing commissure. Furthermore, the originating part is very closely located to the other coronary artery (the right coronary artery), not to the intramural coronary artery, dividing these two originating sites is not an easy task, and the possibility of stenosis or torsion after anastomosis to the neo-aorta is higher because an undue division without unroofing the aortic wall of the intramural coronary artery can result in a lack of sufficient tissue for anastomosis. Owing to these anatomical characteristics, a coronary artery transfer can be difficult, and its postoperative course can be poor. In order to overcome these problems, several coronary artery implantation methods have been introduced. First, the aortocoronary flap technique is a method of dividing the left and right coronary arteries as one button from the aortic wall, to anastomose the upper edge of the button to the incised main pulmonary artery, and to keep the coronary blood flow from going through a neo-aorta by covering this flap with au-

tologous pericardial tissue or the pulmonary arterial wall. Sometimes, the reconstruction of a neo-aorta can be performed first and then, the transverse neo-aortomy at the same level as the upper border of the coronary artery flap and some tissue removal of the neo-aorta can be performed before anastomosing the upper edge of the flap to the neo-aorta and covering the flap with autologous pericardial tissues [7]. The aortocoronary flap technique is easy to perform and to minimize the torsion of the coronary artery due to the minimum geometric changes of the left and right coronary arteries. However, the coronary artery ostium can be compressed by a neopulmonary artery and in the long term, there is the possibility of coronary arterial stenosis when the covering tissues do not grow or shrink. Actually, Asou et al. [5] used this method in the beginning of the intramural coronary artery transfer process and Metton et al. [2] reported that they used this method when the left and right coronary arteries were located too closely to divide them; however, this method caused coronary events more often than the individual coronary button technique. In our experiences, the aortocoronary flap technique has been used since ASO was first introduced without big problems; however, we have drastically used the individual coronary button technique since the one case of conversion to the individual coronary button technique due to myocardial ischemia on the second postoperative day after aortocoronary flap technique (since January, 2009). When the two coronary arteries originate from the same sinus, dividing the coronary arteries with too short an intramural course or something other than an actual intramural coronary artery into an individual coronary button can be dangerous, so we usually use the aortocoronary flap technique. The second method for intramural coronary transfer is the individual coronary button technique. We divide two individual coronary arteries each into button and detach them, then transfer the coronary arteries using the technique of usual ASO. We would like to emphasize the two important surgical techniques in this method. One is that at the time of division of the two coronary arteries from the aortic sinus, we must obtain enough sinus 1 tissue near the left commissure and sufficiently unroof the aortic wall of the intramural coronary artery after partial detachment of the facing commissure from the aortic wall. This is in order to obtain enough of the aortic cuff of both

coronary arteries at the time of dividing the aortic sinus into two coronary buttons. Furthermore, it is also important to identify the extent of unroofing the aortic wall by inserting a coronary probe into the intramural portion of a coronary artery. The other important technique in this method is that for coronary transfer to a neo-aorta, at first, the reconstruction of a neo-aorta has to be performed, then, inflating the neo-aorta by declamping the aorta and choosing the right location and direction for the left and right coronary transfer should be carried out. This method is for coronary button transfer to an adequate location. The authors were able to overcome a myocardial ischemia, which had occurred after using the individual coronary button technique early in our experience, by performing a bypass between the aorta and the left main coronary artery using a left subclavian artery free graft. Besides, the technique of keeping perfusion from a neo-aorta to the coronary arteries using the aortic wall or other grafts without coronary transfer has been reported [8,9]; however, this is not usually done.

The surgical results of TGA with an intramural coronary artery are very different among institutions. According to a paper which was presented from Royal Children's Hospital in Australia in 1994 by Asou et al. [5], 12 of 259 patients who underwent ASO had an intramural coronary artery and there was no operative or long term postoperative death. According to the report which Blume et al. from the Boston Children Hospital in 1999 [10], there were 4 intramural coronary arteries of a total of 223 patients, and one of them died. There were 12 intramural coronary arteries of 168 patients and no death, according to the relatively recent results of ASO reported by Qamar et al. from C.S. Mott Children's Hospital in 2007. On the other hand, the results of ASO which performed at Green Lane Hospital in New Zealand until 1999 noted 11 intramural coronary arteries of 244 patients and 4 postoperative deaths [4]. According to the results presented by Metton et al. [2] from Hospital for Sick Children of the University of Paris Descartes, there were 46 patients with intramural coronary arteries of 919 who underwent ASO, and 13 patients died, which corresponded to a 28% of mortality rate. This mortality rate was very high, when compared with that (3.9%) of the patients without intramural coronary artery in the same period. They reported that there had been no

change in the mortality rate, even in recent years.

There are few published long term results of ASO in patients with intramural coronary arteries. According to the long term results of ASO from Green Lane Hospital, there was no late mortality after ASO in patients with intramural coronary arteries [4]. However, Metton et al. reported that two patients died at postoperative day 51 and day 105, and 8 patients of 33 survivors had intramural coronary arteries, and furthermore, 5 of them had reoperations due to an intramural coronary artery. They reported that the actuarial freedom from a coronary event of these patients for ten years would be 46%. Sachweh et al. [11] reported that they found an intramural coronary artery in 5 patients (1.4%) of 351 who underwent ASO, and they transferred the intramural coronary artery as one button without unroofing the aortic wall. They also reported that, though there were neither operative mortality nor myocardial ischemia, intramural coronary artery obstructions were identified by coronary angiograms that were performed at postoperative 5, 16, and 53 months later, and 2 of the patients had operations for a coronary artery bypass graft using an internal mammary artery.

In this series, the mortality rate of ASO in patients with an intramural coronary artery was lower than that of the other patients undergoing ASO, but the difference was statistically insignificant. There was no late mortality. We observed the postoperative coronary state with a coronary angiography or CT scan in 7 of the 14 total patients, and one patient needed an invasive coronary artery intervention. Even the patients without symptoms could have a coronary abnormality, so we think close follow-up is needed for these patients.

CONCLUSION

In TGA with an intramural coronary artery, ASO could be performed with a low mortality rate. However, myocardial ischemia related to the coronary artery transfer occurred during the operative or postoperative period with a high incidence.

This problem could be managed by the conversion to the individual coronary button implantation technique and a coronary artery bypass graft using a subclavian artery free graft. Both an aortocoronary flap and the individual coronary button implantation technique for coronary transfer have excellent mid-term results.

REFERENCES

1. Day RW, Laks H, Drinkwater DC. *The influence of coronary anatomy on the arterial switch operation in neonates.* J Thorac Cardiovasc Surg 1992;104:706-12.
2. Metton O, Calvaruso D, Gaudin R, et al. *Intramural coronary arteries and outcome of neonatal arterial switch operation.* Eur J Cardiothorac Surg 2010;37:1246-53.
3. Pretre R, Tamisier D, Bonhoeffer P, et al. *Results of the arterial switch operation in neonates with transposed great arteries.* Lancet 2001;357:1826-30.
4. Wong SH, Finucane K, Kerr AR, O'Donnell C, West T, Gentles TL. *Cardiac outcome up to 15 years after the arterial switch operation.* Heart Lung Circ 2008;17:48-53.
5. Asou T, Karl TR, Pawade A, Mee RB. *Arterial switch: translocation of the intramural coronary artery.* Ann Thorac Surg 1994;57:461-5.
6. Qamar ZA, Goldberg CS, Devaney EJ, Bove EL, Ohye RG. *Current risk factors and outcomes for the arterial switch operation.* Ann Thorac Surg 2007;84:871-8; discussion 8-9.
7. Cetin G, Tireli E, Ozkara A, et al. *Arterial switch operations for single coronary artery ostium or intramural coronary artery.* Circ J 2004;68:1179-83.
8. Moat NE, Pawade A, Lamb RK. *Complex coronary arterial anatomy in transposition of the great arteries. Arterial switch procedure without coronary relocation.* J Thorac Cardiovasc Surg 1992;103:872-6.
9. Murthy KS, Cherian KM. *A new technique of arterial switch operation with in situ coronary reallocation for transposition of great arteries.* J Thorac Cardiovasc Surg 1996;112:27-32.
10. Blume ED, Altmann K, Mayer JE, Colan SD, Gauvreau K, Geva T. *Evolution of risk factors influencing early mortality of the arterial switch operation.* J Am Coll Cardiol 1999;33:1702-9.
11. Sachweh JS, Tiete AR, Jockenhoevel S, et al. *Fate of intramural coronary arteries after arterial switch operation.* Thorac Cardiovasc Surg 2002;50:40-4.