

Carinal Reconstruction and Sleeve Right Upper Lobectomy Assisted with Extracorporeal Membrane Oxygenator for Non-small Cell Lung Cancer

— A case report —

Hee Sung Lee, M.D.*, Hyoung-Soo Kim, M.D.**, Ho-Seung Shin, M.D.***,
Sung Jun Kim, M.D.****, Sung-Woo Cho, M.D.*****, Kun-Il Kim, M.D.*****

Bronchogenic carcinoma involving the carina has remained a challenging problem for thoracic surgeons. Carinal resection and reconstruction is limitedly indicated because this aggressive surgical approach has been reported to be associated with significant morbidity and mortality while long-term outcome has not been determined. We successfully performed carinal reconstruction and sleeve right upper lobectomy assisted with ECMO for a 60-year-old male with squamous cell carcinoma in the right upper lobe extending to the carina.

Key words: 1. Carcinoma, non-small cell, lung
2. Surgery, tracheobronchial
3. Extracorporeal membrane oxygenation

CASE REPORT

A sixty-year-old male patient was admitted with cough and blood-tinged sputum which started 3 months prior to admission. He had past histories of gastric lymphoma 20 years ago, which was completely cured after 11 months of chemotherapy, and lung abscess in the left upper lobe 3 years before. He had been a 30 pack-year smoker, and quit cigarette smoking after the development of lung abscess. Chest computed tomography showed 2.3 cm sized lung mass originating from the right upper lobe (Fig. 1A), and bronchoscopic examination revealed that endobronchial lesion was ex-

tending into the carina (Fig. 1C, D). Tissue diagnosis (squamous cell carcinoma) was made from the biopsy specimen, which was obtained upon bronchoscopy. Positron emission tomography showed FDG uptake in the right main bronchus and the carina while there was no increased FDG uptake in the mediastinal lymph nodes (Fig. 1B).

Under general anesthesia with a single lumen endotracheal tube, mediastinoscopic lymph node biopsy was performed. After confirming that there was no metastasis to the right and left lower para-tracheal lymph nodes (R4, L4) and the subcarinal node (7), the patient was re-positioned to be prepared for posterolateral thoracotomy incision and inguinal dissec-

*Department of Thoracic and Cardiovascular Surgery, Kangnam Sacred Heart Hospital

**Department of Thoracic and Cardiovascular Surgery, Chuncheon Sacred Heart Hospital

***Department of Thoracic and Cardiovascular Surgery, Hangeang Sacred Heart Hospital

****Department of Thoracic and Cardiovascular Surgery, Hallym University Sacred Heart Hospital

*****Department of Thoracic and Cardiovascular Surgery, Kangdong Sacred Heart Hospital

Received: August 23, 2010, Revised: November 15, 2010, Accepted: March 21, 2011

Corresponding author: Hyoung-Soo Kim, Department of Thoracic and Cardiovascular Surgery, Chuncheon Sacred Heart Hospital, 153, Gyo-dong, Chuncheon 200-704, Korea

(Tel) 82-33-240-5000 (Fax) 82-33-255-6244 (E-mail) cskhs99@hallym.ac.kr

© The Korean Society for Thoracic and Cardiovascular Surgery. 2011. All right reserved.

© This is an open access article distributed under the terms of the Creative Commons Attribution Non-Commercial License (<http://creativecommons.org/licenses/by-nc/3.0>) which permits unrestricted non-commercial use, distribution, and reproduction in any medium, provided the original work is properly cited.

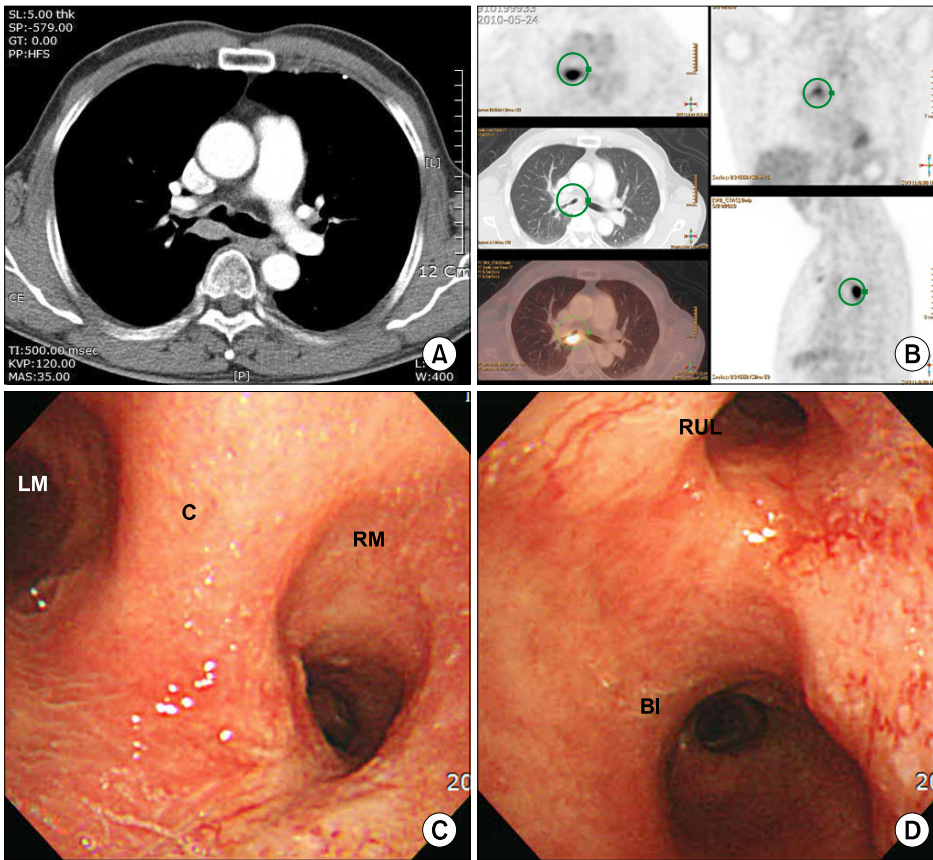


Fig. 1. Preoperative chest CT and PET-CT show about 2.5 cm mass on right main bronchus involving carina (A, B). Preoperative bronchoscopic findings show endobronchial lesion on the orifice of right upper lobe involving carina (C, D). C=Carina; LM=Left main bronchus; RM=Right main bronchus; BI=Bronchus intermedius; RUL=Right upper lobe.

tion. Vertical incision was made in the left inguinal area, and femoral artery and vein were dissected (Fig. 2A). Once heparin (3,000 unit) was administered, 17 French arterial cannula (DLP[®], Medtronic Inc., MN, USA) and 21 French venous cannula (DLP[®], Medtronic Inc., MN, USA) were introduced into the corresponding vessels, and veno-arterial extracorporeal oxygenation (ECMO) was commenced with a flow rate of 3.5 liter/minute using a centrifugal pump (Roatflow pump[®], Maquet Inc, Hirrlingen, Germany). With the cessation of the artificial ventilation, systemic blood pressure, peripheral oxygen saturation, and activated coagulation time (ACT) were maintained at 90 mmHg, 100%, and 140~160 seconds, respectively. Through right posterolateral thoracotomy and 5th intercostals space, loose pleural adhesion was dissected and the right inferior pulmonary ligament was divided. The right upper pulmonary artery and vein was dissected and divided using an autosuture device and Hemoloc clip. On palpation, lung mass was identified in the right main bronchus. After bronchus intermedius was divided at the level

distal to the origin of right upper lobar bronchus, wedge resection of the distal trachea and proximal left main bronchus was performed. Because tracheal resection margin was tumor positive on frozen biopsy, trachea and left main bronchus was excised further by 1 cm. Distal end of the trachea and proximal end of the left main bronchus was approximated and partially anastomosed for carinal reconstruction, and this newly reconstructed carina was anastomosed in an end-to-end fashion to the previously divided bronchus intermedius (Fig. 2B). After air leakage test of the tracheobronchial suture lines, additional mediastinal lymph node dissection was performed. After meticulous hemostasis, the patient came off ECMO without any problem. He was extubated on postoperative day 1, and was transferred to the general ward on postoperative day 2. Bronchoscopic examination on postoperative day 7 showed no abnormal finding in the anastomotic site (Fig. 2C). Postoperative pathological staging was stage IIIb (T4NoMo). He was discharged home on postoperative day 8, and has been followed-up for 4 weeks with-

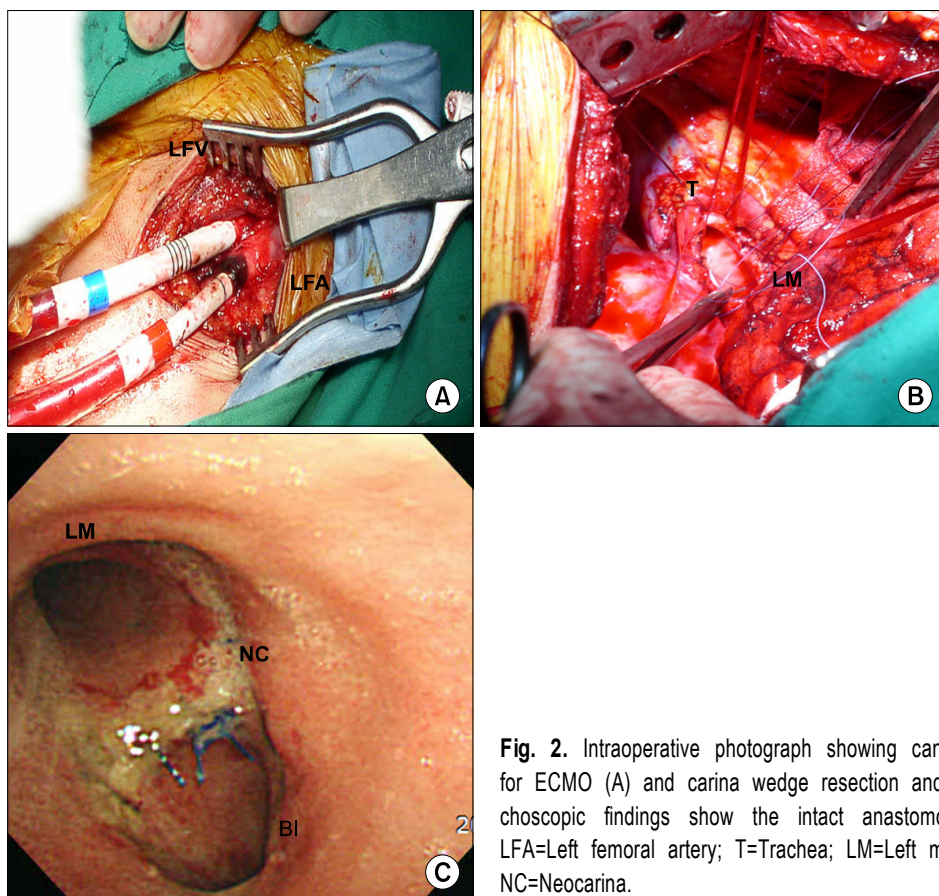


Fig. 2. Intraoperative photograph showing cannulation in left femoral vein and artery for ECMO (A) and carina wedge resection and reconstruction (B). Postoperative bronchoscopic findings show the intact anastomosis site (C). LFV=Left femoral vein; LFA=Left femoral artery; T=Trachea; LM=Left main bronchus; BI=Bronchus intermedius; NC=Neocarina.

out significant complications, receiving postoperative adjuvant radiotherapy.

DISCUSSION

Although carinal resection and reconstruction was first reported by Grillo almost 30 years ago in 1982 [1], non-small cell lung cancer involving carina has not been frequently indicated for surgical intervention because carinal reconstruction is reportedly associated with significant morbidity and mortality while long-term outcome has not been determined. As the number of surgeons and programs who got accustomed to sleeve resection of the lung has increased, however, the outcome of carinal resection and reconstruction has improved too [2,3]. Perrot et al and Mitchell et al reported relatively low surgical mortality (7.6% and 10.0%, respectively), which was almost comparable to that of ordinary lung resection [4,5].

Long-term outcome of carinal resection and reconstruction

depends mainly upon proper patient selection. Significant prognostic factors are known to be ventilator support time, the amount of resection of the trachea and contralateral bronchus, and anastomotic site air leak. To lower the incidence of tracheal anastomotic site complications, minimal dissection of the surrounding tissue as well as distal ends of the trachea and bronchi the key to successful repair. Furthermore, distal resection of the trachea should not exceed 4 cm so that minimal tension is imposed on the anastomotic site [6]. Mitchell et al. reported that the presence or absence of mediastinal lymph node involvement is a major determinant of the outcome [5]. They showed that five-year survival rate for N0 versus N2/N3 lesions were 51% and 12%, respectively. The most precise diagnostic tool for mediastinal lymph node metastasis is mediastinoscopic biopsy. In our case, mediastinoscopic lymph node biopsy showed no metastasis to both lower paratracheal and subcarinal lymph nodes. If the patient had had positive mediastinal lymph nodes, surgical inter-

vention might have been discouraged, or, at least, deferred, given very poor prognosis of the patients with positive N2 nodes.

When carinal resection and reconstruction are performed without cardiopulmonary bypass, jet ventilation or ventilation through the endotracheal tubes introduced into the divided bronchial ends could be used. These techniques, however, have several pitfalls, such as hindrance to appropriate surgical view, inpouring of blood into the airway, prolonged operation time due to repeated endobronchial intubation, and potential risk of bronchus luminal injury. In this case, ECMO was used to guarantee un-interfered surgical field, to shorten the surgery time, and to avoid bronchial injury. The use of ECMO, however, may increase the risk of postoperative bleeding and may lead to postoperative pulmonary edema. Use of heparin coated circuit with minimal heparinization may decrease the risk of postoperative bleeding [7,8].

REFERENCES

1. Grillo HC. *Carinal reconstruction*. Ann Thorac Surg 1982; 34:356-73.
2. Rovario GC, Varoli F, Rebuffat C, et al. *Tracheal sleeve pneumonectomy for bronchogenic carcinoma*. J Thorac Cardiovasc Surg 1994;107:13-8.
3. Jensik RJ, Faber LP, Kirtle CF, et al. *Survival in patients undergoing tracheal sleeve pneumonectomy for bronchogenic carcinoma*. J Thorac Cardiovasc Surg 1982;84:489-96.
4. de Perrot M, Fadel E, Mercier O, et al. *Long-term results after carinal resection for carcinoma: dose the benefit warrant the risk?* J Thorac Cardiovasc Surg 2006;131:81-9.
5. Mitchell JD, Mathisen DJ, Wright CD, et al. *Resection for bronchogenic carcinoma involving the carina: Long-term results and effect of nodal status on outcome*. J Thorac Cardiovasc Surg 2001;121:465-71.
6. Mitchell JD, Mathisen DJ, Wright CD, et al. *Clinical experience with carinal resection*. J Thorac Cardiovasc Surg 1999;117:39-53.
7. Kondo T, Sagawa M, Sato M, et al. *Left sleeve pneumonectomy performed through a clamshell incision with extracorporeal membrane oxygenation for bronchogenic carcinoma: report of two cases*. Surg Today 1999;29:807-10.
8. Maggart S, Stewart S. *The mechanism and management of noncardiogenic pulmonary edema following cardiopulmonary bypass*. Ann Thorac Surg 1987;43:231-6.