

Expansion of the mandibular arch using a trombone appliance

Fidan Alakus Sabuncuoglu, PhD,^a Şeniz Karaçay, PhD,^b Hüseyin Ölmez, PhD^c

Objective: This case report describes orthodontic treatment of contracted mandibular arch using a trombone appliance. **Methods:** A 14-year-old girl with Class II division 2 malocclusion, retroclined maxillary incisors, and buccally displaced maxillary canines required dental expansion in 3 spatial directions to correct the contracted maxillary and mandibular arches. In the initial phase of treatment, the maxillary arch was expanded and distalized using a quad-helix appliance and cervical headgear. Following the expansion and leveling of the maxillary arch, a trombone appliance was used to expand the mandibular arch. On correction of the mandibular arch and provision of sufficient space to level the mandibular teeth, fixed orthodontic treatment phase was initiated. **Results:** A trombone appliance proved effective in correcting the contracted mandibular arch. Because of labiolingual and transversal expansion, the mandibular dental arch perimeter was increased by 7.4 mm; the misalignment of the mandibular teeth was corrected successfully. **Conclusions:** A trombone appliance may serve as an appropriate clinical alternative for treating moderate mandibular arch crowding caused by the contraction of the dental arch. (*Korean J Orthod* 2011; 41(3):211-218)

Key words: Trombone appliance, Mandibular arch development, Mandibular dental expansion

INTRODUCTION

Mandibular arch crowding is a frequently observed phenomenon in patients with malocclusion, which occurs when the dental arch perimeter between the first permanent molars is insufficient in length to permit the alignment of erupting permanent teeth. The extent of crowding is a determining factor for whether to per-

form extractions during orthodontic treatments. The treatment plan for mandibular arch crowding must take into consideration whether the results can be stably maintained.

Researchers have differing views regarding tooth extraction. Angle¹ states that a full complement of teeth is essential for achieving ideal function and aesthetics, whereas Case² advises extraction for long-term stability in patients with discrepancies between tooth mass and basal bone. Over the last 2 decades, the number of patients treated without extraction of permanent teeth has increased.^{3,4} It is possible to gain the space required for leveling crowded teeth by early space preservation through conservation of leeway space,⁵ proximal tooth reduction by stripping, and rapid palatal expansion and lip bumper therapy.⁶

It is more difficult to induce change in the mandible than in the maxilla because of the compact structure of the lower jaw, which makes it more resistant to ortho-

^aErzurum Mareşal Çakmak Military Hospital Dental Center Orthodontics Department, Erzurum, Turkey.

^bAssociate Professor, GMMA Haydarpasha Education Hospital, Dental Service, İstanbul, Turkey.

^cAssociate Professor, Gulhane Military Medical Academy, Dental Sciences Center Orthodontics Department, Ankara, Turkey.

Corresponding author: **Fidan Alakus Sabuncuoglu.**

Erzurum Mareşal Çakmak Military Hospital Dental Center Orthodontics Department, Erzurum, Turkey.

+90 442 3812665; e-mail, fidansabuncuoglu@yahoo.com.tr.

Received August 19, 2010; Last Revision November 7, 2010;

Accepted November 10, 2010.

DOI:10.4041/kjod.2011.41.3.211

odontic and orthopedic forces. Mandibular dental arch deficiencies in growing patients are commonly corrected by the use of orthodontic expansion with Schwarz devices or functional devices like lip bumpers.⁷ These therapies have been recommended particularly in patients with lingually tipped teeth that need to be “decompensated.” Relatively stable results have been shown in younger patients.⁸

The following case report describes the successful treatment of a girl with Class II division 2 malocclusion by using a trombone appliance. To our knowledge, no previous report has described the use of a trombone appliance in a patient with a contracted low-

er dental arch.

DIAGNOSIS AND ETIOLOGY

A 14-year-old girl was referred to the Department of Orthodontics for correction of crowded anterior teeth. Her medical and dental histories were uneventful. Extraoral examination revealed a symmetrical convex profile (Fig 1). Intraoral examination showed a Class II div 2 malocclusion with a 1-mm overjet and a 3-mm overbite; a 4-mm mandibular midline shift to the left (Fig 1); anterior crowding of 6 mm in the mandibular arch and 4 mm in the maxillary arch; and a

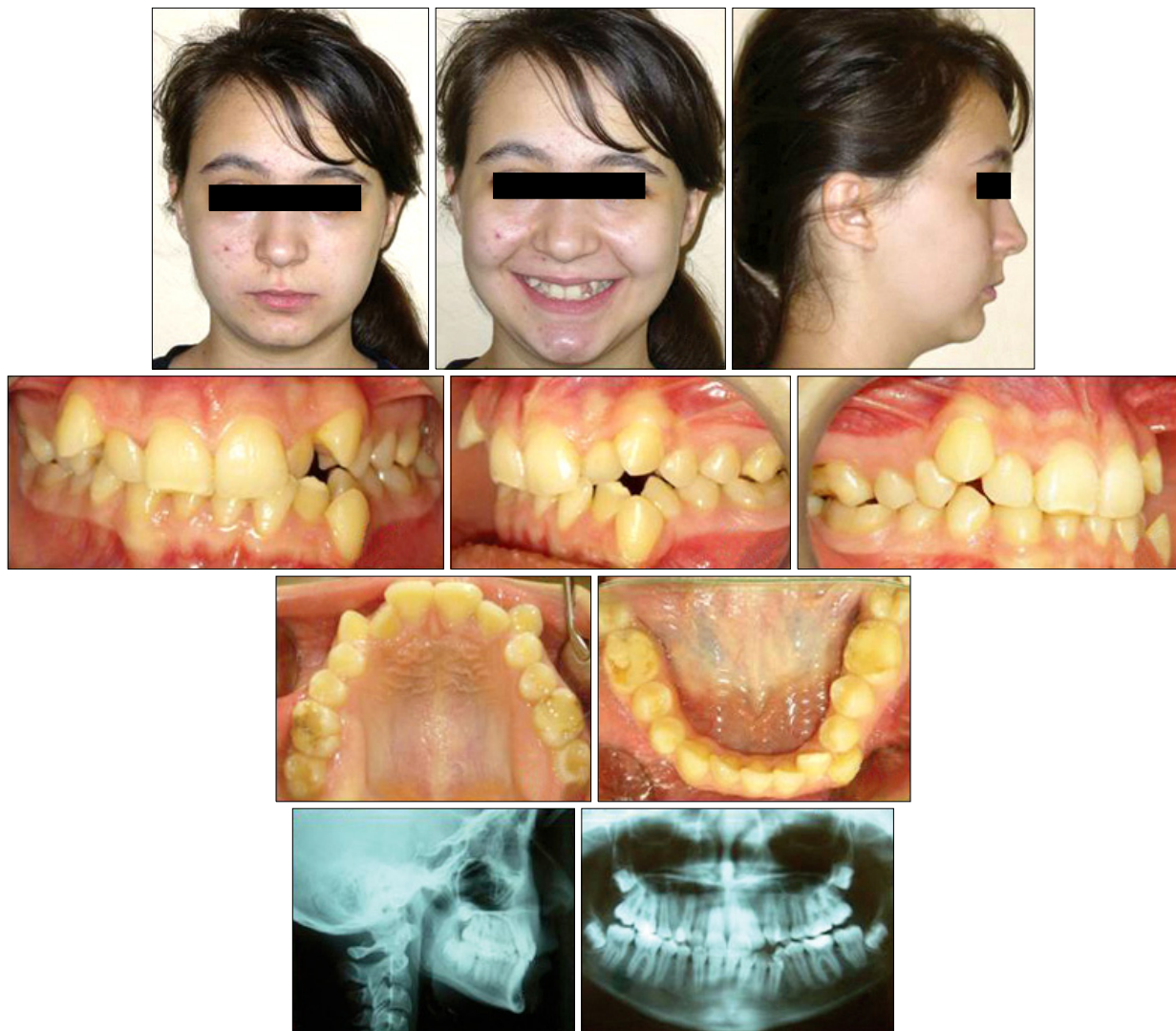


Fig 1. Pretreatment extraoral - intraoral views and radiographs.

displaced right canine caused by a severe deficiency in arch length.

Lateral cephalometric analysis revealed a mild skeletal Class II malocclusion (ANB angle: 4°); normal facial proportions (anterior facial height: 125 mm; posterior facial height: 84 mm; antero-posterior ratio: 64%); and retroclined mandibular and maxillary incisors (Fig 1, Table 1).

TREATMENT OBJECTIVES

The main goal of treatment was to increase the length of the maxillary and mandibular arches by correcting the inclination of the retroclined incisors.

Table 1. Pretreatment and posttreatment cephalometrics values

Measurement	Normal	Pretreatment	Posttreatment
SNA (°)	82 ± 2	76	77
SNB (°)	80 ± 2	73	74
ANB (°)	+2	+3	+3
NV-A (mm)	0	-10	-3
NV-Pog (mm)	-4/-6	-16	-9
S-N (mm)	71	70	69
S (°)	123	123	126
Ar (°)	145	156	148
Go (°)	130	118	113
Ar-Go (mm)	44	44	45
Go-Gn (mm)	71	73	72
Y axis (°)	60	66	67
SN/ANS-PNS (°)	7	10	12
SN/Occ. (°)	16	27	19
SN/Go-Gn (°)	32	34	33
ANS-PNS/ Go-Gn (°)	25	24	21
Co-A (mm)	-	84	85
Co-Pog (mm)	-	115	114
N-Me (mm)	-	125	121
N-ANS (mm)	-	56	55
ANS-Me (mm)	-	71	69
S-Go (mm)	-	81	79
S-Go/N-Me (%)	62 - 65	64	65
I/SN (°)	10°	103	106
I-NA (mm)	4	3	5
I/NA (°)	22	12	28
I/Go-Gn (°)	93	90	101
I-NB (mm)	4	3	5
I/NB (°)	25	18	30

TREATMENT ALTERNATIVES

The first treatment alternative involved distalization of the canines after extraction of the maxillary and mandibular first premolars to eliminate crowding. However, after evaluating the patient's profile and the inclination of the mandibular incisors, it was ultimately decided that extraction was unnecessary and that the molar relation and midline shift could be corrected through the use of trombone appliance and intraoral elastics.

Trombone appliance

The trombone appliance is designed specifically to assist antero-posterior arch development in the maxilla and mandible. Since the trombone appliance does not interfere with speech and is integrated with conventional fixed appliances, it has excellent potential for adult treatment.

The design is based on the slide principle, with an inner tube sliding freely within an outer tube to extend or contract the length of the appliance in a mechanism similar to that of the slide trombone, from which the appliance derives its name. The molar section of the appliance is retained with double lingual posts and includes a vertical tube attachment for insertion of the trombone section of the appliance (Fig 2). The appliance is preactivated to achieve the initial amount of expansion required. The mechanism is reactivated every 4 - 6 weeks by replacing the silicone tubing with a new tube of an appropriately increased length (Fig 2) until the arch form is corrected. The distal portion of wire is recurved and retained in a horizontal sheath on the molar band that extends mesially at the gingival level to engage the anterior segment of the lingual arch. The absence of frictional forces allows rapid tooth movement using gentle, controlled lingual forces.

TREATMENT PROGRESS

The maxillary and mandibular arches required dental expansion in 3 directions. The initial treatment phase consisted of expansion and distalization of the maxilla

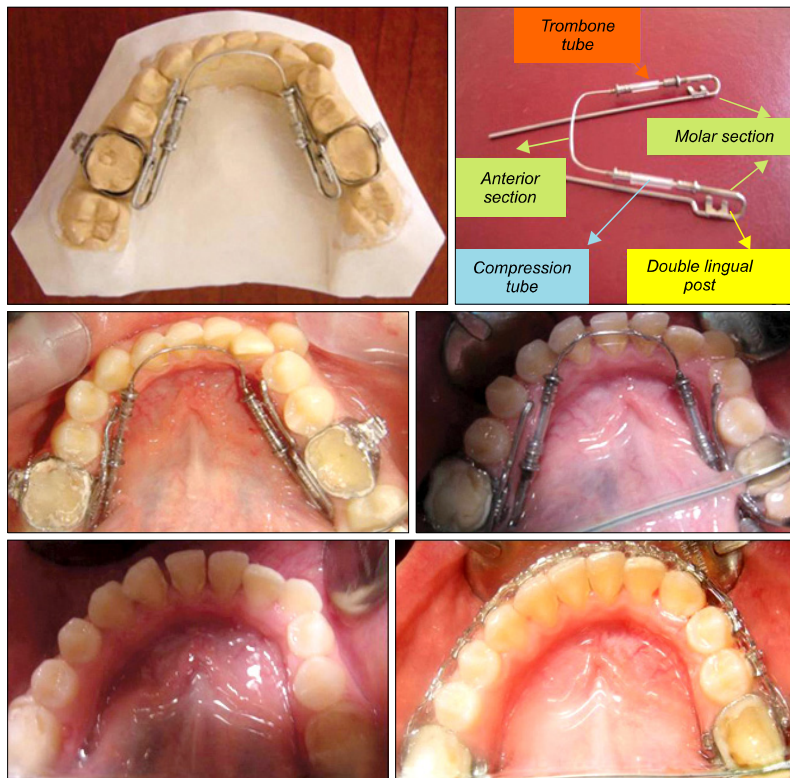


Fig 2. The Lingual Arch Developer appliance and treatment phase.

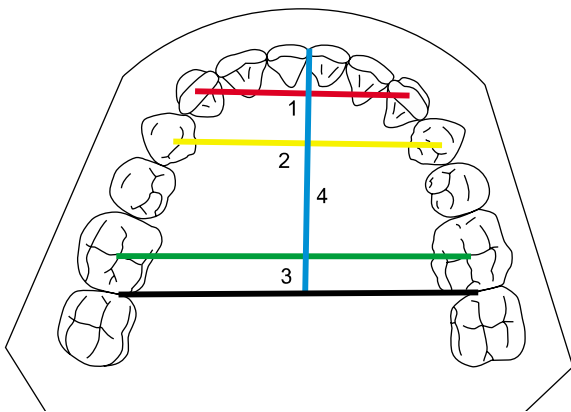


Fig 3. Dental arch dimensions with reference points. 1, Mandibular intercanine width: The distances between the canine cusp; 2, Mandibular interfirst premolar width: The distance in millimeters between buccal cusp tips; 3, Mandibular interfirst permanent molar width: The distance in millimeters from the centroids of the permanent first molars; 4, Arch depth: It was defined as the distance from the facial aspect of the incisors at the embrasure to a perpendicular drawn from the distal aspects of the permanent first molars.

to correct the arch form and adjust the malocclusion. A quad-helix appliance was fabricated from a 0.036-inch orthodontic wire and was soldered to the molar bands to expand the maxillary arch and align the anterior teeth in a fixed orthodontic treatment. The arms of the appliance were extended anterior to the distal aspect of the lateral incisors on both sides. Cervical headgear was worn by the patient 12 to 14 h per day to distalize maxillary molars.

Dental expansion of the mandible was achieved using a trombone appliance (Fig 2). Separators were inserted 3 days prior to the fitting. The appliance was positioned along the lingual outline of the mandibular incisors, inserted into the molar tubes, and fitted into the horizontal lingual sheaths in the molar bands (Fig 2). After 4 weeks, the trombone appliance was activated by 1 mm per side. Subsequent bilateral activation was achieved by replacing the silicon compression tubing with tubing that was 1 mm longer, once every 4 weeks to provide 1-mm activation per month until the desired amount of space was achieved (Fig 2).

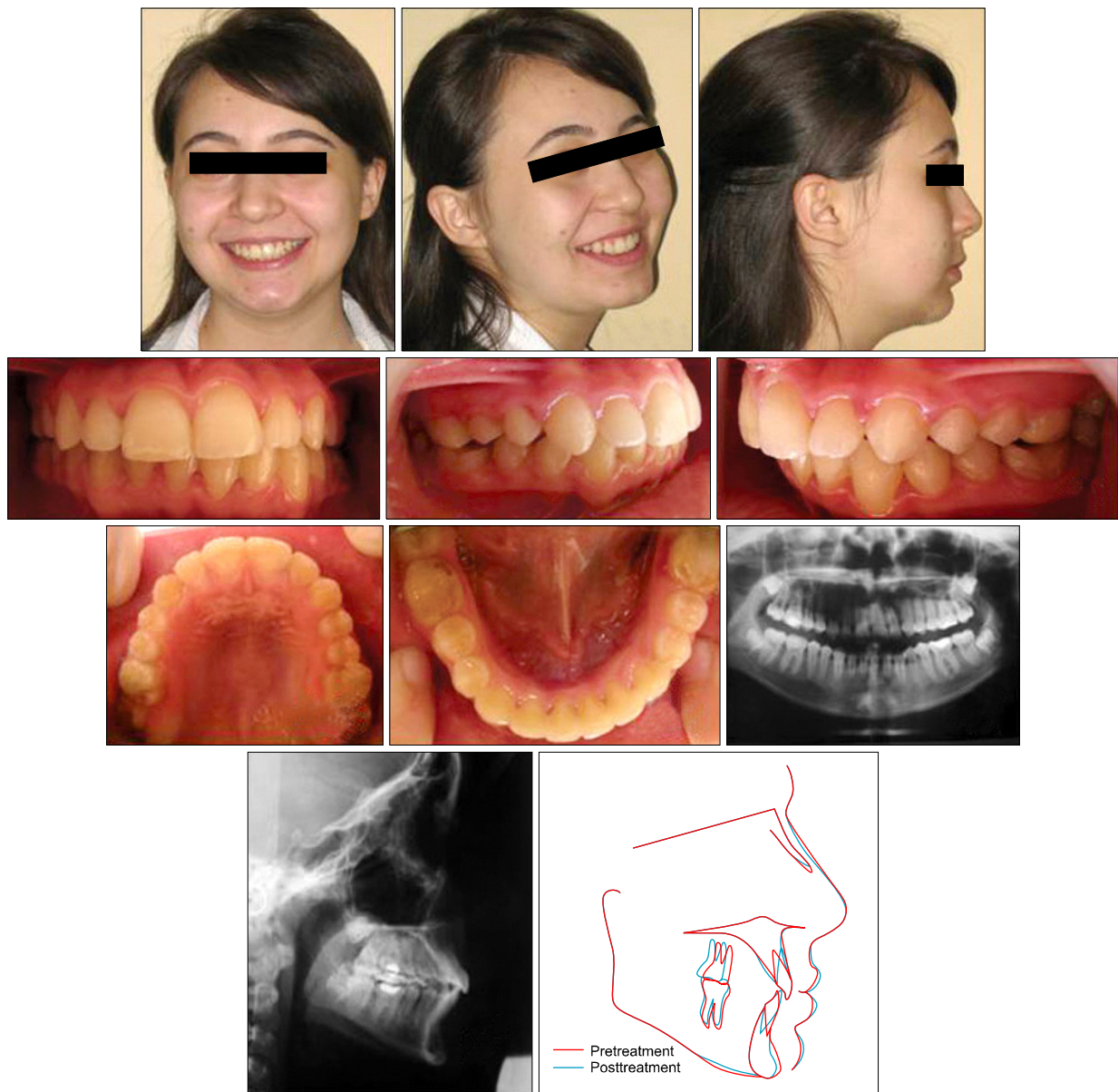


Fig 4. Intraoral-extraoral photographs and radiographs of patient after treatment and superposition of initial and final tracings on SN at S.

After sufficient space was obtained, the mandibular left canine was bracketed and aligned within the arch (Figs 2 and 3). Nickel titanium arch wires were used for initial leveling and alignment, whereas rectangular stainless steel arch wires were inserted to achieve acceptable occlusion. Class II and Class III elastics were used to correct the molar relationship and midline shift. The patient was seen at 4-week intervals during active treatment. After 13 months, functional occlusion

and favorable aesthetics were obtained, and the edge-wise appliances were removed (Fig 4, Table 1). Retention was accomplished by the use of a maxillary removable retainer and a mandibular fixed retainer, and follow-up visits were conducted once every 6 months.

Two years after retention, an acceptable occlusion was maintained without any marked relapse in occlusion, which indicates long-term stability of the occlusion (Fig 5).

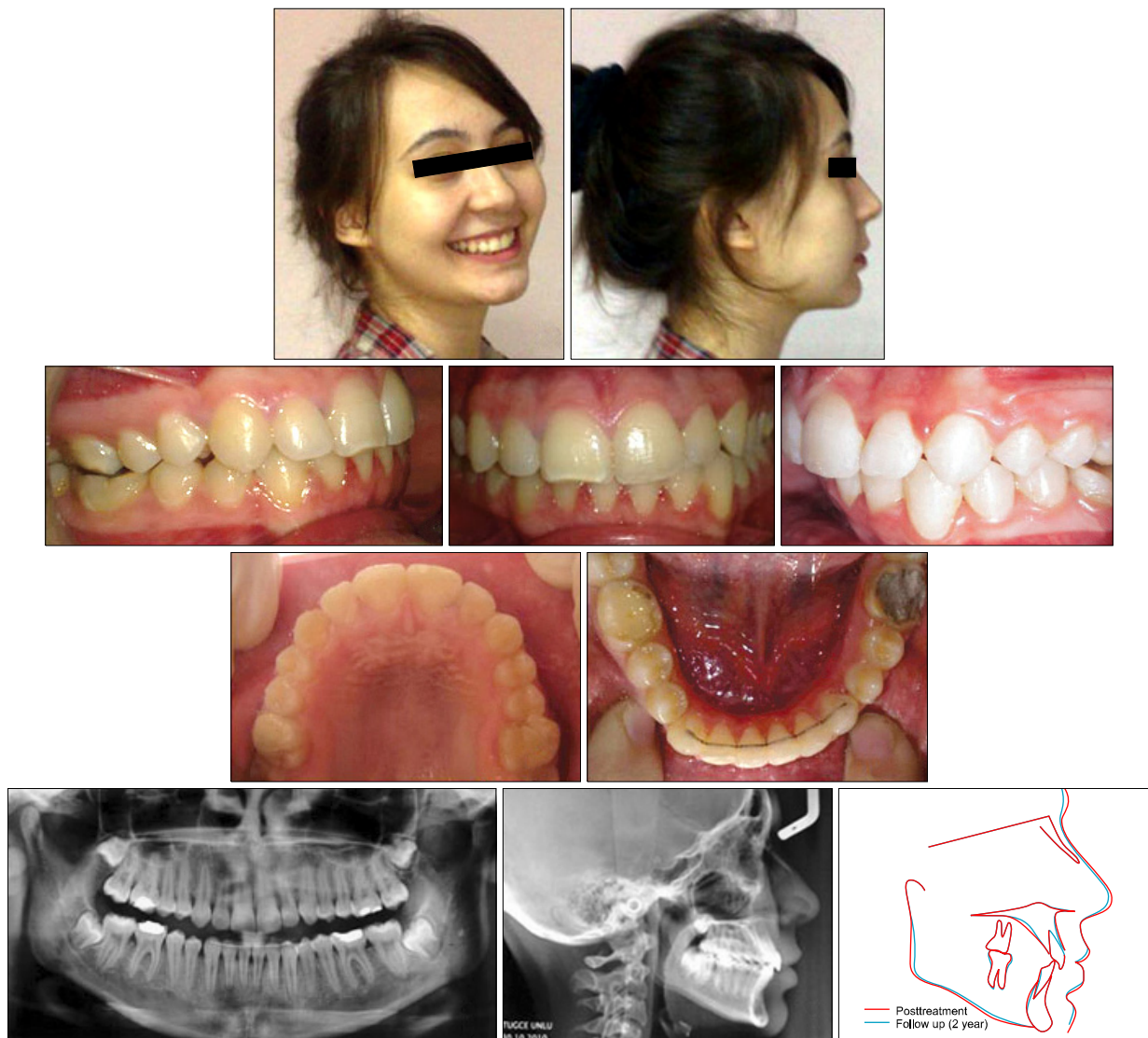


Fig 5. Facial-intraoral photographs, cephalometric-panoramic radiographs and superposition two years after retention.

RESULTS

The trombone appliance was effective for correcting mandibular dental arch crowding. The patient was satisfied with her teeth and her facial profile. Satisfactory intercuspation, interproximal contact, and root parallelism were achieved (Fig. 5). Tracing and superimposition of the initial and final cephalograms revealed distalized maxillary molars and minimally distalized mandibular molars that extruded as a result of the cervical headgear, the trombone appliance, and the intermaxillary elastics. Upper and lower molar distalization

and tipping are not the main outcomes of the treatment. The labial movement of the incisors combined with the increase in arch width account for most of the space gained. Collectively, these factors led to an increase in arch length and perimeter.

Protrusion and labial tipping of the maxillary and mandibular incisors were also observed (Table 1, Fig 5), and did not result in lip protrusion.

The mandibular intercanine width was increased by 1.2 mm, the mandibular intermolar width by 3.9 mm, and the arch depth by 3 mm; the total increase in the mandibular arch perimeter was 7.4 mm. The midline

deviation was corrected, and both overbite and overjet were reduced to acceptable levels, which allowed the patient to acquire a Class I molar relation with functional occlusion and a pleasing smile (Fig 5).

DISCUSSION

The most common reason to initiate orthodontic treatment is to eliminate dental crowding. Dental irregularities arise when an insufficient arch perimeter between the first permanent molars does not permit proper alignment of erupting permanent teeth. Spontaneous increases in arch perimeter are not expected after the first permanent molars erupt; actually, arch perimeter decreases as the patient passes from mixed to permanent dentition. During this period, mesial migration of the first permanent molars may result in crowding. Mild anterior crowding in mixed dentition patients can be eliminated by using a lingual arch to preserve leeway space and prevent mesial tipping or drifting of mandibular molars.

In the cases of permanent dentition, crowding may be resolved by extraction, interproximal reduction, or expansion. The main goal of extraction, advocated primarily by Case,² Tweed,⁹ Strang,¹⁰ and Begg,¹¹ is to obtain a tooth mass that is compatible with the existing arch dimension. Interproximal reduction, which is indicated for patients with mild to moderate crowding, involves the removal of the enamel from teeth contact points.¹² Expansion can be divided into 3 categories: orthodontic, passive, and orthopedic. Orthodontic expansion of dental arches results in lateral movement of the posterior buccal segments of the dental arch and creates a tendency toward lateral tipping of crowns.¹³ Passive expansion, achieved by use of a lip bumper or a Frankel appliance vestibular shield, widens the dental arches by shielding the occlusion from the forces of buccal and labial musculature, thereby allowing intrinsic forces produced by the tongue to create dimensional changes in the dental arches.¹⁴ Orthopedic expansion produces skeletal expansion by separating the midpalatal suture using rapid palatal expansion or other forms of treatment.¹⁵

Decision-making regarding expansion or extraction requires evaluation of the patient profile, inclination

and periodontal status of the mandibular incisors, severity of anteroposterior and vertical discrepancies, and the patient's growth potential. These factors are essential in determining whether mandibular expansion is appropriate in terms of the time, effort, and costs to the patient as well as to the orthodontist.

The gentle lingual pressure applied by the tongue represents the most natural method of arch development. Trombone appliances simulate this natural process by applying gentle, controlled forces to the lingual surface of the teeth. This approach has excellent potential for adult treatment, especially since it does not interfere with speech. Overall, the application of light and continuous physiological forces and invisible lingual aesthetics, and integration with conventional fixed appliances, which can eliminate cooperation issues, make the trombone appliance an ideal alternative to the mandibular Schwarz plate.

In the case presented, the mandibular arch length increased because of labial incisor movement, which corrected dental arch contraction and reduced crowding. At the end of treatment, the intercanine width increased by 1.2 mm, which is greater than that previously reported for lip bumpers.¹⁶ This can be attributed to active expansion of the arch achieved using the trombone appliance as compared to the passive expansion that the lip bumper provides by shielding teeth from perioral musculature forces. The use of the trombone appliance in this patient also resulted in increased intermolar width that was greater than or similar to that previously reported for lip bumpers.¹⁷ Although the mandibular intermolar width relapsed during the post-treatment period, a 2.9-mm net gain in the arch perimeter was achieved because of the increased intermolar width. Labial tipping of incisors and molar distalization resulted in an additional increase of approximately 3 mm in arch length; however, this length was less than what was previously reported for lip bumpers with acrylic shields.^{18,19}

Debate surrounds the stability of mandibular arch expansion. Nance⁸ reported that mandibular expansion is unstable and that intercanine width returns to pretreatment values over time; therefore, he advocated maintenance of intercanine width during orthodontic treatment. In contrast, Herberger¹⁷ reported that 68% of

expansions due to increase in mandibular intercanine width remained in place 4 - 6 years after retention. In this case, long-term retention and a fixed lingual retainer were planned to preserve gains in the intercanine width.

CONCLUSION

The use of a trombone appliance for less than 12 months during fixed orthodontic treatment resulted in increase in transversal and sagittal dimensions of the mandibular arch. Satisfactory skeletal and dental results were obtained by the end of the treatment. Among the various techniques used to develop the mandibular arch and to correct crowding in patients with a contracted arch and retroclined incisors, the invisible trombone appliance represents an acceptable method that can be used successfully in young patients with early mixed dentition as well as in adult patients with permanent dentition. Long-term studies that include cephalometric and clinical evaluations are needed to provide more detailed information and to determine stability following the treatment and retention periods.

REFERENCES

1. Angle EH. Treatment of malocclusion of the teeth. 7th ed. Philadelphia: S.S. White Dental Mfg. Co.; 1907. p. 44-59.
2. Case CS. The advisability of extracting teeth in the correction of irregularities. *Dent Cosmos* 1905;67:417-20.
3. Ferris T, Alexander RG, Boley J, Buschang PH. Long-term stability of combined rapid palatal expansion-lip bumper therapy followed by full fixed appliances. *Am J Orthod Dentofacial Orthop* 2005;128:310-25.
4. Geran RG, McNamara JA Jr, Baccetti T, Franchi L, Shapiro LM. A prospective long-term study on the effects of rapid maxillary expansion in the early mixed dentition. *Am J Orthod Dentofacial Orthop* 2006;129:631-40.
5. Gianelly AA. Leeway space and the resolution of crowding in the mixed dentition. *Semin Orthod* 1995;1:188-94.
6. Littlewood SJ, Millett DT, Doubleday B, Bearn DR, Worthington HV. Retention procedures for stabilising tooth position after treatment with orthodontic braces. *Cochrane Database Syst Rev* 2006;(1):CD002283.
7. Schwarz AM, Gratzinger M. Removable orthodontic appliances. Philadelphia, Pa: WB Saunders Co.; 1966.
8. Nance HN. The limitations of orthodontic treatment; mixed dentition diagnosis and treatment. *Am J Orthod* 1947;33:177-223.
9. Tweed CH. A philosophy of orthodontic treatment. *Am J Orthod Oral Surg* 1945;31:74-103.
10. Strang RHW. The fallacy of denture expansion as a treatment procedure. *Angle Orthod* 1949;19:12-22.
11. Begg PR. Light arch wire technique employing the principle of differential force. *Am J Orthod* 1961;47:30-48.
12. Sheridan JJ. Air-rotor stripping. *J Clin Orthod* 1985;19:43-59.
13. Horton SJ. The transverse stability of combined rapid palatal expansion and lip bumper therapy following comprehensive orthodontic treatment (dissertation). Dallas: Baylor College of Dentistry, 1997.
14. Fränkel R. Decrowding during eruption under the screening influence of vestibular shields. *Am J Orthod Dentofacial Orthop* 1974;65:372-406.
15. McNamara JA Jr. Treatment of arch length problems in the mixed dentition. *Bull Pac Coast Soc Orthod* 1992;64:42-4.
16. Nevant CT, Buschang PH, Alexander RG, Steffen JM. Lip bumper therapy for gaining arch length. *Am J Orthod Dentofacial Orthop* 1991;100:330-6.
17. Herberger RJ. Stability of mandibular intercuspid width after long periods of retention. *Angle Orthod* 1981;51:78-83.
18. Davidovitch M, McInnis D, Lindauer SJ. The effects of lip bumper therapy in the mixed dentition. *Am J Orthod Dentofacial Orthop* 1997;111:52-8.
19. Werner SP, Shivapuja PK, Harris EF. Skeletodental changes in the adolescent accruing from use of the lip bumper. *Angle Orthod* 1994;64:13-20.