



## The Protective Effects of Different Mycotoxin Adsorbents against Blood and Liver Pathological Changes Induced by Mold-contaminated Feed in Broilers

Zhengquan Che, Yulan Liu\*, Huirong Wang, Huiling Zhu, Yongqing Hou and Binying Ding

Hubei Key Laboratory of Animal Nutrition and Feed Science, Wuhan Polytechnic University, Wuhan, China 430023

**ABSTRACT** : An experiment was conducted to determine the effects of different mycotoxin adsorbents including esterified glucomannan (EGM), hydrated sodium calcium aluminosilicate (HSCAS) and compound mycotoxin adsorbent (CMA) on performance, blood parameters, and liver pathological changes in broilers fed mold-contaminated feed. Two hundred and forty 10-day-old broilers were randomly assigned to one of the five dietary treatments including: i) control diet; ii) mold-contaminated diet; iii) mold-contaminated diet+0.05% EGM; iv) mold-contaminated diet+0.2% HSCAS; v) mold-contaminated diet+0.1% CMA. At 35-days-old, blood and liver tissue samples were collected for analysis. 0.1% CMA improved ADG and ADFI during 10-42 d compared to the mold-contaminated group ( $p<0.05$ ). The mold-contaminated diet increased total white blood cell (WBC) number, haemoglobin (Hgb) concentration, hematocrit (Hct) level, serum aspartate aminotransferase (AST) and  $\gamma$ -glutamyl transferase (GGT) activities, and decreased red blood cell (RBC) number and serum globulin (GLB) and urea nitrogen (BUN) concentrations ( $p<0.05$ ). The three mycotoxin adsorbents alleviated the alteration of RBC, WBC, Hgb and AST caused by the mold-contaminated diet. Furthermore, 0.1% CMA increased GLB concentration and decreased Hct level and GGT activity ( $p<0.05$ ). Liver superoxide dismutase (SOD) activity was reduced, and myeloperoxidase (MPO) activity was increased by the mold-contaminated diet ( $p<0.05$ ). Both EGM and HSCAS prevented the increase of MPO activity ( $p<0.05$ ). Liver lesion, including severe vacuolar degeneration of hepatocytes, was observed in chicks fed the mold-contaminated diet. 0.05% EGM prevented these effects except for biliary hyperplasia and mild vacuolar degeneration. 0.2% HSCAS showed medium vacuolar degeneration of hepatocytes. Liver of broilers fed 0.1% CMA revealed a mild vacuolar degeneration. These results indicate that a mold-contaminated diet results in adverse effects on blood parameters and liver morphology. 0.05% EGM and 0.2% HSCAS partially alleviated the adverse effects. However, 0.1% CMA almost completely ameliorated the adverse effects. (**Key Words** : Mycotoxin, Mycotoxin Adsorbents, Blood Parameters, Liver Morphology, Broilers)

### INTRODUCTION

Mycotoxins are structurally diverse compounds produced by filamentous fungi that vary in their chemistry and biological effects (Sudakin et al., 2003). Among the various mycotoxins, aflatoxins (AFs), ochratoxin A (OTA), T-2, zearalenone (ZEN) and deoxynivalenol are often encountered in foodstuffs in different parts of the world. In nature, mycotoxins rarely occur as a single contaminant since many fungal species that produce mycotoxins grow and produce their toxic metabolites under similar conditions. Furthermore, a typical animal diet is made up of several sources, each of which may be contaminated with a different mycotoxin or more than one mycotoxin. Thus,

mixed feeds, made from foodstuffs contaminated with individual mycotoxins, may have all the mycotoxins present in different individual ingredients. The consumption of multiple mycotoxin contaminated diet may induce hematological, biochemical and liver physiological changes and growth depression in animals (Awad et al., 2006a, b; Shi et al., 2006; Razar et al., 2007; Gowda et al., 2008), and thus the presence of mycotoxins in poultry feeds causes significant economic losses to animal industries (Awad et al., 2006a).

At present, the most potent dietary approach to prevent mycotoxicoses in poultry is the use of adsorbents (Surai, 2005). In the last few years, most studies related to the alleviation of mycotoxicosis by the use of adsorbents are focused on aluminosilicates (mainly zeolites, hydrated sodium calcium aluminosilicates (HSCAS), and aluminosilicate-containing clays), and esterified

\* Corresponding Author: Yulan Liu. Tel: +86-27-83956175, Fax: +86-27-83956175, E-mail: yulanflower@126.com  
Received January 12, 2010; Accepted March 24, 2010

glucomannan (EGM) derived from cell wall of *Saccharomyces cerevisiae*<sup>1026</sup>. Several studies have revealed aluminosilicates (Pasha et al., 2007; Gowda et al., 2008) and esterified glucomannan (Julia et al., 2007; Girish et al., 2008) have shown considerable promise in countering aflatoxins. However, single mycotoxin adsorbent lack binding effects against multiple mycotoxins of practical importance (Edrington et al., 1997). Watts et al. (2003) reported that addition of HSCAS to diets containing multiple mycotoxins did not prevent the negative effects observed in poultry. Yiannikouris and Jouany (2002) revealed that EGM was not effective in counteracting the toxic effects of multiple mycotoxins. Huwig (2001) revealed the addition of different adsorbents to animal feed provided versatile tools of preventing mycotoxicosis. Therefore, the present trial was conducted to evaluate the effects of a compound mycotoxin adsorbent (CMA), the mixture of EGM and HSCAS on growth performance, haematological and serum biochemical parameters, and liver morphology in broilers chickens exposed to mold-contaminated feed.

## MATERIALS AND METHODS

### Experimental animals

The trial was conducted at the Wuhan Polytechnic University experimental broiler facility in Hubei province, P. R. China. A total of 240 1-d-old Avian male broilers were obtained from a commercial hatchery (Wuhan Zhengda Arbor Acres Poultry Breeding Co., Ltd., Wuhan, P. R. China) and then wing-banded and raised in 1.00×1.00 m<sup>2</sup> wire-floored brooders in an environmentally controlled electrically-heated room. A commercial broiler starter diet was fed from d 0 to 10 and was formulated according to NRC (1998) nutrient recommendations. On d 10, the birds were transferred to the 1.02×0.96×0.55 m<sup>3</sup> wire-floored battery brooders in another environmentally controlled room with electrical heating. The brooders were equipped with nipple drinkers and tube feeder. The broilers were allotted to five dietary treatments, with six replicate pens per treatment and eight birds per pen. The room temperature was maintained at 32°C from d 1 to 7, and then gradually reduced 2°C per week until the temperature reached 25°C. Chicks were exposed to 23 h light and 1 h darkness from d 1 to 4 and 16 h light and 8 h darkness from d 5 to 42. Birds were allowed to consume mash feed and water *ad libitum* for the entire duration of the experiment.

### Dietary treatments

Treatments included: i) control group (normal corn-soybean meal based diet); ii) mold-contaminated group (mold-contaminated diet); iii) 0.05% EGM group (mold-contaminated diet+0.05% EGM); iv) 0.2% HSCAS group

(mold-contaminated diet+0.2% HSCAS); v) 0.1% CMA group (mold-contaminated diet+0.1% CMA). The basal corn-soybean meal diets (Table 1) in starter (d 10 to 21) and grower-finisher (d 22 to 42) phases were formulated according to NRC (1998). The proximate analysis of the diet was performed according to the procedures of the Association of Official Analytical Chemists (AOAC, 1990). Mold-contaminated diets in starter and grower phases were prepared by replacing half of normal corn in the basal diets with mold-contaminated corn. CMA was produced by Hubei Key Laboratory of Animal Nutrition and Feed Science. CMA was mainly made up of EGM (Mycosorb, obtained from Beijing Alltech Biological Products Co., Ltd, China) and HSCAS (Aluminosilicate, obtained from Shanghai Aoge Biotechnology Co., Ltd, China).

The mycotoxin contaminated corn was prepared by the following procedures. First, water was added to the normal corn which was grinded adequately until about 20% moisture. Then, the wet corn was cultured in natural conditions (temperature 23-28°C, humidity 68-85%) until a clear mildew was observed. Finally, the corn which was contaminated with mycotoxins was naturally air-dried, mixed and sampled for detection.

### Mycotoxin analysis

Dietary contents of ochratoxin A and T-2 toxin were

**Table 1.** Ingredient and nutrient composition of diets

Ingredients	Starter	Grower-finisher
Corn	56.70	62.52
Soybean meal	31.00	26.35
Soybean oil	3.50	3.50
Fish meal	5.00	4.25
Limestone	1.34	1.14
Dicalcium phosphate	0.97	0.83
Salt	0.30	0.25
DL-methionine	0.19	0.16
Premix <sup>a</sup>	1.00	1.00
Total	100.00	100.00
Nutrient levels		
ME <sup>b</sup> (kcal/g)	2.97	3.03
Crude protein <sup>c</sup>	21.30	19.27
Calcium <sup>c</sup>	1.01	0.86
Available phosphorus <sup>b</sup>	0.47	0.42
Lysine <sup>b</sup>	1.14	1.00
Methionine <sup>b</sup>	0.57	0.51
Methionine+cystine <sup>b</sup>	0.90	0.82

<sup>a</sup> Vitamin and mineral premixes supplied per kilogram of diet: vitamin A, 10,000 IU; vitamin D<sub>3</sub>, 2,750 IU; vitamin E, 20 IU; menadione, 3.0 mg; thiamin, 2.5 mg; riboflavin, 6.0 mg; pyridoxine, 2.5 mg; vitamin B<sub>12</sub>, 12 µg; folic acid, 1.5 mg; niacin, 20 mg; pantothenic acid, 15 mg; biotin, 80 µg; Co, 300 µg; Cu, 16 mg; Fe, 102 mg; I, 1.2 mg; Mn, 95 mg; Se, 300 µg; Zn, 80 mg.

<sup>b</sup> Calculated. <sup>c</sup> Analyzed.

analyzed using a combination of gas chromatography and mass spectrometry as described by Groves et al. (1999) and modified by Raymond et al. (2003). The detection limit for these mycotoxins was 0.2 µg/g. Dietary aflatoxin B<sub>1</sub> content was determined using the high-performance liquid chromatography (0.77 µg/g detection limit) according to Matsui and Watanabe (1988), as modified by Smith and Sousadias (1993), and confirmed by Porter et al. (1995). Upon analysis, the contaminated maize contained 450.6 µg/kg of aflatoxin B<sub>1</sub>, 68.4 µg/kg of ochratoxin A, and 320.5 µg/kg of T-2 toxin.

### Growth performance determination

Chicks were weighed individually at 10 and 42-day-old, and feed consumption was recorded at the same time per pen average daily gain (ADG), average daily feed intake (ADFI) and feed: gain ratio (F/G) were calculated.

### Blood parameters analysis

At 35 d of age, blood samples were collected in tubes containing EDTA as anti-coagulant. Red blood cells (RBC), haemoglobin (Hgb), hematocrit (Hct), mean corpuscular haemoglobin concentration (MCHC), mean corpuscular haemoglobin (MCH), mean corpuscular volume (MCV), and total white blood cells (WBC) were determined using a blood counter (Coulter STKS model, Coulter electronics, Ltd, Luton, UK) with adapted dilutions.

At 35 d of age, blood was collected in non-heparinised tubes from six birds (one bird per replicate) in each treatment by puncturing the brachial vein. The sample was centrifuged at 3,000 rpm for 10 min and serum samples were separated and preserved at -20°C until analysis. The analyzed serum parameters included glucose (GLU), total protein (TP), globulin (GLB), albumin (ALB), blood urea nitrogen (BUN), and the activities of  $\gamma$ -glutamyl transferase (GGT), alanine aminotransferase (ALT), aspartate aminotransferase (AST) and alkaline phosphatase (ALP), which were determined by using an automatic analyser (Hitachi 7020 automatic biochemical analyzer, Japan).

### Liver enzyme activities determination

At 35 d of age, after blood sampling, six birds (one bird per replicate) in each treatment were killed, and liver tissue

was collected, snap-frozen in liquid nitrogen, and then stored in a freezer at -80°C until analysis. The liver antioxidant or oxidant parameters included malondialdehyde (MDA), myeloperoxidase (MPO) and superoxide dismutase (SOD) using assay kits (Nanjing Jiancheng Bioengineering Institute, Nanjing, China).

### Hepatic morphology

At 35 d of age, liver of one bird in each treatment was excised. Liver was dissected out, fixed in 10% neutral buffered formalin, embedded in paraffin and sectioned in pieces of 5 µm thickness and stained with hematoxylin and eosin (H&E) for microscopy examination. The slides were examined under 400×Magnification using an optical microscope (CarlZeiss, Germany).

### Statistical analyses

Data were analyzed by one-way ANOVA using SPSS 13.0 software as a completely randomized block design. Duncan's multiple range test was applied to compare treatment means differences. All statements of differences were based on significance at  $p < 0.05$ . All data were expressed as mean±SD.

## RESULTS

### Growth performance

Growth performance data are presented in Table 2. As compared to control group, the mold-contaminated diet group showed no significant difference on ADG, ADFI and F/G during 10-42 d ( $p > 0.05$ ). EGM and HSCAS had no effect on growth performance ( $p > 0.05$ ). Supplementation with 0.1% CMA in the contaminated diet significantly improved ADG and ADFI during 10-42 d ( $p < 0.05$ ).

### Blood parameters

Haematological parameters data are presented in Table 3. The mold-contaminated diet significantly increased the levels of WBC, Hgb and Hct, and significantly decreased RBC level ( $p < 0.05$ ). The addition of three mycotoxin adsorbents (EGM, HSCAS and CMA) alleviated the alteration of RBC, WBC and Hgb caused by mold-contaminated diet. Furthermore, supplementation of 0.05%

**Table 2.** Effect of three mycotoxin adsorbents on growth performance of broilers during 10-42 day of age

BW	CON	MOLD	EGM	HSCAS	CMA	p value
ADG (g)	68±2 <sup>ab</sup>	65±2 <sup>a</sup>	67±2 <sup>ab</sup>	66±3 <sup>a</sup>	70±2 <sup>b</sup>	0.084
ADFI (g)	117±3 <sup>ab</sup>	112±3 <sup>a</sup>	112±4 <sup>a</sup>	115±2 <sup>ab</sup>	118±4 <sup>b</sup>	0.048
F/G	1.71±0.06	1.71±0.01	1.67±0.02	1.73±0.06	1.69±0.02	0.275

CON = Control group; MOLD = Mold-contaminated group; EGM = Esterified glucomannan group; HSCAS = Hydrated sodium calcium aluminosilicate group; CMA = Compound mycotoxin adsorbent group.

ADFI = Average daily feed intake; ADG = Average daily gain; F/G = Feed/gain.

<sup>a, b</sup> Values within a row with the different superscripts significantly different ( $p < 0.05$ ).

**Table 3.** Effect of different adsorbents on white blood cells differential count of broilers

Index	CON	MOLD	EMG	HSCAS	CMA	p value
RBC ( $10^{12}/L$ )	2.52±0.11 <sup>b</sup>	2.29±0.10 <sup>a</sup>	2.47±0.20 <sup>b</sup>	2.45±0.08 <sup>b</sup>	2.48±0.15 <sup>b</sup>	0.025
WBC ( $10^9/L$ )	250±4 <sup>a</sup>	261±5 <sup>b</sup>	251±7 <sup>a</sup>	248±13 <sup>a</sup>	250±6 <sup>a</sup>	0.012
Hgb (g/L)	102±4 <sup>a</sup>	108±4 <sup>b</sup>	103±5 <sup>a</sup>	100±4 <sup>a</sup>	101±3 <sup>a</sup>	0.009
Hct	0.305±0.014 <sup>a</sup>	0.326±0.013 <sup>c</sup>	0.321±0.022 <sup>bc</sup>	0.304±0.009 <sup>a</sup>	0.309±0.010 <sup>ab</sup>	0.010
MCV (fl)	128±3	129±3	130±2	130±1	131±2	0.419
MCH (pg)	42.6±1.72	42.7±1.40	42.8±1.19	42.9±0.78	43.1±1.28	0.935
MCHC (g/L)	331±8	331±5	329±5	330±5	329±5	0.972

CON = Control group; MOLD = Mold-contaminated group; EMG = Esterified glucomannan group; HSCAS = Hydrated sodium calcium aluminosilicate group; CMA = Compound mycotoxin adsorbent group.

RBC = Red blood cells; Hgb = Haemoglobin; Hct = Hematocrit; MCHC = Mean corpuscular haemoglobin concentration; MCH = Mean corpuscular haemoglobin; MCV = Mean corpuscular volume; WBC, total white blood cells.

<sup>a, b, c</sup> Values within a row with the different superscripts significantly different ( $p < 0.05$ ).

HSCAS or 0.1% CMA to the diet containing mycotoxins significantly decreased Hct ( $p < 0.05$ ).

Serum biochemical parameters data are presented in Table 4. Consumption of contaminated feed resulted in a significant increase in GGT and AST activities, and a marked decrease in the concentration of BUN and GLB as compared to the control diet ( $p < 0.05$ ). When compared to mold-contaminated group, three mycotoxin adsorbents (EGM, HSCAS, and CMA) significantly decreased the activity of AST. Supplementation of 0.1% CMA to the diet

containing mycotoxins markedly decreased GGT activity ( $p < 0.05$ ). Furthermore, the adding of 0.1% CMA to the diet mold-contaminated significantly improved GLB content ( $p < 0.05$ ).

#### Liver oxidant and antioxidant enzymes

Liver oxidant and antioxidant enzymes data are presented in Table 5. Liver SOD activity was reduced and MPO activity was increased by mold-contaminated diet respectively ( $p < 0.05$ ). Both EGM and HSCAS prevented

**Table 4.** Effects of three mycotoxin adsorbents on biochemical indicators of broilers

Index	CON	MOLD	EGM	HSCAS	CMA	p value
ALT (U/L)	5.37±1.77	5.50±1.60	6.25±1.03	6.57±1.99	6.00±1.41	0.554
AST (U/L)	221±17 <sup>a</sup>	302±25 <sup>b</sup>	229±14 <sup>a</sup>	230±13 <sup>a</sup>	224±12 <sup>a</sup>	0.001
ALP (U/L)	1,294±218	1,628±199	1,445±87	1,550±378	1,294±113	0.112
GGT (U/L)	14.8±1.6 <sup>b</sup>	17.6±1.5 <sup>a</sup>	14.7±0.8 <sup>b</sup>	16.0±1.7 <sup>ab</sup>	14.5±1.3 <sup>b</sup>	0.001
TP (g/L)	29.2±1.2	26.9±2.9	28.0±0.7	27.9±2.2	28.7±2.1	0.367
ALB (g/L)	10.1±0.8	10.8±0.6	10.6±0.7	10.2±1.3	10.8±0.7	0.500
GLB (g/L)	18.6±0.8 <sup>b</sup>	16.8±1.1 <sup>a</sup>	17.5±0.3 <sup>ab</sup>	17.6±0.8 <sup>ab</sup>	18.4±1.5 <sup>b</sup>	0.040
BUN (mmol/L)	0.57±0.02 <sup>b</sup>	0.40±0.06 <sup>a</sup>	0.46±0.09 <sup>a</sup>	0.41±0.08 <sup>a</sup>	0.46±0.08 <sup>a</sup>	0.019
GLU (mol/L)	12.8±0.9	12.7±0.3	12.6±0.4	13.0±0.6	13.0±1.1	0.857

CON = Control group; MOLD = Mold-contaminated group; EGM = Esterified glucomannan group; HSCAS = Hydrated sodium calcium aluminosilicate group; CMA = Compound mycotoxin adsorbent group.

ALT = Alanine aminotransferase; AST = Aspartate aminotransferase; ALP = Alkaline phosphatase; GGT =  $\gamma$ -glutamyl transferase; TP = Total protein; ALB = Albumin; GLB = Globulin; BUN = Blood urea nitrogen; GLU = Glucose.

<sup>a, b</sup> Values within a row with the different superscripts significantly different ( $p < 0.05$ ).

**Table 5.** Effects of three mycotoxin adsorbents on the activity of SOD (U/mg Protein), MDA (nmol/mg Protein) and MPO (mU/ml) in the liver tissue of broilers

Index	CON	MOLD	EGM	HSCAS	CMA	p value
SOD	298±19 <sup>b</sup>	245±24 <sup>a</sup>	252±17 <sup>a</sup>	246±20 <sup>a</sup>	286±48 <sup>ab</sup>	0.023
MDA	4.81±0.53	5.29±0.90	4.72±0.78	5.18±0.35	4.47±0.51	0.380
MPO	0.20±0.04 <sup>a</sup>	0.30±0.09 <sup>b</sup>	0.20±0.03 <sup>a</sup>	0.17±0.05 <sup>a</sup>	0.22±0.06 <sup>ab</sup>	0.079

CON = Control group; MOLD = Mold-contaminated group; EGM = Esterified glucomannan group; HSCAS = Hydrated sodium calcium aluminosilicate group; CMA = Compound mycotoxin adsorbent group.

MDA = Malondialdehyde; MPO = Myeloperoxidase; SOD = Superoxide dismutase.

<sup>a, b</sup> Values within a row with the different superscripts significantly different ( $p < 0.05$ ).

the increase of MPO activity ( $p < 0.05$ ).

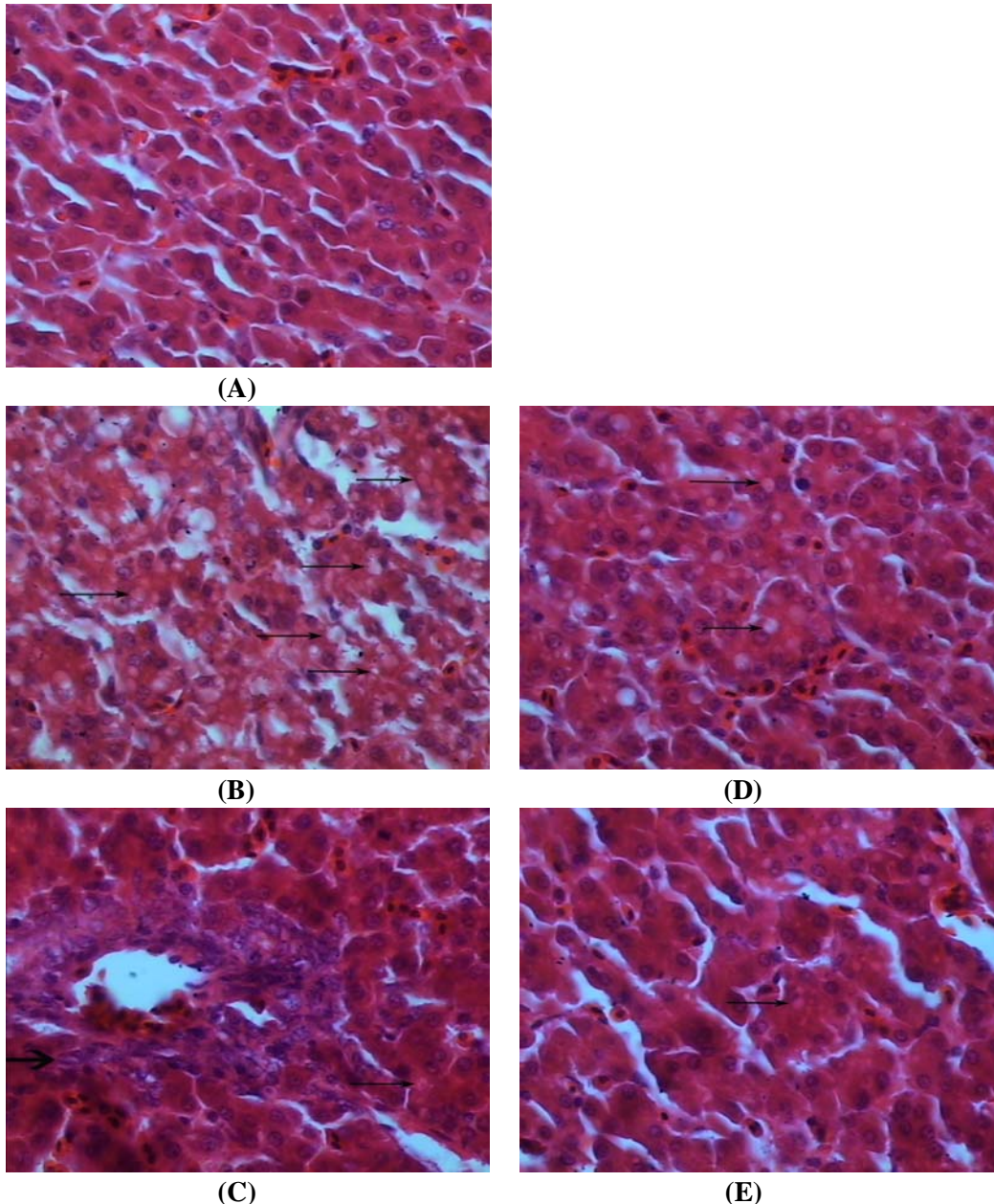
### Hepatic histopathology

The liver section from chicks fed the control diet revealed normal histological pictures (Figure 1A). Feeding mold-contaminated diet caused liver lesion including severe vacuolar degeneration of hepatocytes in chicks (Figure 1B). 0.05% EGM supplementation prevented these effects except with biliary hyperplasia and mild vacuolar degeneration (Figure 1C). 0.2% HSCAS group showed

medium vacuolar degeneration of hepatocytes in liver (Figure 1D). Liver of broilers fed contaminated diet supplemented with 0.1% CMA revealed a mild vacuolar degeneration (Figure 1E).

### DISCUSSION

The adverse effects of mycotoxins on animal health is expressed in a diverse range of symptoms including haemostasis blood system damage (Abbès et al., 2006), skin



**Figure 1.** Photomicrographs of liver sections from chicks fed with control diet, mold-contaminated diet alone or with 0.05% EGM, 0.2% HSCAS or 0.1% CAM. Liver section from chicks fed with control diet (A), mold-contaminated diet (feeding mold-contaminated diet) (B), 0.05% EGM diet (feeding mold-contaminated diet and 0.05% EGM) (C), 0.2% HSCAS diet (feeding mold-contaminated diet and 0.2% HSCAS) (D), or 0.1% CMA diet (feeding mold-contaminated diet and 0.1% CMA) (E). Vacuolar degeneration was indicated by “→”, and biliary hyperplasia was indicated by “→”. Original magnifications 400×.

lesions, immunosuppression, hepatotoxicity, nephrotoxicity, neurotoxicity, genotoxicity and even death (Dvorska et al., 2007).

Hematological parameters of animal are determined as an index of their health status. In our study, the mold-contaminated diet increased the levels of WBC, Hgb and Hct, and decreased RBC level. Similarly, Abbès et al. (2006) reported that mice treated with 500 mg/kg ZEN caused a significant increase in WBC, Hct, Hgb, MCV, MCH, MCHC and MPV levels, and decrease in RBC level. Our results indicate that haemostasis blood system damage was induced by mycotoxins.

Serum biochemical parameters such as AST and ALT activities provide a sensitive and specific measure of hepatic function or injury (Abbès et al., 2006). Serum ALP and GGT activities (Kubena et al., 1997), and TP, ALB, GLB and GLU concentrations (Mathur et al., 2001) have also been described as valuable parameters of hepatic injury and function. In our study, mold contaminated feed resulted in an increase in GGT and AST activities, and a decrease in the concentration of BUN and GLB as compared to the control diet. Aravind et al. (2003) reported broilers fed a naturally contaminated diet was associated with significant decrease in BUN concentration and increase in GGT activity along with unaltered TB concentration at 21d of age. Sharma et al. (2008) reported serum AST activity was increased by fed chick with fumonisin B<sub>1</sub> or moniliformin. Similar results were observed by other studies (Shi et al., 2005; Gowda et al., 2008), which suggests that mycotoxins exert a direct toxic effect on animal liver.

In our study, multiple mycotoxins altered hematological and biochemical parameters including increased serum AST and GGT activities and WBC, Hgb and Hct levels, and decreased serum GLB and BUN concentrations, and RBC level, which suggests that multiple mycotoxin exerted a direct toxic effect on haemostasis blood system and hepatocytes.

Results found concerning serum biological and haematological parameters were confirmed and supported by liver histological findings. In the present study, liver from chicks treated with mold-contaminated feed showed liver lesion including severe vacuolar degeneration of hepatocytes, which is consistent with other studies (Banlunara et al., 2005; Dvorska et al., 2007).

Mycotoxin inducing hepatotoxicity may be due to many complex reasons. One of the important reasons may be that mycotoxins cause oxidative stress in liver (Gowda et al., 2008). The formation of potent cytotoxic oxidant peroxynitrite is increased, and these events may culminate in lipid peroxidation, cell death and hepatic injury (Gowda et al., 2008). In our study, multiple mycotoxins decreased SOD activity in liver. Similar to our study, Shi et al. (2005) indicated the diet containing AFs markedly decreased

activities of liver SOD and GSH-Px. Gowda et al. (2008) also reported AFB<sub>1</sub> decreased hepatic antioxidant function. In addition, the activity of MPO was increased by mold-contaminated feed, which indicates that liver antioxidant capacity was depressed to a certain extent. Ferrante et al. (2006) reported a single oral OTA administration (10 mg/kg) in mice increased lipid peroxidation and MPO activity in liver. In our study, multiple mycotoxins contamination induced a negative impact on health and liver, which may be partially due to liver antioxidant depletion.

EGM is a toxin binder consisting of functional carbohydrates extracted from yeast cell walls of *Saccharomyces cerevisiae*. It has a large surface area of 22,000 m<sup>2</sup> per 1 kg and contains a large number of pores of different sizes to trap a wide range of chemicals (Banlunara et al., 2005). In the current study, addition of 0.05% EGM to the mold-contaminated diet had partially ameliorated the changes of hematological and biochemical parameters, hepatic injury and hepatic antioxidative depletion except for growth performance. These results suggested that addition of 0.05% EGM seemed to partially counteract the toxins and partially restored damages induced by multiple mycotoxins, which may due to EGM partially trapping the mycotoxin molecule in its glucomannan matrix and preventing toxin absorption from the gastrointestinal tract. Similar results were noted by other studies. Aravind et al. (2003) reported that the addition of EGM to the contaminated diet improved the BUN concentration and decreased the GGT activity. Banlunara (2005) indicated that activities of ALP and GGT were increased by AFB<sub>1</sub>, and were decreased by EGM. Dvorska et al. (2007) revealed that inclusion of modified glucomannans (Mycosorb) into the T-2 toxin-contaminated diet provided a partial protection against the detrimental effects of the mycotoxin on the antioxidant defence in the chicken liver. Bintvihok et al. (2002, 2003) found that supplementation of AFB<sub>1</sub>-contaminated diet with EGM reduced the liver injury such as bile proliferation and fatty degeneration in ducklings. Similar results were also reported by Aravind et al. (2003). However, Banlunara (2005) reported that the inclusion of EGM in a ducklings diet did not reduce aflatoxin B<sub>1</sub>-induced hepatic injury. Our study also found that EGM didn't improve growth performance and only partially prevented the adverse effects of multiple mycotoxins, which indicates that deleterious effects of multiple mycotoxins could not be completely overcome by EGM.

HSCAS, a phyllosilicate clay of the smectite class, is shown to tightly bind aflatoxins and prevent aflatoxicosis in animals (Abbès et al., 2006). In the current study, addition of 0.2% HSCAS to the mold-contaminated diet partially ameliorated hematological and biochemical parameters, hepatic antioxidative status and hepatic injury except for growth performance. These results showed that 0.2%

HSCAS partially counteract the toxins and partially restored damages induced by multiple mycotoxins, which may be due to the high adsorptive property of HSCAS. Similarly, Gowda et al. (2008) indicated that HSCAS ameliorated the adverse effects of AFB<sub>1</sub> on some of the serum chemistry parameters, increased antioxidant capacity in liver, and reduced the severity of hepatic microscopic lesions due to AFB<sub>1</sub>. Abbès et al. (2006) reported the mixture of HSCAS with ZEN induced a reestablishment of haematological parameters, serum biochemical enzyme activities and histology of liver and kidney. However, Watts et al. (2003) revealed that addition of HSCAS to diets containing multiple mycotoxins did not prevent the negative effects observed in chicks and poultry. Huwig (2001) reported that HSCAS were effective in preventing aflatoxicosis, but their efficacy against zearalenone, ochratoxin, and trichothecenes was limited. Our study also found that EGM did not improve growth performance and only partially prevent the adverse effects of multiple mycotoxins, which indicates that HSCAS could partially restore damages induced by multiple mycotoxins.

Huwig (2001) pointed out that single adsorbent could not be effective against most types of mycotoxins, and combined use of different adsorbents would provide versatile tools for preventing mycotoxicosis. In our study, we added 0.1% CMA which was mainly made up of EGM and HSCAS to the mold-contaminated diets. We found that CMA markedly improved growth performance, significantly ameliorated the changes of hematological and biochemical parameters, and improved hepatic antioxidative status in multiple mycotoxins treated chicks, resuming its values towards near normal levels of control. Especially, livers of broilers fed contaminated diet supplemented with 0.1% CMA revealed the most mild liver injury near normal histological pictures of the control group. These results indicated that multiple mycotoxins in diets could be completely overcome by CMA. Our observation is consistent with the report of Huwig (2001). The possible reasons may be that EGM and HSCAS exerted synergistic or additive effects in counteracting the adverse effects of mycotoxins in the mold-contaminated diet.

It is concluded that mold-contaminated diets altered hematological and serum biochemistry parameters, depressed liver antioxidant capacity and led to hepatic injury in chicks. Supplementation with 0.05% EGM and 0.2% HSCA partially alleviated the adverse effects induced by mold-contaminated feed. However, 0.1% CMA almost completely ameliorated the adverse effects.

#### ACKNOWLEDGMENT

The authors express their gratitude to the Scientific and Technological Project of Hubei Province (2005AA201C30)

for the financial supports.

#### REFERENCES

- Abbès, S., Z. Ouannes, J. Salah-Abbes, Z. Houas, R. Oueslati, H. Bacha and O. Othman. 2006. The protective effect of hydrated sodium calcium aluminosilicate against haematological, biochemical and pathological changes induced by Zearalenone in mice. *Toxicol.* 47:567-574.
- AOAC. 1990. Official methods of analysis (15th Ed.). Association of Official Analytical Chemists, Arlington, Virginia, USA, p. 1200.
- Aravind, K. L., V. S. Patil, G. Devegowda, B. Umakantha and S. P. Ganpule. 2003. Efficacy of esterified glucomannan to counteract mycotoxicosis in naturally contaminated feed on performance and serum biochemical and hematological parameters in broilers. *Poult. Sci.* 82:571-576.
- Awad, W. A., J. Böhm, E. Razzazi-Fazeli, K. Faulk and J. Zentek. 2006a. Effect of addition of a probiotic microorganism to broiler diets contaminated with deoxynivalenol on performance and histological alterations of intestinal villi of broiler chickens. *Poult. Sci.* 85:974-979.
- Awad, W. A., J. Böhm, E. Razzazi-Fazeli and J. Zentek. 2006b. Effects of feeding deoxynivalenol contaminated wheat on growth performance, organ weights and histological parameters of the intestine of broiler chickens. *J. Anim. Nutr. Anim. Physiol.* 90:32-37.
- Banlunara, W., A. Bintvihok and S. Kumagai. 2005. Immunohistochemical study of proliferating cell nuclear antigen in duckling liver fed with aflatoxin B<sub>1</sub> and esterified glucomannan. *Toxicol.* 46:954-957.
- Bintvihok, A., W. Banlunara and T. Kaewamatawong. 2002. Aflatoxin detoxification by esterified glucomannans in ducklings. *Thai. J. Health Res.* 16:135-148.
- Bintvihok, A. and S. Kositcharoenkul. 2003. Aflatoxin B<sub>1</sub> and its metabolites residues in tissues and fecal excretion levels of aflatoxin B<sub>1</sub> and its metabolites of ducklings given feed containing aflatoxin and esterified glucomannan. *Proceedings of the 11th International Symposium of the World Association of Veterinary Laboratory Diagnosticians and OIE Seminar on Biotechnology (ISWAVLD)*. pp. 104-105.
- Dvorska, J. E., A. C. Pappas, F. Karadas, B. K. Speake and P. F. Surai. 2007. Protective effect of modified glucomannans and organic selenium against antioxidant depletion in the chicken liver due to T-2 toxin-contaminated feed consumption. *Comp. Biochem. Physiol.* 45:582-587.
- Edrington, T. S., A. B. Sarr, L. F. Kubena, R. B. Harvey and T. D. Phillips. 1997. Hydrated sodium calcium aluminosilicate (HSCAS), acidic HSCAS, and activated charcoal reduce urinary excretion of aflatoxin M<sub>1</sub> in turkey poults. Lack of effect by activated charcoal on aflatoxicosis. *Toxicol. Lett.* 89:115-122.
- Ferrante, M. C., M. Bilancione, G. M. Raso, E. Esposito, A. Iacono, A. Zaccaroni and R. Meli. 2006. Expression of COX-2 and *hsp72* in peritoneal macrophages after an acute Ochratoxin A treatment in mice. *Life Sci.* 79:1242-1247.
- Girish, C. K. and T. K. Smith. 2008. Effects of feeding blends of grains naturally contaminated with fusarium mycotoxins on

- small intestinal morphology of Turkeys. *Poult. Sci.* 87:1075-1082.
- Gowda, N. K. S., D. R. Ledoux, G. E. Rottinghaus, A. J. Bermudez and Y. C. Chen. 2008. Efficacy of turmeric (*Curcuma longa*), containing a known level of curcumin, and a hydrated sodium calcium aluminosilicate to ameliorate the adverse effects of aflatoxin in broiler chicks. *Poult. Sci.* 87:1125-1130.
- Groves, F. D., L. Zhang, Y. S. Chang, P. F. Ross, H. Casper, W. P. Norred, Y. W. Cheng and Fraumeni. 1999. Fusarium mycotoxins in corn and corn products in a high-risk area for gastric cancer in Shandong province, China. *J. AOAC Int.* 82:657-662.
- Huwig, A., S. Freimund, O. Kappeli and H. Dutler. 2001. Mycotoxin detoxication of animal feed by different adsorbents. *Toxicol. Lett.* 122:179-188.
- Julia, E. D., C. P. Athanasios, F. Karadas, K. S. Brian and F. S. Peter. 2007. Protective effect of modified glucomannans and organic selenium against antioxidant depletion in the chicken liver due to T-2 toxin-contaminated feed consumption. *Toxicol. Appl. Pharmacol.* 145:582-587.
- Kubena, L. F., R. B. Harvey, S. A. Buckley, T. S. Edrington and G. E. Rottinghaus. 1997. Individual and combined effects of moniliformin present in fusarium fujikuroi culture material and aflatoxin in broiler chicks. *Poult. Sci.* 76:265-270.
- Mathur, S., P. D. Constable and R. M. Eppley. 2001. Fumonisin B1 is hepatotoxic and nephrotoxic in milk-fed calves. *Toxicol. Sci.* 60:385-396.
- Matsui, Y. and M. Watanabe. 1988. Quantitative analysis of fusaric acid in the cultural filtrate and soybean plants inoculated with *Fusarium oxysporum* var. *redolens*. *J. Rakuno Gakuen Univ. Nat. Sci.* 13:159-167.
- NRC. 1998. Nutrient requirements of swine (10th Ed.). National Academic Press, Washington, DC.
- Pasha, T. N., M. U. Farooq, F. M. Khattak, M. A. Jabbar and A. D. Khan. 2007. Effectiveness of sodium bentonite and two commercial products as aflatoxin adsorbents in diets for broiler chickens. *Anim. Feed Sci. Technol.* 132:103-110.
- Porter, J. K., C. W. Bacon, E. M. Wray and W. M. Hagler. 1995. Fusaric acid in *Fusarium moniliforme* cultures, corn, and feeds toxic to livestock and the neurochemical effects in the brain and pineal gland of rats. *Nat. Toxins* 3:91-100.
- Raymond, S. L., T. K. Smith and H. V. L. N. Swamy. 2003. Effects of feeding a blend of grains naturally contaminated with *Fusarium mycotoxins* on feed intake, serum chemistry, and hematology of horses, and the efficacy of a polymeric glucomannan mycotoxin adsorbent. *J. Anim. Sci.* 81:2123-2130.
- Rezar, V., T. Frankič, M. Narat, A. Levart and J. Salobir. 2007. Dose-dependent effects of T-2 toxin on performance, lipid peroxidation, and genotoxicity in broiler chickens. *Poult. Sci.* 86:1155-1160.
- Sharma, D., R. K. Asrani, D. R. Ledoux, N. Jindal, G. E. Rottinghaus and K. Gupta. 2008. Individual and combined effects of fumonisin B1 and moniliformin on clinicopathological and cell-mediated immune response in Japanese quail. *Poult. Sci.* 87:1039-1051.
- Shi, Y. H., Z. R. Xu, J. L. Feng and C. Z. Wang. 2006. Efficacy of modified montmorillonite nanocomposite to reduce the toxicity of aflatoxin in broiler chicks. *Anim. Feed Sci. Technol.* 129:138-148.
- Smith, T. K. and M. G. Sousadias. 1993. Fusaric acid content of swine feedstuffs. *J. Agric. Food Chem.* 41:2296-2298.
- Sudakin, D. L. 2003. Trichothecenes in the environment: Relevance to human health. *Toxicol. Lett.* 143:97-107.
- Surai, P. F. and J. E. Dvorska. 2005. Effects of mycotoxins on antioxidant status and immunity. *The Mycotoxin Blue Book*. D. Diaz, ed. Nottingham Univ. Press, UK. pp. 93-137.
- Watts, C. M., Y. C. Chen, D. R. Ledoux, J. N. Broomhead, A. J. Bermudez and G. E. Rottinghaus. 2003. Effects of multiple mycotoxins and a hydrated sodium calcium aluminosilicate in poultry. *Int. J. Poult. Sci.* 2(6):372-378.
- Yiannikouris, A. and J. Jouany. 2002. Mycotoxins in feed and their fate in animals: a review. *Anim. Res.* 51:81-99.