

콧등에 발생한 화골성 근염: 1례 보고

송제니퍼김 · 황소민 · 임광열 · 정용휘 · 안성민

좋은문화병원 성형외과

Myositis Ossificans on the Nasal Dorsum: A Case Report

Jennifer K Song, M.D., So Min Hwang, M.D.,
Kwang Ryeol Lim, M.D., Yong Hui Jung, M.D.,
Sung Min Ahn, M.D.

Department of Plastic & Reconstructive Surgery, Good
Moonhwa Hospital, Busan, Korea

Purpose: Myositis ossificans is a benign condition of heterotopic bone formation that still requires more of its pathologic explanation. The lesions are localized predominantly to the high-risk sites of injury, involving flexor muscles of the upper limbs and thigh, but rarely in the head and neck area.

Methods: A case of a 44-year-old male patient presented with a palpable hard mass on nasal dorsum. The patient experienced a similar lesion on upper limb few years ago. On computed tomographic image, the lesion presented focal definite increase in opacity compatible to adjacent bone density on nasal dorsum.

Results: The lesion was excised under open rhinoplasty incision. The pathologic report revealed focal bone formation and calcification within skeletal muscle.

Conclusion: We describe a unique and only case of a myositis ossificans on nasal dorsum which is indifferent from previous concept.

Key Words: Myositis ossificans, Nose

I. INTRODUCTION

Myositis Ossificans is a benign condition of heterotopic bone formation that remains difficult to distinguish between soft tissue and bone. Traumatic myositis ossificans *circumscripta* also called traumatic myositis

ossificans, localized myositis ossificans or fibrodysplasia ossificans *circumscripta* is a disease in which muscles are ossified after trauma or inflammation.¹⁻³ The lesions are localized predominantly to the high-risk sites of injury, involving flexor muscles of the upper limbs and thigh, particularly the brachialis anterior and the quadriceps femori muscles.^{2,4} It is rarely encountered in the head and neck area. Few cases reported in the head and neck area involve the masticatory muscle such as masseter, medial and lateral pterygoid, or sternocleidomastoid muscle.³

Even vulnerable to repeated trauma and reported high incidence among facial trauma, nose has not occurred to be a common location for myositis ossificans. To our knowledge the case presented in this report is the first myositis ossificans developed in the nasal dorsum.

II. CASE

A 44-year-old male was referred to our clinic for evaluation of irregular nasal contour, suffered for three months. Few years before, the patient experienced similar features developed on right forearm and left upper arm, and had undergone simple excision at a local orthopedic clinic. At that time, biopsy report specified the lesion to be a calcification within a soft tissue structure, suspicious of Myositis Ossificans. The patient had no other remarkable medical history, and no other soft tissue or bone abnormality. As far as he knew, although he enjoyed playing soccer since youth, he couldn't confirm a history of previous facial trauma severe enough to cause any forms of paranasal soft tissue injury or fracture.

On physical examination, slightly tender beaded palpable hard mass was confirmed overlying the keystone area of the nasal dorsum (Fig. 1). The skin on the mass was mildly hyperemic. Routine laboratory findings were within normal limit. The mass was found radiopaque with definite increase in soft tissue density on computed tomography (Fig. 2).

The mass was completely dissected from the surrounding tissues through an open rhinoplasty incision.

Received June 21, 2010
Revised August 23, 2010
Accepted September 2, 2010

Address Correspondence: So Min Hwang, M.D., Department of Plastic and Reconstructive Surgery, Good Moonhwa Hospital, 899-8 Beomil 2-dong, Dong-gu, Busan 601-803, Korea. Tel: 051) 630-0100 / Fax: 051) 630-0145 / E-mail: sominhwang@hanmail.net

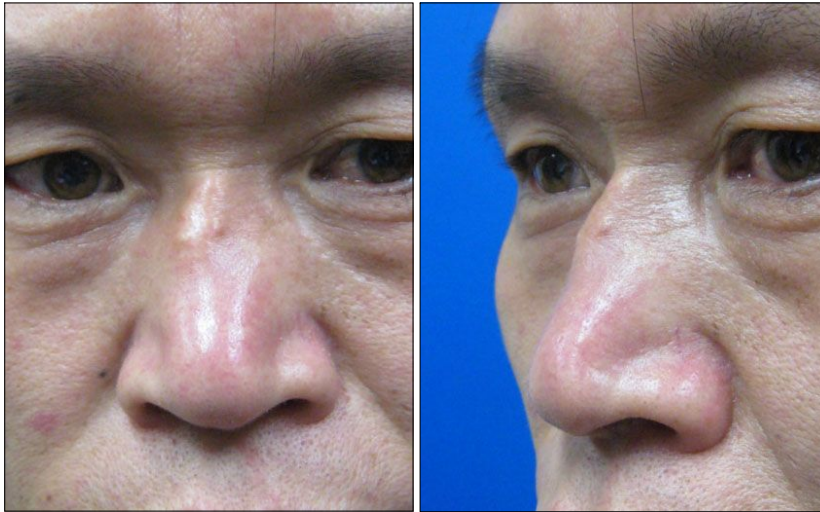

Fig. 1. Preoperative clinical photo presenting irregular nasal dorsum.

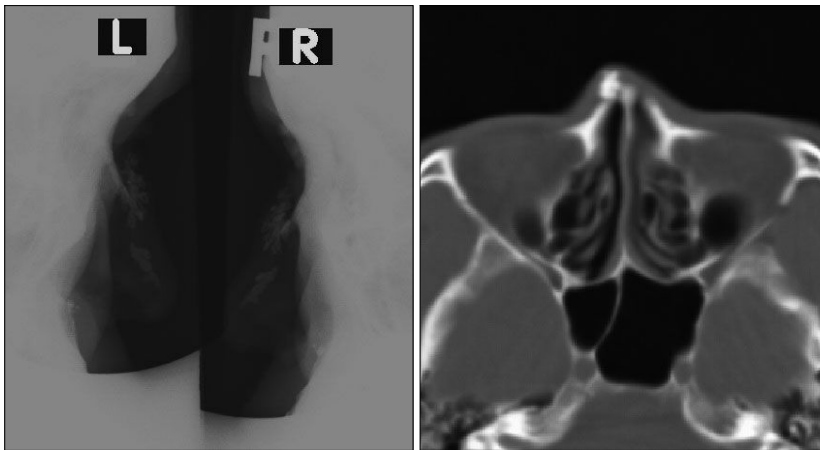


Fig. 2. Calcified soft tissue bulging, equivalent of bone density, above the intact nasal skeletal structure on nasal lateral view and computed tomographic finding.

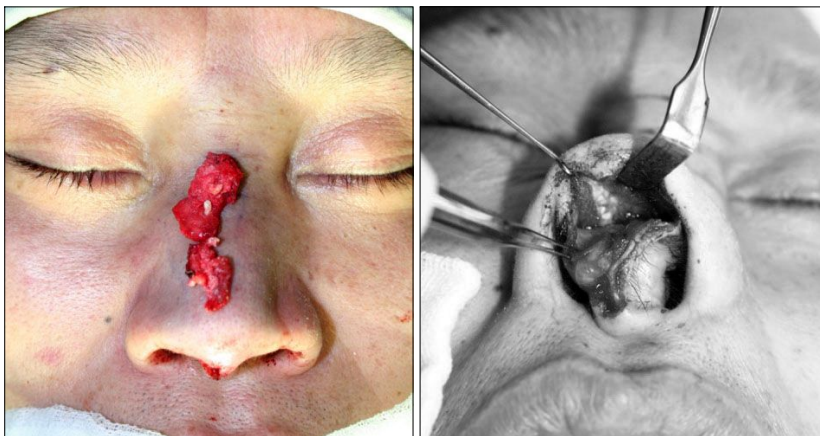


Fig. 3. Excised gross finding of a myositis ossificans in the operative field.

During the operation, the mass was found on the supra-periosteal plane intermingled with the nasalis muscle, probably the origin of the lesion. Pathologic report revealed focal mature bone tissue, compatible with the

myositis ossificans (Fig. 3).

In 2 years of follow-up, the patient is satisfied with a smooth nasal contour and no signs of recurrence had been noted.

III. DISCUSSION

Myositis Ossificans is a benign condition of heterotopic bone formation that remains difficult to distinguish between soft tissue and bone. It can be classified into three clinical varieties: myositis ossificans progressive (MOP), atraumatic myositis ossificans circumscripta (AMOS), and traumatic myositis ossificans circumscripta (TMOC).¹⁻³

Traumatic myositis ossificans circumscripta also called traumatic myositis ossificans, localized myositis ossificans or fibrodysplasia ossificans circumscripta is a disease in which muscles are ossified after trauma or inflammation.

An unknown mechanism and etiology of MOC involve proliferation of the mesenchymal tissue and metaplasia of the fibrous tissue, causing ossification after traumatic incident.^{1,3,5} Several opinions were reported. Few reports proposed theories that these lesions are implantation of

periosteum into muscle, escape of osteogenic cells from periosteum, ossification of a hematoma and metaplasia of connective tissue cells,^{1,3,4} following either acute macrotrauma or long periods of microtrauma. Saussez suggested this phenomenon to be a reparative, self-limited lesion occurring after tissue injury and necrosis, that the terminology of this entity, MOC, is misleading.⁵

The lesions are localized predominantly to the high-risk sites of injury,⁶ involving flexor muscles of the upper limbs and thigh, particularly the brachialis anterior and the quadriceps femori muscles.^{2,4} Even though head and neck area is common site of trauma, TMOC is rarely encountered in this area.^{2,4} Few cases reported in the head and neck area involves the masticatory. Other reported sites are the digastrics, temporalis, mylohyoid, buccinator, medial and lateral pterygoid, platysma, suprahyoid, sternocleidomastoid and scalenus medius muscle.¹ Most of the cases reported are found involving the masseter muscle, which is reasonable in sense that it covers the lateral side of the face and consist in bulk of muscle. However, TMOC of the pterygoid muscle is quite difficult to explain by simple trauma. Narang and Dixon speculated that it could have resulted from trauma during extraction of an impacted third molar and implantation of periosteum into the muscle.⁴ The TMOC of neck also occurred after application of a cervical collar to immobilize the neck, considered as a microtrauma.⁶ Another case reported also presents association with chronic, extensive pressure sore in patient with paraplegia secondary to spinal injury.⁷ It is interesting to find that in our case was located on nasal dorsum, the least amount of soft tissue and most susceptible site of facial injury. But there was no history of evident trauma, which makes this case even more unique if it was TMOC.

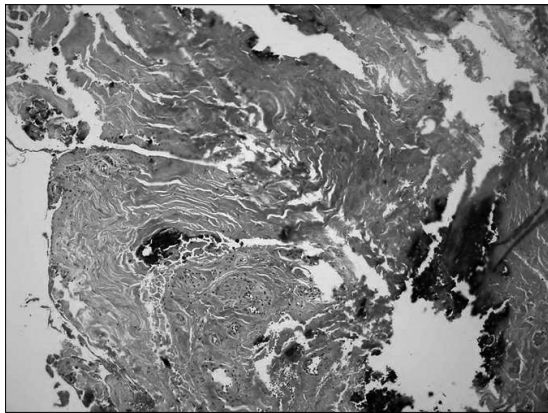


Fig. 4. Histopathologic report revealed woven bony structure with crowded myofibroblast (H-E stain × 40).

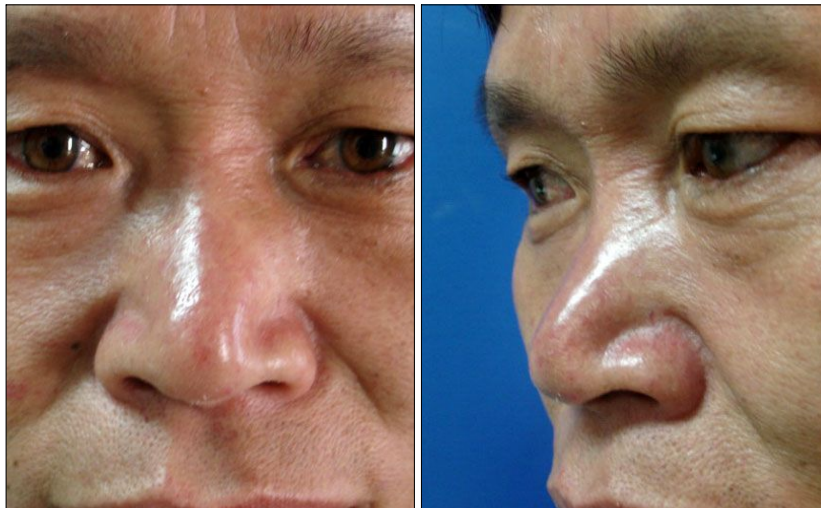

Fig. 5. Postoperative clinical photos at in 2 years show satisfying smooth nasal contour with no recurrence.

Clinical approach and diagnosis in such conditions is established by thorough history taking, appropriate imaging studies and most importantly by histopathologic finding. Because spontaneous regression can occur, some physicians are reluctant to surgical intervention.⁸ However, if the mass is gradually increasing in size, located in an unusual location or if it is compromising the cosmesis, surgical intervention may be required for diagnosis and treatment.^{2,3}

To our knowledge, the significance in this report is the first Myositis Ossificans developed in the nasal dorsum without evident trauma, which provides us with another unexplained prospective regarding pathogenesis of the disease.

REFERENCES

1. Takayuki A, Hiroyuki N, Yoshihide O, Kazuo S: Myositis ossificans traumatic of the masticatory muscles: review of the literature and report of a case. *J Oral Maxillofac Surg* 60: 1083, 2002
2. Sarac S, Sennaroglu L, Hosal AS, Sozeri B: Myositis ossificans in the neck. *Eur Arch Otorhinolaryngol* 256: 199, 1999
3. Mevio E, Rizzi L, Bernasconi G: Myositis ossificans traumatic of the temporal muscle: a case report. *Auris Nasus Larynx* 28: 345, 2001
4. Takahashi K, Sato K: Myositis ossificans traumatic of the medial pterygoid muscle. *J Oral Maxillofac Surg* 57: 451, 1999
5. Saussez S, Blaivie C, Lemort M, Chantrain G: Non-traumatic myositis ossificans in the paraspinal muscles. *Eur Arch Otorhinolaryngol* 263: 331, 2006
6. Baysal T, Baysal O, Sarac K, Elmali N, Kutlu R, Ersoy Y: Cervical myositis ossificans traumatic: a rare location. *Eur Radiol* 9: 662, 1999
7. Youn HS, Jang HJ, Hong IP, Kim JH: Myositis ossificans associated with pressure sore; a case report. *J Korean Soc Plast Reconstr Surg* 25: 1160, 1998
8. Yazici M, Etensel B, Gursoy MH, Aydogdu A, Erkus M: Nontraumatic myositis ossificans with an unusual location: case report. *J Ped Surg* 37: 1621, 2002