

## Case Report

# Leg Weakness in a Patient with Lumbar Stenosis and Adrenal Insufficiency

Kyoung-Tae Kim, M.D.,<sup>1</sup> Suk-Won Ahn, M.D.,<sup>2</sup> Jeong-Taik Kwon, M.D.,<sup>3</sup> Young-Baeg Kim, M.D.<sup>3</sup>

Department of Neurosurgery,<sup>1</sup> Kyungpook National University, Hospital, Daegu, Korea

Departments of Neurology,<sup>2</sup> Neurosurgery,<sup>3</sup> College of Medicine, Chung-Ang University, Seoul, Korea

Lumbar spinal stenosis (LSS) is a common spinal disease in the elderly. The cardinal symptom of LSS is neurogenic claudication, but not all patients present with such typical symptom. The clinical symptoms are often confused with symptoms of peripheral neuropathy, musculo-skeletal disease and other medical conditions in elderly patients. In particular, LSS presenting with rapid progression of leg weakness must be distinguished from other combined diseases. We report a case of rapid progressive leg weakness in a patient with LSS and iatrogenic adrenal insufficiency that was induced by obscure health supplement.

**Key Words :** Leg weakness · Lumbar spinal stenosis · Adrenal insufficiency.

## INTRODUCTION

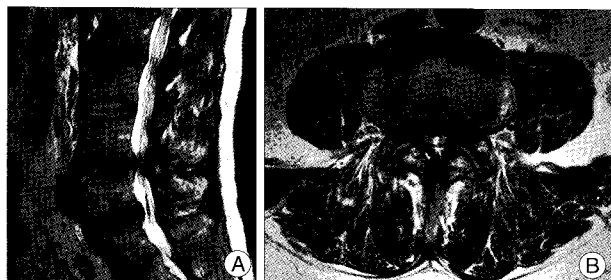
Lumbar spinal stenosis (LSS), first described by Verbiest in 1954<sup>13)</sup>, is widely diagnosed disease entity. Katz et al.<sup>8)</sup> reported that the more than 30,000 surgical procedures were performed in United States in 1994 to treat LSS. The rate of diagnosis is growing rapidly because of improvements in diagnostic imaging tools and surgical techniques, and the aging of the population<sup>4)</sup>. The cardinal symptom of LSS is neurogenic claudication, defined as pain in the buttocks and legs, and numbness or cramping of one or both legs induced by walking, which is relieved when sitting and bending forward<sup>11)</sup>. However, not all patients present with typical symptoms and clinical symptoms in elderly patients are often confused with symptoms of peripheral neuropathy, musculo-skeletal disease and other medical conditions<sup>4)</sup>. The decision to employ surgery must be made with caution in elderly patients with rapidly progressing leg weakness, because this condition rarely occurs in the absence of other combined conditions, and the incidence of combined disease in the elderly patients is high<sup>6,11)</sup>. We report a case of rapid progressive leg weakness in a patient with the LSS and iatrogenic adrenal insufficiency (AI).

## CASE REPORT

### Preoperative evaluation and operation

A 66-year-old male presented with rapidly progressing leg weakness and voiding difficulty, which had developed one month ago. He complained of chronic lower back pain and radiating pain in both legs, which had developed one year previously. Medical history revealed 10 years of treatment for hypertension and diabetes mellitus (DM). On physical examination, the patient appeared very tired and had moderate bilateral calf muscle atrophy. Neurological examination showed a leg motor power of grade IV/III+(right/left), with knee flexion and ankle dorsi-/plantar-flexion power of grade IV/III. Both knee and ankle reflexes were diminished without no long-tract signs. The patient's serum sodium level was 131 mEq/L (normal range : 135-146 mEq/L) and other laboratory findings were normal.

Magnetic resonance imaging (MRI) showed severe LSS at L4-5 (Fig. 1). Electromyography (EMG) and nerve conduction



**Fig. 1.** Sagittal (A) and axial (B) T2-weighted Lumbar MR images showing severe lumbar spinal stenosis at L4-5.

• Received : June 23, 2010 • Revised : August 5, 2010  
 • Accepted : March 27, 2011  
 • Address for reprints : Young-Baeg Kim, M.D.  
 Department of Neurosurgery, Chung-Ang University Hospital,  
 224-1 Heukseok-dong, Dongjak-gu, Seoul 156-755, Korea  
 Tel : +82-2-6299-1607, Fax : +82-2-821-8409  
 E-mail : ybkim1218@cau.ac.kr

velocity (NCV) showed bilateral L4, L5, S1 radiculopathy with mild DM neuropathy.

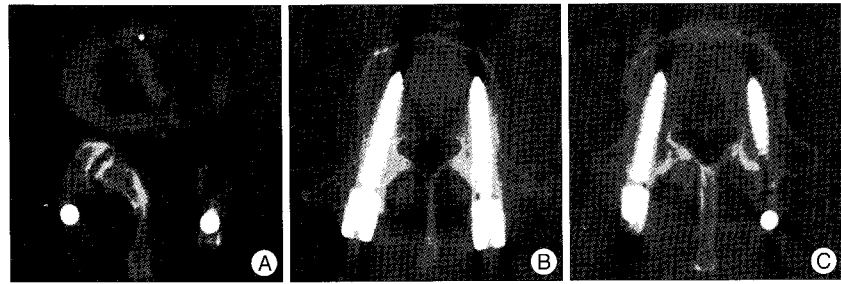
We concluded that the patient's main lesion was LSS and decided to proceed with a transforaminal lumbar interbody fusion (TLIF) via a left side approach. TLIF was performed successfully and postoperative CT showed well decompression of LSS and properly located pedicle screws (Fig. 2).

### Postoperative clinical course

At postoperative day 1 (POD #1), partial improvement was seen in radiating leg pain (visual analogue scale score decreased from 7 to 3), and leg weakness (grade IV/III increased to grade IV/IV), but the patient complained of general weakness with mild confusion. At POD #3, the patient could walk with maximal walker assistance, but could not void himself without Foley catheterization. At POD #7, he had a high fever with diarrhea and severe confusion, and was diagnosed with pseudomembranous colitis from a colonoscopy. At POD #12, the patient complained of general weakness with mild fever, and still had difficulty voiding without Foley catheterization. He had cystitis and the result of uro-dynamic study suggested a neurogenic bladder. The patient still could not walk without walker assistance. At POD #21, cystitis and colitis improved, but leg weakness (grade IV/IV) and voiding difficulty continued. At POD #27, general condition and leg weakness did not improve, and hyponatremia remained. Also, untreated blood pressure and sugar levels were lower limits of normal range. Because of the patient's odd medical conditions, we reviewed past medical history again and revealed that the patient had taken a health supplement for two years, and had stopped two months ago. We analyzed the health supplement and the result was surprising. The main component of the health supplement was glucocorticoid. The supplement had been purchased over the internet from foreign country. Serum cortisol level (0.52 µg/dL, normal range : 4.3-22.4), serum adrenocorticotropic hormone (ACTH) level (9.4 pg/mL, normal range : 10-60) and rapid ACTH stimulation test (moderate response) provided a diagnosis of severe secondary AI, which was treated immediately with glucocorticoid. General condition improved dramatically, with gradual improvement of leg weakness. Three days after medication, the patient could walk with a crutch, and void himself without Foley catheterization. Ten days after medication, he could walk independently and void normally. Twelve days after medication, the patient was discharged in good health. One year after operation, he can walk and void normally, but muscle atrophy is not recovered.

### DISCUSSION

LSS is a common spinal disease in the elderly and its symp-



**Fig. 2.** Postoperative Lumbar CT images showing well decompression and properly located pedicle screws at L4-5. A : L4-5 disc level. B : L4 pedicle level. C : L5 pedicle level.

toms may be confused with other conditions. Neurological deficits, such as leg motor weakness and cauda equina syndrome are not common in LSS patients, because neural compression is relieved by positional change<sup>6</sup>. In particular, the LSS symptom of rapidly progressing leg weakness must be distinguished from other causes, such as combined diseases or trauma<sup>4</sup>. In the case presented here, whole spine MRI and EMG/NCV showed LSS at L4-5 and radiculopathy in L4, L5, S1 with mild diabetic neuropathy, respectively. We supposed that LSS was the main cause of leg weakness and radiating pain, however we initially did not notice the use of a health supplement in the patient's medical history. Many people do not consider supplements to be medications and often take them without medical advice. This type of behavior has recently been worsened by the increased use of the internet market, which allows easy access to materials, foods and even drugs without detailed confirmation. This can be dangerous, because the components of some supplements are often not clear.

Some drugs, such as anticoagulants, fungal agents, phenobarbital, phenytoin, rifampin, imipramine, chlorpromazine, opiate drugs and glucocorticoid (systemic or topical), can induce primary or secondary AI<sup>1,2</sup>. In particular, excessive glucocorticoids have long been associated with risk of osteoporosis, or iatrogenic AI<sup>2,9,12</sup>. AI symptoms include general weakness, fatigue, nausea and vomiting, fever, dehydration, hypotension, hypoglycemia, hyponatremia, confusion, muscle weakness, shock and even death, induced by hypocortisolism. Cortisol has many important metabolic and endocrine functions that are essential for human survival, particularly during stress. Surgery, anesthesia, trauma, and severe illness, including infection, demand high cortisol level<sup>1,3</sup>. Surgery is a potent activator of the hypothalamus-pituitary-adrenal axis, and AI patients need adequate perioperative glucocorticoid coverage<sup>5,7,10</sup>. In case presented here, the patient was probably in a stage of hypocortisolism before TLIF surgery, which aggravated the hypocortisolism. Hypocortisolism also decreases the activation of the immune system<sup>1,3</sup>, which might have triggered pseudomembranous colitis and cystitis. These infections, in turn, would have re-aggravated the hypocortisolism. This vicious cycle corresponded to the clinical course, but leg weakness and radiating pain, and voiding difficulty showed somewhat different patterns. AI can present as muscle weakness, but in this case, the patient complained of

definite leg motor weakness. During four weeks after TLIF operation, the patient could not walk without walker assistance and void without Foley catheterization, even if the leg radiating pain and weakness partially improved (leg motor grade IV/III increased to grade IV/IV). We hypothesize that in this case, leg motor weakness and voiding difficulty, which were primarily affected by LSS, were more influenced by AI than other organs. Postoperative hypocortisolism might have delayed the recovery of the cauda equina syndrome at the operated lumbar lesion.

## CONCLUSION

This case highlights two basic medical principles. One is the importance of obtaining the detailed medical history. If we had performed a detailed history taking, including the use of health supplements, and AI had been properly treated with glucocorticoid before surgery or during surgery, we could have more safely performed the lumbar operation, and the patient might have followed rapid recovery without complications. The other principle is that decisions to proceed with surgery in elderly patients with rapid progressive leg weakness must be made with caution, because rapid progression of LSS is uncommon without special circumstance, and the incidence of combined disease in the elderly is relatively high.

## References

1. Arafah BM : Hypothalamic pituitary adrenal function during critical illness: limitations of current assessment methods. *J Clin Endocrinol Metab* 91 : 3725-3745, 2006
2. Bornstein SR : Predisposing factors for adrenal insufficiency. *N Engl J Med* 360 : 2328-2339, 2009
3. Coursin DB, Wood KE : Corticosteroid supplementation for adrenal insufficiency. *JAMA* 287 : 236-240, 2002
4. Egli D, Hausmann O, Schmid M, Boos N, Dietz V, Curt A : Lumbar spinal stenosis: assessment of cauda equina involvement by electrophysiological recordings. *J Neurol* 254 : 741-750, 2007
5. Fraser CG, Preuss FS, Bigford WD : Adrenal atrophy and irreversible shock associated with cortisone therapy. *J Am Med Assoc* 149 : 1542-1543, 1952
6. Ghanayem AJ : Clinical presentation and diagnosis, in Frymoyer JW WS (ed) : *The adult & pediatric spine*, ed 3. Philadelphia : Lippincott Williams & Wilkins, 2004, pp955-957
7. Jabbour SA : Steroids and the surgical patient. *Med Clin North Am* 85 : 1311-1317, 2001
8. Katz JN, Lipson SJ, Chang LC, Levine SA, Fossel AH, Liang MH : Seven- to 10-year outcome of decompressive surgery for degenerative lumbar spinal stenosis. *Spine (Phila Pa 1976)* 21 : 92-98, 1996
9. Khosla S, Lufkin EG, Hodgson SF, Fitzpatrick LA, Melton LJ 3rd : Epidemiology and clinical features of osteoporosis in young individuals. *Bone* 15 : 551-555, 1994
10. Lewis L, Robinson RF, Yee J, Hacker LA, Eisen G : Fatal adrenal cortical insufficiency precipitated by surgery during prolonged continuous cortisone treatment. *Ann Intern Med* 39 : 116-126, 1953
11. Porter RW : Spinal stenosis and neurogenic claudication. *Spine (Phila Pa 1976)* 21 : 2046-2052, 1996
12. Reynolds RM, Dennison EM, Walker BR, Syddall HE, Wood PJ, Andrew R, et al. : Cortisol secretion and rate of bone loss in a population-based cohort of elderly men and women. *Calcif Tissue Int* 77 : 134-138, 2005
13. Verbiest H : A radicular syndrome from developmental narrowing of the lumbar vertebral canal. *J Bone Joint Surg Br* 36B : 230-237, 1954