

## Simultaneous Aortic and Tricuspid Valve Endocarditis due to Complication of Sinus of Valsalva Rupture

Tae-Eun Jung, M.D.\*, Jung-Hee Kim, M.D.\*, Hyung-Dong Do, M.D.\*, Dong-Hyup Lee, M.D.\*

We experienced a case of ruptured aneurysm of the sinus of Valsalva, and this resulted in simultaneous aortic and tricuspid valve endocarditis through a shunt. The echocardiography showed a ruptured sinus of Valsalva aneurysm to the right atrium with a shunt. The aortic non-coronary cusp was fibro-thickened with vegetation. Vegetations of the septal leaflet and the anterior leaflet of the tricuspid valve were also found. The blood culture grew *Enterococcus gallinarum*. We replaced both tricuspid and aortic valve with successful surgical result.

Key words: 1. Endocarditis  
2. Aortic valve  
3. Tricuspid valve  
4. Sinus of Valsalva  
5. Rupture

### CASE REPORT

A 49-year-old man, who had been admitted to a sanatorium 20 years earlier due to schizophrenia, visited our emergency room with cough, dyspnea, and high fever from which he had been suffering for 1 week. Upon physical examination, a grade IV/VI continuous murmur was heard at the third intercostal space along the left sternal border. His blood pressure was 120/40 mmHg and his heart rate was 110 beats/min. Chest radiography showed an enlarged heart, pulmonary congestion, and bilateral pleural effusion. Two-dimensional echocardiography showed a ruptured sinus of Valsalva aneurysm in the right atrium with a left to right shunt (Qp/Qs=2.6). The aortic regurgitation was trivial, and the non-coronary cusp was fibro-thickened with vegetation (size=1.3×0.7 cm) (Fig. 1). The tricuspid valve regurgitation was

grade II/IV, and the pulmonary artery pressure was moderately elevated. Multiple vegetations of the septal and anterior leaflet (size=1.2×0.5 cm) of the tricuspid valve were found. The blood culture grew *Enterococcus gallinarum* and the patient was treated with linezolid. As he had malnutrition and showed signs of heart failure, surgery was deferred for a week, during which he was given nutritional support and medication, including antibiotics. After a week of medical treatment, his medical condition improved and elective surgery was performed. During surgery, the non-coronary sinus of Valsalva was aneurysmal, vegetated, and the diameter of the ruptured opening was 0.8 cm. The tricuspid valve was also fibro-thickened and multiple vegetations were attached to the margin of the septal and whole anterior valve leaflets, extending to the chordae. The ruptured opening of the sinus of Valsalva was repaired with a polytetrafluoroethylene patch

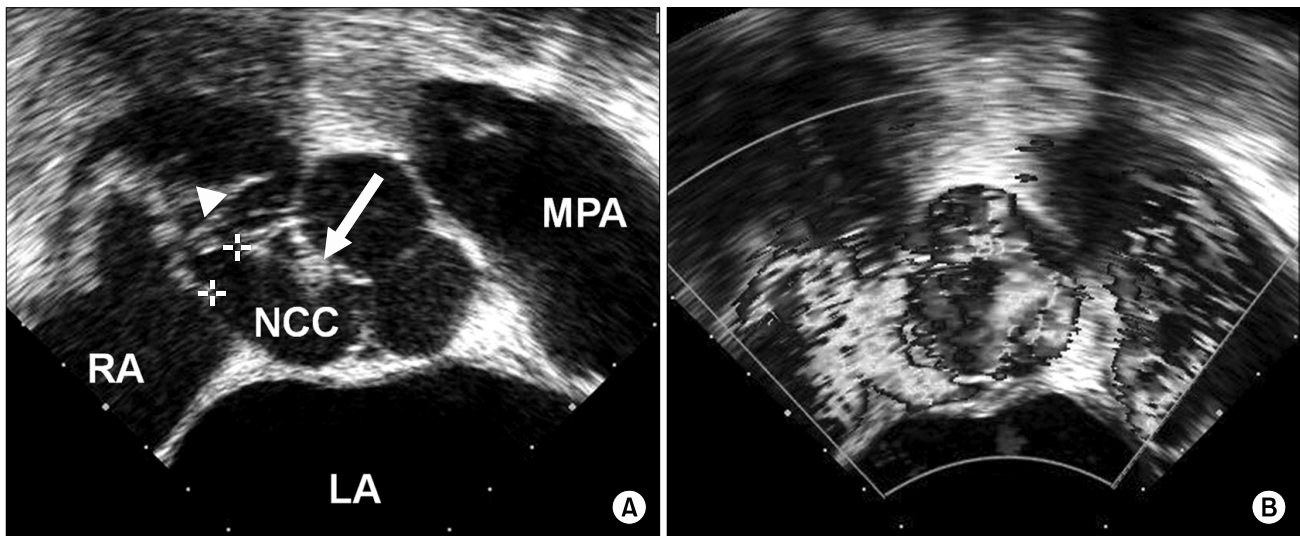
\*Department of Thoracic and Cardiovascular Surgery, College of Medicine, Yeungnam University

Received: December 27, 2010, Revised: April 1, 2011, Accepted: May 10, 2011

Corresponding author: Dong-Hyup Lee, Department of Thoracic and Cardiovascular Surgery, College of Medicine, Yeungnam University, 317-1, Daemyeong 5-dong, Nam-gu, Daegu 705-717, Korea  
(Tel) 82-53-620-3883 (Fax) 82-53-626-8660 (E-mail) dhlee@med.yu.ac.kr

© The Korean Society for Thoracic and Cardiovascular Surgery. 2011. All right reserved.

© This is an open access article distributed under the terms of the Creative Commons Attribution Non-Commercial License (<http://creativecommons.org/licenses/by-nc/3.0>) which permits unrestricted non-commercial use, distribution, and reproduction in any medium, provided the original work is properly cited.



**Fig. 1.** Short-axis view of the aortic valve showing a ruptured aneurysm of the non-coronary sinus of Valsalva protruding into the right atrium with aortic valve vegetation (arrow) and tricuspid valve vegetation (arrow head) (A). Color Doppler showing the turbulent flow from the aorta to the right atrium through the perforation (B). RA=Right atrium; LA=Left atrium; NCC=Non-coronary cusp; MPA=Main pulmonary artery.

through the aorta. Both valves were widely resected and replaced with tissue valves (aortic valve; Hancock II-25 mm, tricuspid valve; Hancock II-31 mm, Medtronic, Minneapolis, MN). The patient had no perioperative complications. He continued to receive antibiotics for 4 weeks during hospitalization. There was no residual shunt through the repaired sinus of Valsalva and both valves were functioning well at follow-up echocardiography. During a follow-up period of 2 years, the patient was doing well without recurrence of endocarditis.

## DISCUSSION

Ruptured aneurysm of the sinus of Valsalva is a rare heart disease. Most cases originate from the right coronary sinus (65~85%), followed by the non-coronary sinus (10~30%), rarely originating from the left coronary sinus (<5%). The right ventricle is the most common receiving chamber. The hemodynamic consequences of a ruptured sinus of Valsalva depend on the rapidity of the rupture, the size of the ruptured orifice, and which chamber is involved.

Intracardiac shunt disease such as a ventricular septal defect or a ruptured sinus of Valsalva may give rise to infective endocarditis [1]. Clinical manifestations complicated by both

a ruptured sinus of Valsalva and tricuspid endocarditis have been reported [2-4]. However, endocarditis of both valves occurring in a single patient has rarely been reported. We reported here on a case of a ruptured aneurysm of the sinus of Valsalva that resulted in simultaneous aortic and tricuspid valve endocarditis through a shunt. We believe that the ruptured aneurysm of the sinus of Valsalva with fistulous formation may have predisposed the patient to endocarditis of the aortic valve; subsequently, tricuspid valve endocarditis developed.

Tricuspid valve repair seemed impossible due to extensive leaflet and sub-valvular involvement. Our patient suffered from schizophrenia and cachexia. We decided to implant tissue valves instead of mechanical valves due to the difficulty of performing anticoagulation.

We experienced a case of infective endocarditis of the aortic and tricuspid valves complicated by a ruptured sinus of Valsalva aneurysm. The patient was successfully treated with surgery and was transferred back to the sanatorium where he was previously staying.

## REFERENCES

1. Akowuah EF, Casula R, Thanos A, Cooper GJ. *Aorto-right*

Tae-Eun Jung, et al

- atrial fistula associated with native tricuspid valve endocarditis.* J Cardiovasc Surg (Torino) 2002;43:841-2.
2. Kuvin J, Vannan M, Corrodi G, Warner K, Bojar R, Pandian NG. *Ruptured sinus of Valsalva aneurysm simulating endocarditis.* J Am Soc Echocardiogr 1997;10:756-9.
  3. Ott DA. *Aneurysm of the sinus of valsalva.* Semin Thorac Cardiovasc Surg Pediatr Card Surg Annu 2006;165-76. Review.
  4. Sugimoto T, Ogawa K, Asada T, et al. *Surgical treatment of ventricular septal defect and ruptured sinus of Valsalva associated with infective endocarditis.* Cardiovasc Surg 1994;2: 470-3.