

Cystic Adventitial Disease of the Popliteal Artery: Resection and Repair with Autologous Vein Patch

Young-Hee Maeng, M.D.*, Jee Won Chang, M.D.**, Sun Hyung Kim, M.D.***

Cystic adventitial disease is rare, but it is one of the well-recognized causes of non-atherosclerotic arterial stenosis or obstruction. Despite one of its most common symptoms being chronic intermittent claudication, it may be misdiagnosed as arterial embolism when presented with acute ischemic symptoms. Surgical resection is recommended because of recurrence or a low success rate with aspiration or endovascular stent. We performed resection and repair with autologous vein patch for cystic adventitial disease of the popliteal artery of a 57-year-old man presenting with pain, pallor, and paresthesia, without any postoperative complications or recurrence.

Key words: 1. Vascular disease
2. Cysts

CASE REPORT

A 57-year-old man was referred to our department because of a recent aggravation of sensations of coldness, tingling, and pain in the right leg. He had right calf pain for 4 months, which was exacerbated by walking a distance of 500 meters, and occasional nocturnal stabbing leg pain for 1 month. The symptoms described aggravated suddenly 4 days before presentation. He had a medical history of hypertension and operation for a soft tissue mass in the medial side of right knee. He had no other vascular risk factors such as diabetes or smoking. Physical examination revealed pallor, poikilothermia, decreased sensitivity on the pin prick test, and no palpable pulse below the popliteal artery. He had no remarkable findings in CBC and chemistry except for an elevated AST of 78 IU/L (reference value 8~38 IU/L). CT angiog-

raphy showed severe narrowing of the right popliteal artery, which was compressed by a multi-loculated cystic mass with a largest diameter of 3 cm (Fig. 1). We decided to perform a surgical resection of the lesion because we were concerned about fracturing of the endovascular stent in the frequently bent area.

Under spinal anesthesia he was positioned prone for a posterior approach. When the popliteal artery was exposed, a cystic mass filled with a jelly-like material encased the artery. Pulse was palpable in the proximal part of mass but not in the distal part. In order to facilitate the dissection and make the relationship between mass and arterial lumen clear, vertical arteriotomy was performed after applying proximal and distal vascular clamps. The lumen was intact without thrombus or any endoluminal irregularity (Fig. 2). Complete excision and arterial repair with autologous vein patch was

*Department of Pathology, Jeju National University Hospital

**Department of Thoracic and Cardiovascular Surgery, Jeju National University Hospital

***Department of Laboratory Medicine, Jeju National University Hospital

Received: November 15, 2010, Revised: December 29, 2010, Accepted: May 10, 2011

Corresponding author: Jee Won Chang, Department of Thoracic and Cardiovascular Surgery, Jeju National University Hospital, 1753-3, Ara 1-dong, Jeju 690-121, Korea

(Tel) 82-64-717-1704 (Fax) 82-64-717-1131 (E-mail) jeewon71@naver.com

© The Korean Society for Thoracic and Cardiovascular Surgery. 2011. All right reserved.

© This is an open access article distributed under the terms of the Creative Commons Attribution Non-Commercial License (<http://creativecommons.org/licenses/by-nc/3.0>) which permits unrestricted non-commercial use, distribution, and reproduction in any medium, provided the original work is properly cited.

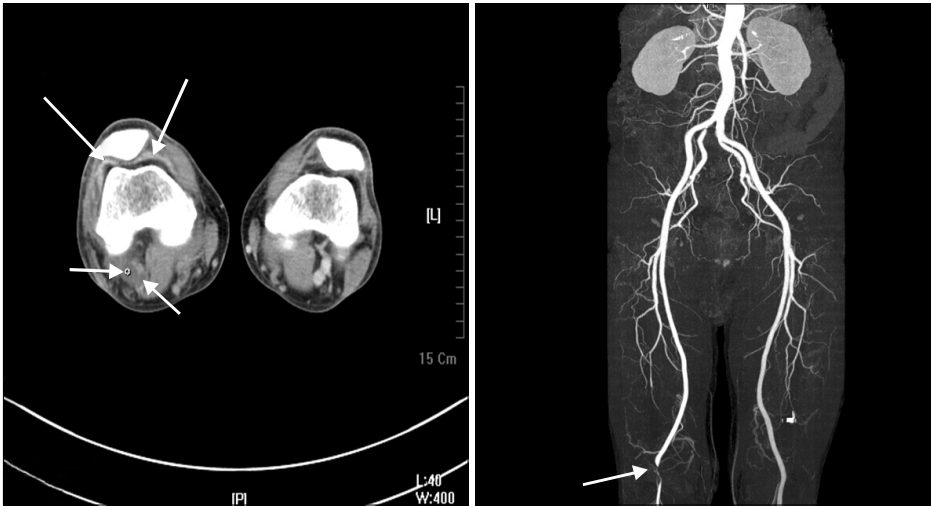

Fig. 1. CT angiography shows that a multi-loculated cystic mass nearly obstructing the popliteal artery and cysts in the synovial area (arrows).

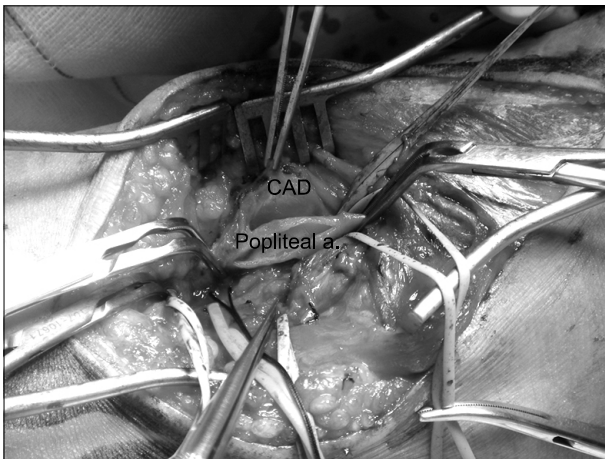


Fig. 2. Intraoperative photograph shows the clear lumen of the popliteal artery and the surrounding cystic mass (CAD=Cystic adventitial disease; Popliteal a.=Popliteal artery).

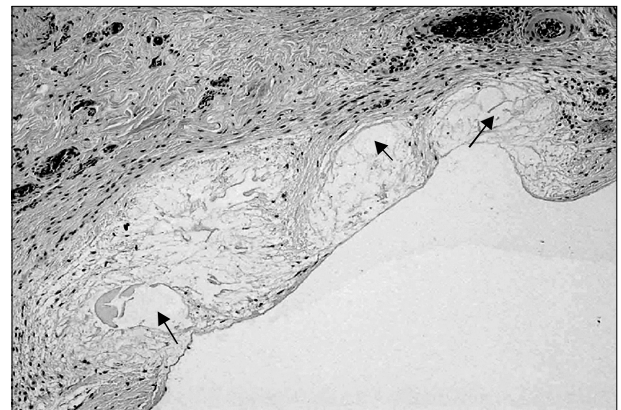


Fig. 3. Histologic findings show multiple foci (arrows) of mucinous degeneration in the wall (H&E, ×100).

done to prevent stenosis of the arteriotomy site. Pathologic findings confirmed cystic adventitial disease (CAD), based on the presence of multiple mucinous foci of degeneration in the vascular wall (Fig. 3).

He was discharged on the fifth postoperative day, but continued to complain of paresthesia during outpatient follow-up. On the postoperative CT angiography, arterial patency was well-maintained without any evidence of recurrence. Paresthesia gradually improved with symptomatic treatment for neuropathic pain and finally disappeared on the sixth postoperative month.

DISCUSSION

CAD is so rare a disorder that less than 400 cases have been reported in the literature [1]. The first case of CAD involved external iliac artery and was reported by Atkins and Keys in 1947 [2]. Because CAD is commonly presented with intermittent claudication, popliteal artery entrapment syndrome, Buerger's disease, and popliteal artery aneurysm should be differentiated. However, CAD usually develops in young and middle-aged men without evidence of atherosclerosis. In some cases, the symptoms have a sudden onset and have a short duration of days to weeks rather than years. Therefore, CAD should also be differentiated from the diseases causing acute ischemia. The disease mainly affects pop-

liteal arteries (about 85% of cases) and, more rarely, the common femoral, external iliac, radial, and ulnar arteries [3]. Ischemic neuropathic symptoms such as burning pain, coldness, or paresthesia may be present. Sustained ischemic neuropathic symptoms after revascularization were noted in this case. If the arterial patency is confirmed by radiologic studies during postoperative follow-up, pain-relieving medication and close observation could be sufficient to address residual symptoms.

The etiology of CAD remains to be elucidated, but four hypotheses have been proposed [4]. The trauma theory suggests chronic degeneration by repetitive trauma. The ganglion theory assumes that synovial cysts, which track along vascular branches, are finally settled in the adventitia of major vessels. In the systemic disorder theory, CAD is considered to be the result of generalized connective tissue disorders. Lastly, the developmental theory suggests that mucin-secreting mesenchymal cells from nearby joints erroneously migrate to adjacent adventitia during the embryogenesis period. The patient in this case study showed cysts in the CT angiography of the knee joint at the time of diagnosis in addition to a history of resection for a soft tissue mass in the nearby joint area. Such findings favor the ganglion theory and the developmental theory.

Treatment options for CAD have been described, including percutaneous aspiration, open incision and cyst enucleation, endovascular stent insertion, excision of the cyst with autologous vein graft reconstruction, and bypass surgery [5]. Percutaneous aspiration is not effective in most of the cases because the content of the cyst is viscous, consisting of mucoproteins and mucopolysaccharides. Endovascular stent

placement is generally not advised because CAD patients are often young and stenting of the popliteal artery is not a durable therapy, due to intimal hyperplasia or stent fracture. In addition, stenting across joints is generally avoided. Though successful percutaneous transluminal angioplasty [6] and even spontaneous resolution of CAD has been reported [7], such experiences are limited and surgical resection is generally considered to be an acceptable treatment.

In summary, we successfully treated CAD with complete resection and autologous vein patch repair without any complications.

REFERENCES

1. Meka M, Hamrick MC, Wixon CL. *Cystic adventitial disease of the popliteal artery: a potential cause of the lower extremity claudication*. Am Surg 2009;75:86-9.
2. Atkins HJB, Key JA. *A case of myxomatous tumor arising in the adventitia of the left external iliac artery*. Br J Surg 1947;34:426.
3. Tsilimparis N, Hanack U, Yousefi S, Alevizakos P, Ruckert RI. *Cystic adventitial disease of the popliteal artery: an argument for the developmental theory*. J Vasc Surg 2007;45:1249-52.
4. Levien LJ, Benn CA. *Adventitial cystic disease: a unifying hypothesis*. J Vasc Surg 1998;28:193-205.
5. Cassar K, Engeset J. *Cystic adventitial disease: a trap for the unwary*. Eur J Vasc Endovasc Surg 2005;29:93-6.
6. Ismaeel MM, Irving LK, Klause DH. *Recurrent cystic adventitial disease of the popliteal artery: successful treatment with percutaneous transluminal angioplasty*. Vasc Endovascular Surg 2009;43:399-402.
7. Pursell R, Torrie EPH, Gibson M, Galland RB. *Spontaneous and permanent resolution of cystic adventitial disease of the popliteal artery*. J R Soc Med 2004;97:77-8.