大韓獸醫學會誌(2011) 第51卷 第2號
Korean J Vet Res(2011) 51(2) : 83~91

<원 저>

Changes of colonic endocrine cells in trinitrobenzene sulfonic acid (TNBS)-induced rat colitis

Young-Doo Back[1], Hyeung Sik Lee[2], In-Kwon Chung[3], Woo-Hyun Cheon[4], Sae Kwang Ku[5,*]

[1]Laboratory of Clinical Laboratory Science, Oriental Hospital, Gyeongsan 712-715, Korea
Departments of [2]Clinical Laboratory Science, [3]Internal Medicine, [4]Neurology, and [5]Anatomy and Histology, College of Oriental Medicine, Daegu Haany University, Gyeongsan 712-715, Korea
(Accepted: June 13, 2011)

Abstract : In this study, immunohistochemistry was used to examine the changes in the density of colonic endocrine cells - argyrophil and argentaffin cells, chromogranin A (CGA), serotonin, somatostatin and glucagon-containing cells in trinitrobenzene sulfonic acid (TNBS)-induced rat colitis. Ulcerative colitis was induced by the instillation of 10 mg of TNBS into the colonic lumen through the anus. To confirm the inducement of ulcerative colitis, the macroscopic and microscopic scores as well as the colonic myeloperoxidase (MPO) activities were monitored for 8 days after TNBS instillation in the colonic lumens. In addition, the number of argyrophil and argentaffin cells, CGA, serotonin, somatostatin and glucagon-immunoreactive cells were counted in the colonic mucosa, respectively. After TNBS instillation into the lumen of the colon from the anus in rats, increases in macroscopic and microscopic scores in the colon tissues were observed along with increases in the colonic MPO activities. Therefore, ulcerative colitis was relatively well induced by the TNBS instillations. Marked decreases in the number of colonic endocrine cells were detected in the TNBS-treated animal compared to the sham control. These results suggest that colonic endocrine cells were also disrupted by TNBS-induced ulcerative colitis.

Keywords : colitis, colon, endocrine cells, immunohistochemistry, TNBS

Introduction

Inflammatory bowel disease, which includes ulcerative colitis and Crohn's disease, is a chronic relapsing and nonspecific inflammatory disorder in the gastrointestinal (GI) tract, ultimately giving rise to mucosal disruption and ulceration [36]. Generally, ulceration, mucus cell depletion, inflammatory cell infiltration and edematous changes can be induced by a treatment with 2,4,5-trinitrobenzene sulfonic acid (TNBS), a well established model of intestinal inflammation with some resemblance to human inflammatory bowel disease mediated by reactive oxygen species [14, 16]. This animal model has been used as a valuable animal model for the development of potent therapeutic agents to inflammatory bowel disease [31].

Inflammatory processes in the GI tract not only affect the mucosa and submucosa, but also disturb the other components, such as the contractile response of its neuromuscular layers mediated by changes in the neurotransmitters in TNBS-induced rabbit colitis [4, 5]. Moreover, the possible involvement of GI endocrine cells in the clinical symptoms of inflammatory bowel diseases has been suggested [8, 21, 26]. In addition, reactive oxygen species can easily disturb the GI endocrine cells [23], and the changes in GI endocrine cells in some diseases have been demonstrated in diabetes [9], pernicious anemia [29], celiac sprue [2], osteoporosis [18] and tumors [19]. Therefore, the density of colonic endocrine cells is also changed in inflammatory bowel disease possibly mediated by oxidative stress in TNBS-induced colitis. These changes can induce a range of clinical symptoms related to the physiological functions of hormones released by endocrine cells.

This study examined the changes in the density of colonic endocrine cells - argyrophil and argentaffin cells, chromogranin A (CGA), serotonin, somatostatin and

*Corresponding author
Tel: +82-53-819-1549, Fax: +82-53-819-1269
E-mail: gucci200@hanmail.net

glucagon-containing cells in TNBS-induced rat colitis using immunohistochemistry, to confirm the relationship between the colonic endocrine cell density and colitis.

Materials and Methods

Animals and husbandry

Fourteen male Sprague-Dawley rats (160~180 g, 6-week old upon receipt; SLC, Japan) were used in this study after allowing 7 days of acclimatization. The animals were allocated to three or four per polycarbonate cage in a temperature (20~25°C) and humidity (40~45%) controlled room. The light : dark cycle was 12 h : 12 h and normal rodent pellet diet and water were supplied free to access throughout all the experimental periods including acclimatization. Ulcerative colitis was induced by TNBS instillation in 7 rats. The remaining 7 rats were used as the sham control. All animals were treated in accordance with the Guidelines for the Care and Use of Laboratory Animals of Daegu Haany University, Korea.

Induction of ulcerative colitis

Colitis was induced using the procedure described by Morris *et al.* [22]. Briefly, the rats were lightly anesthetized with ether after a 24 h fast, and a medical-grade polyurethane cannula for enteral feeding (external diameter 2 mm) was inserted into the anus. The tip was advanced 8 cm proximal to the anal verge. 10 mg/kg of TNBS (Sigma, USA), dissolved in 50% ethanol was instilled into the colon through the cannula to induced ulcerative colitis. After instillation of the hapten, the animals were maintained in a head-down position for a few minutes to prevent leakage of the intracolonic instillate. In the sham control, physiological saline was instilled instead of the TNBS solution.

Macroscopic scoring

All animals were sacrificed 8 days after the TNBS treatment. The distal 12 cm of the colon was excised free of adherent adipose tissue, rinsed with ice-cold saline and opened longitudinally. The excised colon was examined visually immediately and the level of damage was scored on a scale of 0~5 [22]. The scoring of macroscopic colon damage in TNBS-induced colitis was as follows: (0) no colonic damage; (1) hyperaemia and no ulcers; (2) linear ulcers and no colonic wall thickening; (3) linear ulcers and colonic wall thickening in one area; (4) colonic ulcers at multiple areas; and (5) major ulcers and perforation.

Measurement of MPO activity

The MPO activity was assessed as a marker of neutrophil infiltration using the method reported by Grisham *et al.* [12]. In all animals, one sample from the distal colon was obtained. The samples were excised from each animal and rinsed rapidly with ice-cold saline, blotted dry, and frozen at –70°C. The tissue was later thawed, weighed and homogenized in 10 volumes 50 mM PBS (pH 7.4). The homogenate was centrifuged at 20,000 × g, 20 min, 4°C. The pellet was again homogenized in 10 volumes of 50 mM PBS (pH 6.0), containing 0.5% hexadecyl-trimethylammonium bromide (HETAB; Sigma, USA) and 10 mM ethylenediamine tetraacetic acid (EDTA; Sigma, USA). This homogenate was subjected to one cycle of freezing/thawing and a brief period of sonication. One sample of the homogenate (0.5 L) was added to a 0.5 mL reaction volume containing 80 mM PBS (pH 5.4), 0.5% HETAB and 1.6 mM 3,3,5,5-tetramethylbenzidine (TMB). The mixture was incubated at 37°C for 5 min and the reaction was started by the addition of 0.3 mM H_2O_2. Each tube containing the complete reaction mixture was incubated for precisely 3 min at 37°C. The reaction was terminated by the sequential addition of catalase (20 μg/mL) and 2 mL 0.2 M sodium acetate (pH 3.0). The changes in the absorbance at 655 nm were measured using a spectrophotometer. One unit of the MPO activity was defined as the amount of enzyme present that produced a change in absorbance of 1.0 U/m at 37°C in the final reaction volume containing sodium acetate. The results are expressed as U/mg tissue protein.

Histopathology

The approximated regions of the individual colon were sampled, and crossly trimmed based on the lumen. All trimmed colons were fixed in 10% neutral buffered formalin. After paraffin embedding, 3~4 μm sections were prepared. The representative sections were stained with hematoxylin and eosin (H&E) for the optical microscopy examination. Subsequently, the histological profiles of the individual cross trimmed colon were observed. The histological damage to the prepared cross trimmed H&E stained samples was evaluated by two pathologist observers, who were blinded to the experimental groups, according to the modified criteria from Stucchi *et al.* [35] and Peran *et al.* [24]. Briefly, the mucosal epithelial ulceration, crypts mitotic activity and mucous cell depletion, lamina propria inflammatory cell infiltration,

vascularity and collagen depositions, submucosal inflammatory cell infiltration, vascularity, collagen depositions and edema were scored as 0~3 degrees and totalized (maximum score, 30).

Histochemistry

Grimelius staining for argyrophil cells [11] and Masson-Hamperl staining for argentaffin cells [33] were conducted to observe the regional distribution and frequency of argyrophil and argentaffin endocrine cells in colon mucosa. The numbers of argyrophil and argentaffin cells were calculated in 1 mm^2 of mucosal regions using an automated image analyzer. Briefly, for argyrophil staining, the sections were incubated in a silver solution (1% silver nitrate 4 mL, 0.2 M acetate buffer (pH 5.6) 10 mL, distilled water 86 mL) at 60°C for 3 h, and then treated with a preheated reducer (hydroquinone 1 g, sodium sulphate 5 g, distilled water 100 mL) for 1 min at 45°C. For argentaffin staining, sections were incubated in a preheated silver solution (10% aqueous silver nitrate added strong ammonia dropping) at 60°C for 30 min in the dark, and then treated with a 1% sodium thiosulphate solution for 30 sec. The number of positive cells was calculated in 1 mm^2 of the mucosal regions using an automated image analyzer (DMI, Korea).

Immunohistochemistry

Each representative section was deparaffinized, rehydrated and immunostained using the peroxidase-anti peroxidase method [34]. Blocking of the nonspecific reaction was performed with normal goat serum prior to incubation with the specific antisera, polyclonal CGA (dilution 1 : 100; DAKO, USA), serotonin (dilution 1 : 20; BioGenex, USA), somatostatin (dilution 1 : 100; DAKO, USA) or glucagon (dilution 1 : 2,000; Diasorin, USA). After rinsing in phosphate buffered saline (PBS; 0.01 M, pH 7.4), the sections were incubated with secondary antiserum. They were then washed in PBS buffer and the peroxidase-anti peroxidase complex was prepared. The peroxidase reaction was carried out in a solution of 3,3′-diaminobenzidine tetrahydrochloride containing 0.01% H_2O_2 in Tris-HCl buffer (0.05 M, pH 7.6). After immunostaining, the sections were lightly counterstained with Mayer's hematoxylin, and the immunoreactive cells were observed by optical microscopy. The specificity of each immunohistochemical reaction was determined, as recommended by Sternberger [34], including the replacement of specific antiserum by the same antiserum, which had been preincubated with its corresponding antigen - CGA, serotonin, somatostatin or glucagon. The number of immunoreactive cells was calculated in 1 mm^2 of the mucosal regions using an automated image analyzer.

Table 1. Macroscopic and microscopic scores with the colonic MPO activities

Criteria \ Groups	Sham control	TNBS-treated
Totalized macroscopic scores (Max = 5)		
	0.43 ± 0.53	4.29 ±0.76[a]
Totalized microscopic scores (Max = 30)		
	2.43 ±1.40	21.43 ±0.98[a]
MPO activities (U/mg tissue)		
	5.22 ±0.88	9.35 ±1.25[a]

Values are expressed as the mean ±SD of seven rats.
MPO: myeloperoxidase, TNBS: trinitrobenzene sulfonic acid.
[a]$p < 0.01$ as compared with sham control.

Statistical analyses

The data was analyzed using a Mann-Whitney U test. Statistical analyses were conducted using SPSS for Windows (Release 12.0K; SPSS, USA). A p-value < 0.05 was considered significant.

Results

Changes on the macroscopic scores

Significant ($p < 0.01$) increases in the macroscopic colon damage scores were detected in the TNBS-treated animal as compared to the sham control in the present study. About 10-fold higher macroscopic scores were detected in TNBS control as increased as compared to the sham control (Table 1).

Changes on the colonic MPO levels

Significant ($p < 0.01$) increases in the MPO levels in the colon were detected in the TNBS-treated animal compared to the sham control. About 2-fold higher MPO levels were observed in TNBS control as increased as compared to the sham control (Table 1).

Histopathological changes of colons

Ulcerative colitis histopathological changes - ulceration, mucus cell depletion, inflammatory cell infiltration, neovascularization, collagen depositions (fibrosis) and

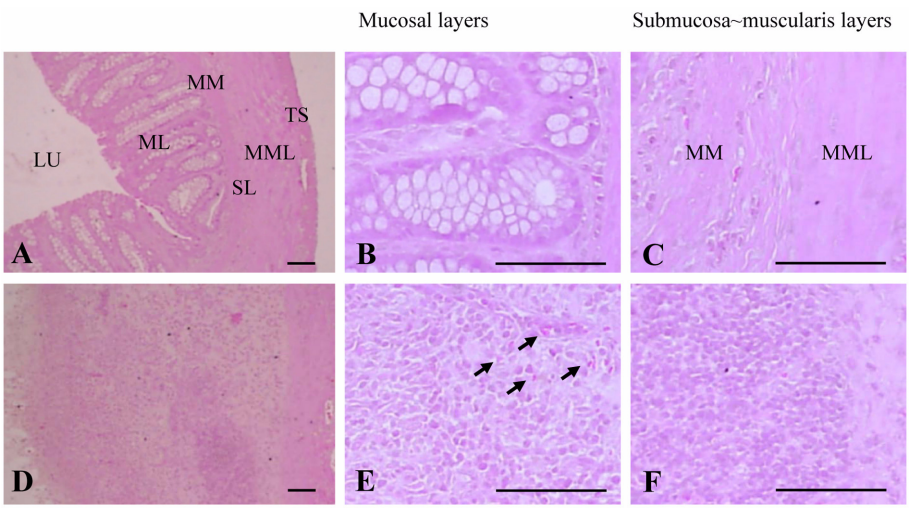

Fig. 1. Representative histopathological profiles of the colon of the sham control (A~C) and TNBS-treated (D~F) groups. Note that ulceration, mucus cell depletion, inflammatory cell infiltration, neovascularization (arrows) and edematous changes were detected in the TNBS-treated animals compared to the intact control. LU: lumen, ML: mucosa layer, MM: muscularis mucosa, SL: submucosa layer, MML: muscle layer, TS: tunica serosa. H&E stain. Scale bars = 80 μm.

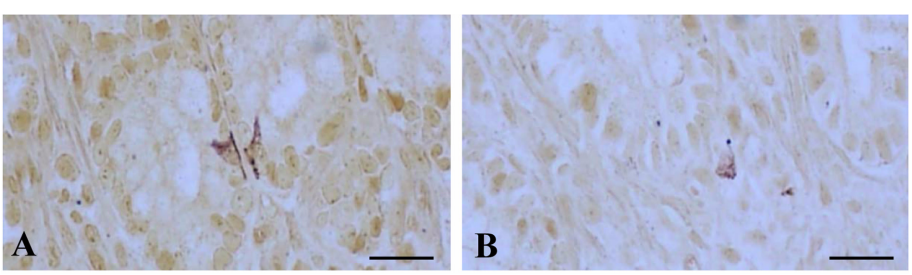

Fig. 2. Representative argyrophil endocrine cells in the colon of the sham control (A) and TNBS (B)-treated groups. Note that marked decreases in the number of colonic argyrophil cells were detected in the TNBS-treated animals compared to the sham control. Grimelius stain. Scale bars = 320 μm.

edematous changes, were detected in the TNBS-treated animal compared to the sham control (Fig. 1). In addition, significant ($p < 0.01$) increases in the totalized microscopic scores were detected in the TNBS-treated animal compared to the sham control (Table 1). About 9-fold microscopic scores were observed in TNBS control as increased as compared to the sham control in the present study.

Changes of the colonic endocrine cells

Argyrophil and argentaffin cells were dispersed throughout the entire colonic mucosa, located mainly in the intestinal glands regions. Similar to those of the argyrophil and argentaffin cells, CGA, serotonin, somatostatin and glucagon-immunoreactive cells were also observed in the colonic mucosa regions regardless of the TNBS treatment. They were also dispersed throughout the

Table 2. Number of colonic endocrine cells

Groups / Endocrine Cell Types	Sham control	TNBS-treated
Argyrophil cells	78.43 ±14.14	17.14 ±3.29[a]
Argentaffin cells	20.71 ±2.21	6.71 ±2.36[a]
Immunoreactive cells		
Chromogranin A	241.57 ±60.50	65.14 ±35.93[a]
Serotonin	33.43 ±9.78	6.86 ±2.12[a]
Somatostatin	109.00 ±25.34	32.43 ±19.14[a]
Glucagon	57.57 ± 7.21	23.57 ±6.16[a]

Values are expressed mean ± SD of seven rats, numbers/mm^2 of colonic mucosa.
[a]$p < 0.01$ as compared with sham control.

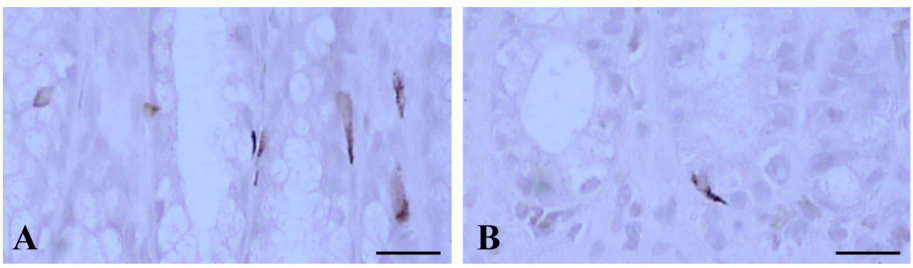

Fig. 3. Representative argentaffin endocrine cells in the colon of the sham control (A) and TNBS (B)-treated groups. Note that marked decreases in the number of colonic argentaffin cells were detected in the TNBS-treated animals compared to the sham control. Masson-Hamperl stain. Scale bars = 320 μm.

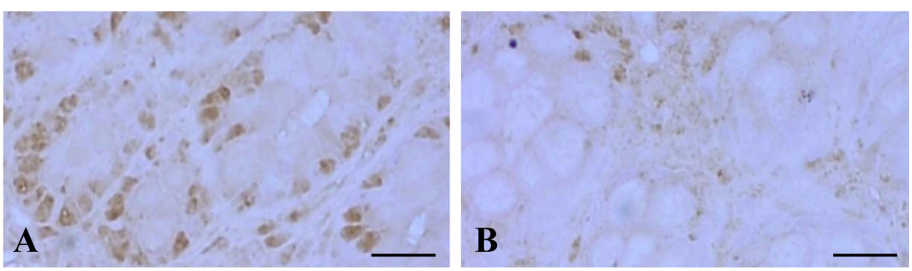

Fig. 4. Representative CGA-immunoreactive cells in the colon of the sham control (A) and TNBS (B)-treated groups. Note that marked decreases in the number of colonic CGA-immunoreactive cells were detected in the TNBS-treated animals as compared to the sham control. Peroxidase-anti peroxidase stain. Scale bars = 320 μm.

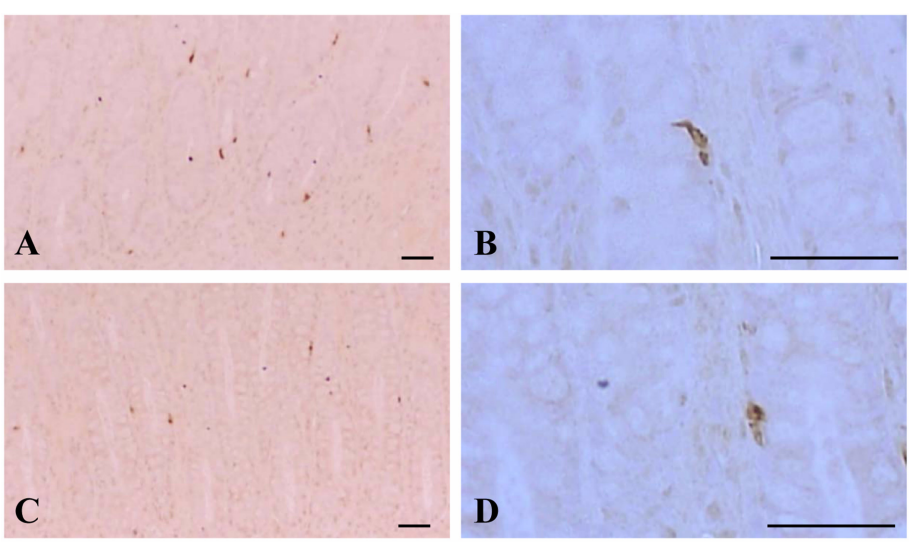

Fig. 5. Representative serotonin-immunoreactive cells in the colon of the sham control (A, B) and TNBS (C, D)-treated groups. Note that decreases in the number of colonic serotonin-immunoreactive cells were detected in the TNBS-treated animals compared to the sham control. Peroxidase-anti peroxidase stain. Scale bars = 160 μm.

entire colonic mucosa, located mainly in the intestinal glands regions. On the other hand, marked decreases in the number of colonic endocrine cells were observed in the TNBS-treated animals as compared to the sham control, respectively (Table 2; Figs. 2~7).

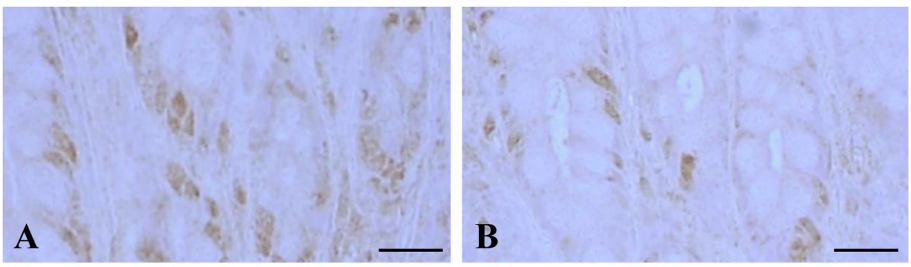

Fig. 6. Representative somatostatin-immunoreactive cells in the colon of the sham control (A) and TNBS (B)-treated groups. Note that decreases in the number of colonic somatostatin-immunoreactive cells were detected in the TNBS-treated animals compared to the sham control. Peroxidase-anti peroxidase stain. Scale bars = 320 m.

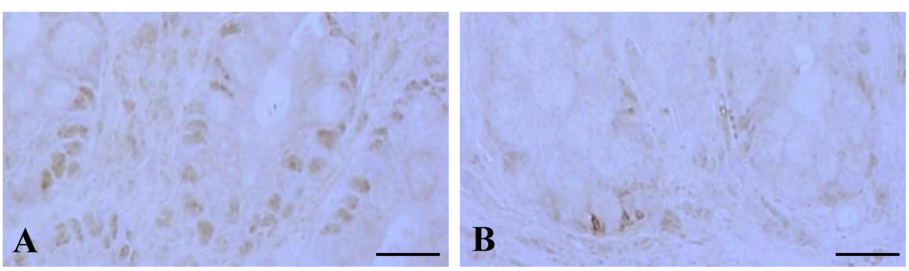

Fig. 7. Representative glucagon-immunoreactive cells in the colon of the sham control (A) and TNBS (B)-treated groups. Note that decreases in the number of colonic glucagon-immunoreactive cells were detected in the TNBS-treated animal compared to the sham control. Peroxidase-anti peroxidase stain. Scale bars = 320 m.

Discussion

Many factors have been implicated in the pathogenesis of ulcerative colitis, such as neutrophil infiltration and the over-production of proinflammatory mediators including cytokines, and reactive oxygen species (ROS). The tissue injury produced by neutrophils and macrophages has been attributed to their ability to release ROS, nitrogen metabolites, cytotoxic proteins, lytic enzymes and cytokines as well as their disrupting effects on the epithelial integrity [25]. TNBS instillation to the lumen of the colon induces classic intestinal inflammation with some resemblance to human ulcerative colitis mediated by oxidative stress [16, 27]. GI endocrine cells are considered the anatomical units responsible for the production of gut hormones, and the change in their density would reflect a change in the capacity to produce these hormones [9].

In the macroscopic scoring system, the higher the level of ulcerative colitis increases with increasing score [10]. MPO is one of activating cytotoxic enzymes released from polymorphic neutrophils [15], and the levels of MPO are also higher in TNBS-induced colitis [30]. The reduction of neutrophil influx into the colonic tissue can be confirmed by the MPO activity [6, 30]. Generally, ulceration, mucous cell depletion, inflammatory cell infiltration and edematous changes were induced histopathologically by a treatment with TNBS [16], and these histopathology and histomorphometry provided a valuable criterion [7, 24, 35]. The microscopic scoring system based on the mucosa and submucosa ulceration, mucous cell depletion, mitotic activity of crypts, inflammatory cell infiltration, vascularity, collagen deposition and edema in the colon, is one of histopathological evaluations generally used to detect the severity of ulcerative colitis. In this system, the level of ulcerative colitis increases with increasing score [24, 35]. Therefore, the increases in the macroscopic and microscopic scores and the colonic MPO activities are considered direct evidence that ulcerative colitis has been induced by the TNBS instillations mediated by oxidative stresses.

Silver techniques have been regarded as a general method for detecting GI endocrine cells, which were classified as Grimelius positive argyrophil and Masson-Hamperl positive argentaffin cells [11, 20]. CG belongs

to a family of large anionic proteins, the members of which are present in the secretory granules of a broad spectrum of amine and peptide-producing cells of the adrenal medulla and gastrointestinal endocrine system, as well as in some neurons of the peptidergic and catecholaminergic nervous system of several mammals [28]. CGs occur in a wide variety of endocrine organs and cells outside the adrenal medulla, and are considered common markers of all neuroendocrine cells [3]. Serotonin consists of monoamines and is distributed widely in the nervous system and GI endocrine cells. The main functions of serotonin are the inhibition of gastric acid secretion and contraction of the smooth muscle in the GI tract [13]. Somatostatin consisting of 14 amino acids was isolated from the hypothalamus of sheep for the first time and can be divided into the straight and cyclic forms [1]. This substance inhibits the secretion of the other neuroendocrine hormones [17]. Glucagon is synthesized in the cells of the pancreas and regulates the serum glucose levels [13]. GI endocrine cells might be involved in the pathogenesis of a range of digestive disorders, such as patients with ulcerative colitis, Crohn's disease [8], peristaltic reflex and motility disorders [37], and irritable bowel syndrome [32]. In addition, the relationship between the immune and neuroendocrine system in the normal colon and in pathology was also reported [26]. In the present study, marked decreases in colonic endocrine cells were detected in the TNBS-treated animal. These results suggest that colonic endocrine cells are also disrupted by TNBS-induced ulcerative colitis and these disruptions of colonic endocrine cells might be partially involved in the symptoms of colitis.

Conclusion

After TNBS instillation into the lumen of the colon in rats, ulcerative colitis was induced as increases in macroscopic and microscopic scores in the colon tissues along with increases in the colonic MPO activities. In addition, the number of colonic endocrine cells was also decreases by TNBS instillation. These results suggest that colonic endocrine cells were also disrupted by TNBS-induced ulcerative colitis.

Acknowledgments

This study was supported by a grant from the Korea Healthcare Technology R&D Project, Ministry for Health, Welfare & Family Affairs, Korea (A091049-1012-0000400).

References

1. **Brazeau P, Vale W, Burgus R, Ling N, Butcher M, Rivier J, Guillemin R.** Hypothalamic polypeptide that inhibits the secretion of immunoreactive pituitary growth hormone. Science 1973, **179**, 77-79.
2. **Buchan AM, Grant S, Brown JC, Freeman HJ.** A quantitative study of enteric endocrine cells in celiac sprue. J Pediatr Gastroenterol Nutr 1984, **3**, 665-671.
3. **Cohn DV, Elting JJ, Frick M, Elde R.** Selective localization of the parathyroid secretory protein-I/ adrenal medulla chromogranin A protein family in a wide variety of endocrine cells of the rat. Endocrinology 1984, **144**, 1963-1974.
4. **Depoortere I, Thijs T, Thielemans L, Keith JC, Van Assche G, Peeters TL.** Effect of recombinant human interleukin-11 on motilin and substance P release in normal and inflamed rabbits. Regul Pept 2001, **97**, 111-119.
5. **Depoortere I, Van Assche G, Peeters TL.** Motilin receptor density in inflamed and noninflamed tissue in rabbit TNBS-induced colitis. Neurogastroenterol Motil 2001, **13**, 55-63.
6. **Dost T, Ozkayran H, Gokalp F, Yenisey C, Birincioglu M.** The effect of *Hypericum perforatum* (St. John's Wort) on experimental colitis in rat. Dig Dis Sci 2009, **54**, 1214-1221.
7. **Dundar E, Olgun EG, Isiksoy S, Kurkcuoglu M, Baser KHC, Bal C.** The effects of intra-rectal and intra-peritoneal application of *Origanum onites* L. essential oil on 2,4,6-trinitrobenzenesulfonic acid-induced colitis in the rat. Exp Toxicol Pathol 2008, **59**, 399-408.
8. **El-Salhy M, Danielsson Å, Stenling R, Grimelius L.** Colonic endocrine cells in inflammatory bowel disease. J Intern Med 1997, **242**, 413-419.
9. **El-Salhy M, Sitohy B.** Abnormal gastrointestinal endocrine cells in patients with diabetes type 1: relationship to gastric emptying and myoelectrical activity. Scand J Gastroenterol 2001, **36**, 1162-1169.
10. **Giriş M, Depboylu B, Doğru-Abbasoğlu S, Erbil Y, Olgaç V, Allş H, Aykaç-Toker G, Uysal M.** Effect of taurine on oxidative stress and apoptosis-related protein expression in trinitrobenzene sulphonic acid-induced colitis. Clin Exp Immunol 2008, **152**, 102-110.

11. **Grimelius L, Wilander E.** Silver stains in the study of endocrine cells of the gut and pancreas. Invest Cell Pathol 1980, **3**, 3-12.
12. **Grisham MB, Benoit JN, Granger DN.** Assessment of leukocyte in involvement during ischemia and reperfusion on the intestine. In: Packer L, Glazer AN (eds.). Methods in Enzymology. Vol 186. pp. 729-741, Academic Press, San Diego, 1990.
13. **Guyton AC.** Textbook of Medical Physiology. 8th ed. pp. 801-815, WB Saunders, Philadelphia, 1991.
14. **Hollenbach E, Vieth M, Roessner A, Neumann M, Malfertheiner P, Naumann M.** Inhibition of RICK/nuclear factor-B and p38 signaling attenuates the inflammatory response in a murine model of Crohn disease. J Biol Chem 2005, **280**, 14981-14988.
15. **İşeri SÖ, Şener G, Yüksel M, Contuk G, Çetinel Ş, Gedik N, Yeğen BÇ.** Ghrelin against alendronate-induced gastric damage in rats. J Endocrinol 2005, **187**, 399-406.
16. **Jurjus AR, Khoury NN, Reimund JM.** Animal models of inflammatory bowel disease. J Pharmacol Toxicol Methods 2004, **50**, 81-92.
17. **Kitamura N, Yamada J, Calingasan NY, Yamashita T.** Immunocytochemical distribution of endocrine cells in the gastrointestinal tract of the horse. Equine Vet J 1984, **16**, 103-107.
18. **Ku SK, Lee HS, Lee JH.** An immunohistochemical study of chromogranin A and Sp-1 immunoreactive cells in the gastrointestinal tract of ovariectomized rats. J Vet Sci 2005, **6**, 191-196.
19. **Ku SK, Seong SK, Kim DY, Lee HS, Kim JD, Choi HY, Seo BI, Lee JH.** Changes of the intestinal endocrine cells in the C57BL/6 mouse after implantation of murine lung carcinoma (3LL): an immunohistochemical quantitative study. World J Gastroenterol 2005, **11**, 5460-5467.
20. **Lundqvist M, Arnberg H, Candell J, Malmgren M, Wilander E, Grimelius L, Öberg K.** Silver stains for identification of neuroendocrine cells. A study of the chemical background. Histochem J 1990, **22**, 615-623.
21. **Moran GW, Leslie FC, Levison SE, McLaughlin JT**. Enteroendocrine cells: neglected players in gastrointestinal disorders? Therap Adv Gastroenterol 2008, **1**, 51-60.
22. **Morris GP, Beck PL, Herridge MS, Depew WT, Szewczuk MR, Wallace JL.** Hapten-induced model of chronic inflammation and ulceration in the rat colon. Gastroenterology 1989, **96**, 795-803.
23. **O'Hara JR, Skinn AC, MacNaughton WK, Sherman PM, Sharkey KA.** Consequences of *Citrobacter rodentium* infection on enteroendocrine cells and the enteric nervous system in the mouse colon. Cell Microbiol 2006, **8**, 646-660.
24. **Peran L, Camuesco D, Comalada M, Nieto A, Concha A, Diaz-Ropero MP, Olivares M, Xaus J, Zarzuelo A, Galvez J.** Preventative effects of a probiotic, *Lactobacillus salivarius ssp. salivarius*, in the TNBS model of rat colitis. World J Gastroenterol 2005, **11**, 5185-5192.
25. **Pravda J.** Radical induction theory of ulcerative colitis. World J Gastroenterol 2005, **11**, 2371-2384.
26. **Qian BF, El-Salhy M, Melgar S, Hammarström ML, Danielsson Å.** Neuroendocrine changes in colon of mice with a disrupted IL-2 gene. Clin Exp Immunol 2000, **120**, 424-433.
27. **Rahimi R, Mozaffari S, Abdollahi M.** On the use of herbal medicines in management of inflammatory bowel diseases: a systematic review of animal and human studies. Dig Dis Sci 2009, **54**, 471-480.
28. **Reinecke M, Höög A, Östenson CG, Efendic S, Grimelius L, Falkmer S.** Phylogenetic aspects of pancreastatin- and chromogranin-like immunoreactive cells in the gastro-entero-pancreatic neuroendocrine system of vertebrates. Gen Comp Endocrinol 1991, **83**, 167-182.
29. **Rode J, Dhillon AP, Papadaki L, Stockbrügger R, Thompson RJ, Moss E, Cotton PB.** Pernicious anaemia and mucosal endocrine cell proliferation of the non-antral stomach. Gut 1986, **27**, 789-798.
30. **Seibel J, Molzberger AF, Hertrampf T, Laudenbach-Leschowski U, Diel P.** Oral treatment with genistein reduces the expression of molecular and biochemical markers of inflammation in a rat model of chronic TNBS-induced colitis. Eur J Nutr 2009, **48**, 213-220.
31. **Selvam R, Maheswari P, Kavitha P, Ravichandran M, Sas B, Ramchand CN.** Effect of *Bacillus subtilis* PB6, a natural probiotic on colon mucosal inflammation and plasma cytokines levels in inflammatory bowel disease. Indian J Biochem Biophys 2009, **46**, 79-85.
32. **Sikander A, Rana SV, Prasad KK**. Role of serotonin in gastrointestinal motility and irritable bowel syndrome. Clin Chim Acta 2009, **403**, 47-55.
33. **Singh I.** A modification of the Masson-Hamperl method for staining of argentaffin cells. Anat Anz 1964, **115**, 81-82.

34. **Sternberger LA.** Immunocytochemistry. 2nd ed. pp. 104-169, John Wiley & Sons, New York, 1979.
35. **Stucchi AF, Shofer S, Leeman S, Materne O, Beer E, McClung J, Shebani K, Moore F, O'Brien M, Becker JM.** NK-1 antagonist reduces colonic inflammation and oxidative stress in dextran sulfate-induced colitis in rats. Am J Physiol Gastrointest Liver Physiol 2000, **279**, G1298-1306.
36. **Tanida S, Mizoshita T, Mizushima T, Sasaki M, Shimura T, Kamiya T, Kataoka H, Joh T.** Involvement of oxidative stress and mucosal addressin cell adhesion molecule-1 (MAdCAM-1) in inflammatory bowel disease. J Clin Biochem Nutr 2011, **48**, 112-116.
37. **Vaccaro R, Parisi Salvi E, Nofroni I, D'Este I, Baglaj SM, Renda T.** Endocrine cells in atresic chick embryo intestine: histochemical and immunohistochemical study. Eur J Histochem 2009, **53**, 143-150.