

Effects of *Danggwieumja* on the Healing of Full-Thickness Skin Injury in Rat

Bum Hoi Kim*

Department of Anatomy, College of Oriental Medicine and Research Institute of Oriental Medicine, Dong-Eui University

The purpose of this study was to investigate the wound healing effects of *Danggwieumja* (DG), which is commonly used for skin inflammation, skin wound, skin pruritus, and chronic hives etc. The 1.5 cm × 1.5 cm full-thickness skin wound was induced to two groups, DG (n=16) and Saline (n=16) group. The DG extract and Saline were orally administrated daily for 15 days after skin wound induction. Then, the body weight of rats and the congestion indices were daily measured for 15 days after skin wound induction. The wound contractions and epithelizations were also measured. The wound contractions were daily measured for 15 days after wound induction and wound epithelizations were measured for 8 days from day 7 after wound induction. For evaluating angiogenesis, the immunoreactivities of vWF and VEGF protein were measured immunohistochemically on day 15. In results, although the percentage increases in mean body weight of rats in the DG and Saline groups hve no significant differences, DG extract decreased the time of wound healing and congestion around wound, and improved wound contraction and epithelization. The contraction percentage of DG group was significantly increased on day 5 (P<0.05) and day 7 (P<0.01) than that of Saline group. DG group showed significant increase of wound epithelization on day 7 (P<0.05) as compared to Saline group. Moreover, DG extract reduced the inflammation of skin dermis and promoted the growth of vascular vessels of dermis by accelerating vascular endothelial growth factor (VEGF) protein. These results suggest that DG has the beneficial effects on skin incision wound and can be the suitable wound healing agent for various surgical wounds.

Key words : wound healing, *Danggwieumja*, full-thickness skin wound, vascular endothelial growth factor (VEGF)

Introduction

Skin is the largest organ in the body, and it separates and protects the internal structures from the external environment. As a protective covering, it guards against the damaging effects of the sun, the loss of body fluids, the entrance of toxic substances into the body, and mechanical violence¹. If the skin is injured, irrespective of the size and severity of the injury, it should repair rapidly and perfectly. The healing response by the body's self-treatment system starts immediately at the moment an injury occurs.

Wound repair is a well-orchestrated and highly coordinated process that includes a series of overlapping phases². Skin wound healing starts immediately after injury and consists of three phases: inflammation, proliferation, and

maturation³. During the inflammatory phase, platelet aggregation at the injury site is followed by the infiltration of leukocytes such as neutrophils, macrophages, and T-lymphocytes into the wound site. In the proliferative phase, reepithelialization and newly formed granulation tissue begin to cover the wound area to complete tissue repair. Angiogenesis is indispensable for sustaining granulation tissue and a crucial step in the healing process. The formation of new blood vessels provides a route for oxygen and nutrient delivery, as well as a conduit for components of the inflammatory response^{4,5}.

When skin wound is induced, the rapid wound closure is very important because it is crucial not only to improve the quality of the patient's life, but also to reduce healthcare expenditure⁶. The rapid wound healing depends on many factors. Among many factors that affect the wound healing process, it was reported that oxygen plays an important role in how fast a wound heals⁷. Often, patients with difficult wounds are placed into hyperbaric chambers to heal open wounds faster⁸. Nutrition plays also an important role in the

* To whom correspondence should be addressed at : Bum Hoi Kim,
Department of Anatomy, College of Oriental Medicine and Research
Institute of Oriental Medicine, Dong-Eui University, Busan, Korea

· E-mail : bume@deu.ac.kr, · Tel : 051-850-7411

· Received : 2011/08/04 · Revised : 2011/08/29 · Accepted : 2011/09/10

wound healing process by providing substrates and energy for collagen synthesis, angiogenesis and wound contraction⁹.

Therefore, angiogenesis, the formation of new blood vessels from the pre-existent microvasculature, is essential for the process of healing of wounds. Immediately after wounding, it allows delivery of oxygen, nutrients and inflammatory cells to the site of injury. It also assists in the development of granulation tissue formation and ultimately wound closure. Angiogenesis is a complex, multistage process, in which a variety of cells are involved in the construction of new blood vessels¹⁰⁻¹².

Angiogenesis is required for normal wound healing. Therefore, stimulating their synthesis when wound repair is defective would be beneficial for promoting wound healing¹³. Vascular endothelial growth factor (VEGF) is one of the most potent angiogenic cytokines which promotes all steps in the angiogenic cascade¹⁴⁻¹⁶. In particular, it induces dissolution of the extracellular matrix, causes chemotaxis and proliferation of capillary endothelial cells and also promotes tube proliferation of endothelial cells. VEGF action is associated with a variety of physiological and pathological neovascular events such as embryonic development, tumor growth and wound repair as well¹⁷.

In oriental medicine, *Danggwieumja* (DG) is commonly used for skin inflammation, skin wound, skin pruritus, and chronic hives etc¹⁸. In previous study, an anti-allergic effect¹⁹ and an anti-atopic²⁰ effect of DG on animals were reported. The current study was designed to investigate the wound healing effects of DG on rats. To accomplish this, the full-thickness skin wound was induced and the changes of skin wounds and capillaries were observed.

Table 1. Herbal Composition of *Danggwieumja* (DG)

Herbal Name	Pharmacognostic Name	Weight
當歸	<i>Angelica Gigantis Radix</i>	10 g
乾地黃	<i>Rehmanniae Radix</i>	8 g
白芍藥	<i>Paeonia Radix</i>	6 g
川芎	<i>Cnidii Rhizoma</i>	6 g
白蒺藜	<i>Tribulus terrestris</i>	6 g
防風	<i>Ephedrae Herba</i>	6 g
何首烏	<i>Polygonum multiflorum</i>	4 g
荊芥	<i>Schizonepeta tenuifolia Briq.</i>	3 g
黃芪	<i>Astragali Radix</i>	3 g
甘草	<i>Glycyrrhizae Radix</i>	2 g
total		54 g

Materials and Methods

1. Animals

Thirty-two adult male Sprague-Dawley (SD) rats, weighing 250±25 g, were purchased from SamTaco (Kyung-gi, Korea). Rats were housed in individual cages under controlled

temperature environment 23±1°C, on a 12 h light-dark cycle, and maintained on standard rodent chow and water ad libitum. The animals were acclimatized to laboratory hygienic conditions for 1 week before starting the experiment.

2. Preparation and administration of DG

DG (270 g) was boiled with 2 L distilled water for 2 h. The supernatant was filtered and evaporated under reduced pressure to give aqueous extracts, which was lyophilized. 64.8 g of lyophilized extract was obtained. On experiment day, the powdered extract of DG was dissolved in physiological saline solution. The solution was orally administered daily at 55.6 mg/100 g for 15 days. The amount administered was determined by assuming that an adult human of approximately 70 kg would take about 162 g (54 g×3) a day.

3. Full-thickness skin wound creation and treatment

Rats were anesthetized by diethyl ether, and Fur on the back of rats was shaved while the animals were under mild ether anesthesia. Skin tissue measuring 1.5 cm long × 1.5 cm width was removed surgically to create an excision wound, on the back using sterile surgical tools²¹. The wound of the animals were treated for 15 days and the wound healing was monitored.

Rats were randomly divided into two groups each including 16 animals. Full-thickness skin wound was performed on all animals. In DG group, rats were administered with DG for 15 days after operation. The rats in Saline group were fed with administered with saline.

4. Body weights and congestion indices

The body weight of rats was daily measured for 15 days after skin wound induction and the features of wound area were captured using digital camera. With observation of capillary around skin wound, the congestion indices were also measured as 4 grades²²; none: 0, slight: 1, moderate: 2, severe: 3.

5. Wound contractions and epithelizations

Using wound pictures of each rat, wound contractions and epithelizations were measured. The wound contractions were daily measured for 15 days after wound induction and wound epithelizations were measured for 8 days from day 7 after wound induction. The percentages of contraction and epithelization were calculated with the formular below²³.

$$\text{Wound contraction (\%)} = \frac{W_0 - W_i}{W_0} \times 100$$

$$\text{Wound epithelization (\%)} = \frac{W_i - U_i}{W_i} \times 100$$

W_0 = initiate square size of wound margin after wound incision

W_i = daily-measured square size of wound margin

U_i = daily-measured square size of wound.

6. Histopathology

After 15 days following skin wound induction, rats were anesthetized by diethyl ether, and the tissues of the incision wounds were excised. Part of the excised tissue was fixed in 4% paraformaldehyde for 3 h, embedded in paraffin, and 5- μ m sections were prepared. The sections were deparaffinized in xylene and rehydrated and stained with Haematoxylin and Eosin (H&E). The sections were examined under a light microscope.

7. Immunohistochemistry

For immunostaining with vWF and VEGF, tissues were deparaffined, rehydrated and washed in PBS (pH7.4). After pretreatment with PBS supplemented with 0.3% hydrogen peroxide and 0.1% sodium azide for 10 min, the preparations were washed in PBS twice and incubated with blocking medium (10% normal goat serum in PBS) for 10 min. Anti-vWF (SM1686, 1:500 dilution; Novus Bio.) and anti-VEGF (ab46154-100, 1:100 dilution; Abcam) were applied to the tissues and incubated overnight at 4°C. After two washes with PBS, the tissue samples were incubated with peroxidase-conjugated goat anti-rabbit IgG antibodies diluted 1:100 in PBS for 30 min. Visualization of the reaction products was performed with 0.2 mg/ml 3',3'-diaminobenzidine tetrahydrochloride in PBS supplemented with 0.003% hydrogen peroxide.

8. Statistical analysis

Data are expressed as the mean \pm SE. A Student's t-test was performed in order to compare the mean values of the various parameters between the DG and Saline groups.

Results

1. The changes of body weights

The mean body weights of rats during experiment are represented in Fig. 1. The rats in the both DG and Saline groups showed the increase in body weight. The body weight in the DG group was 263.1 \pm 2.3 g on day 1 and 296.5 \pm 7.6 g on day 15, respectively. While in Saline group it was only 262.4 \pm 3.7 g and 306.7 \pm 5.8 g, respectively. The percentage increase in mean body weight of rats in the DG and Saline groups was 12.9% and 17.2% respectively but, there were no

significant differences between 2 groups.

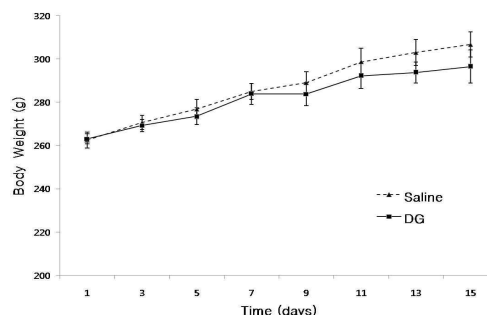


Fig. 1. Changes of the body weights of rats in DG and Saline group.

The body weight of rats was daily measured for 15 days after skin wound induction. The rats in the both DG and Saline groups showed the increase in body weight. There were no significant differences between 2 groups. Mean \pm SE.

2. The morphologic changes of wound area

In the rats of both DG and Saline groups, the complete healing was not achieved after 15 days following skin wound induction. But, the rate of healing was faster and more consistent in rats of DG group than Saline group especially after day 7. The rate of wound contraction in the DG group was also much higher compared to the Saline group (Fig. 2).

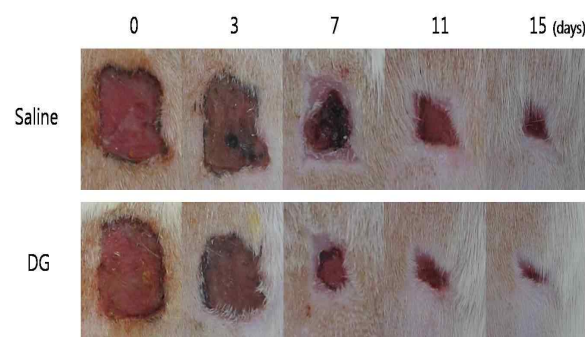


Fig. 2. The representative pictures of skin wound in the rats of DG and Saline groups.

In the rats of both DG and Saline groups, the complete healing was not achieved after 15 days following skin wound induction. However, the wound contraction in the DG group was more rapid as compared to the Saline group.

3. Congestion indices

The congestion indices were gradually decreased during experimental period and did not significantly differ between the DG and Saline groups. However, the congestion index in Saline group was significantly higher on day 7 than that of DG group. The congestion index in the DG group was 2.6 \pm 0.1 on day 3 and 0.4 \pm 0.2 on day 15, respectively. While in Saline group it was only 2.2 \pm 0.2 and 0.6 \pm 0.2, respectively (Fig. 3).

4. The changes of wound contraction

The wound contraction in the both DG and Saline group

were gradually increased daily and the percentage of wound contraction in the DG group was higher compared to the Saline group during total experimental period. The percentage of wound contraction in the DG group was 61.9±3.5% on day 7 and 89.4±1.4 on day 15, respectively. While in Saline group it was only 47.2±3.7% and 85.0±3.6, respectively(Fig. 4). The contraction percentage of DG group was significantly increased on day 5 and 7 than that of Saline group. The DG group showed 33.0% ($P<0.05$) and 31.2% ($P<0.01$) increase in the % coverage of the wound as compared to Saline group on day 5 and 7 respectively.

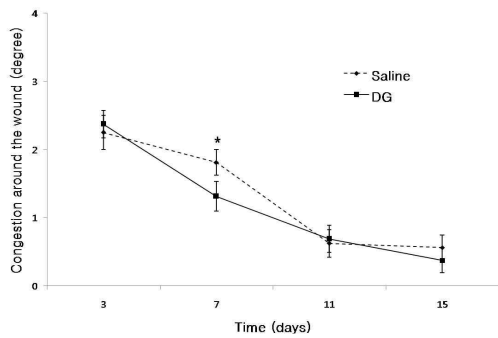


Fig. 3. The congestion indices of wound area in the rats of DG and Saline groups. The congestion indices were measured as 4 grades. The congestion indices of both of DG and Saline groups were gradually decreased during experiment. The congestion index of DG group was significantly decreased as compared to Saline group on day 7. Mean ± SE. * $P<0.05$

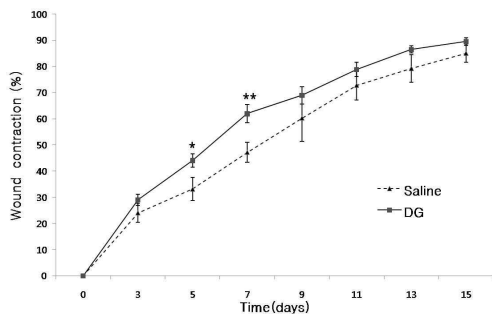


Fig. 4. Changes of wound contraction percentage in the rats of DG and Saline groups after skin wound induction. The wound contraction in the both DG and Saline group were gradually increased daily and DG group was significantly increased on day 5 and 7 as compared to Saline group. Mean ± SE. * $P<0.05$, ** $P<0.01$.

5. The changes of wound epithelization

The wound epithelizations of DG and Saline groups were observed from day 7 after skin wound induction. The wound epithelization in the DG and Saline group were also gradually increased during experiment. The percentage of wound epithelization in the DG group was 20.2±2.6% on day 7 and 85.7±6.4 on day 15, respectively. While in Saline group it was only 11.4±3.3% and 83.6±4.9, respectively.

There were no significant differences in the percentage of

wound epithelization between 2 groups except day 7, on which DG group showed 77.5% ($P<0.05$) increase as compared to Saline group(Fig. 5).

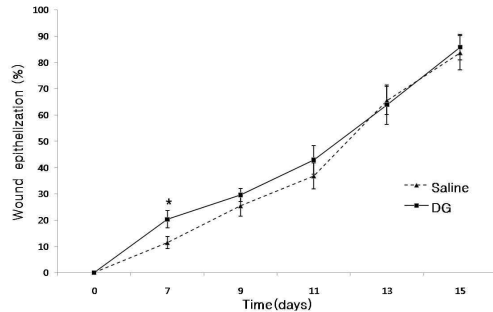


Fig. 5. Changes of wound epithelization percentage in the rats of DG and Saline groups after skin wound induction. The wound epithelization in the DG and Saline group were gradually increased during experiment and there were no significant differences in the percentage of wound epithelization between 2 groups except day 7. Mean ± SE. * $P<0.05$

6. Histopathological observation

At the day 15 of experiment, there was inflammatory reaction in dermis of DG and Saline groups. However, the severity of the reaction in DG group was lower than Saline group.

The incision site in Saline group showed irregular arrangement of collagen were loosely packed, and wounds were only moderately cellular with fibroblast cells. The DG group showed more densely packed and compactly arranged collagen with more fibroblasts cells, increased blood vessel formation(Fig. 6A, B).

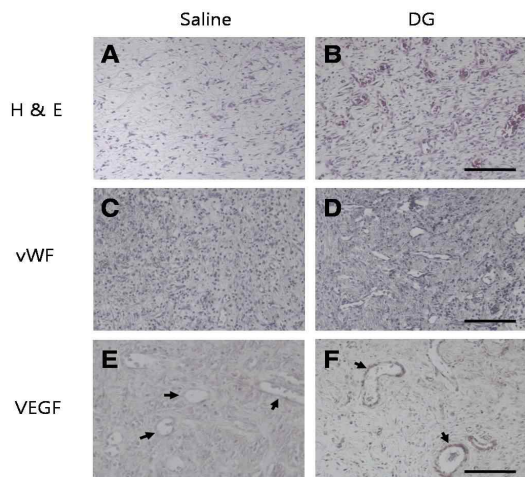


Fig. 6. Representative pictures of H&E staining and immunohistochemistry of DG and Saline groups on day 15 after rat skin incision wound. The DG group showed more fibroblasts cells and increased blood vessel formation (A, B). vWF-positive vessels of DG group were increased in number significantly as compared to Saline group (C, D). Expressions of VEGF in DG group represented significant increase as compared with Saline group (E, F arrows). magnification = A, B, C, D : 200×, E, F : 400×. Scale Bar = B, D : 200 μm, F : 100 μm

7. The changes of capillaries

The anti-vWF antibody was used to stain vascular endothelial cells and the anti-VEGF antibody was used to stain vascular endothelial growth factors in paraffine sections. In immunostaining, anti-vWF immunohistochemistry stained vascular vessels and vWF-positive vessels were observed in the dermis of DG and Saline groups on day 15 after wound induction. Blood vessels were homogeneously distributed in the granulation tissue in both DG and Saline group. However, the blood vessels of DG group were increased in number significantly as compared to Saline group (Fig. 6C, D).

8. VEGF immunoreactivities

Expressions of VEGF, pro-angiogenic growth factors, were assayed in incision wound tissues in both DG and Saline group on day 15 after wound induction and DG group showed significant increase as compared with Saline group (Fig. 6E, F arrows).

Discussion

Wound healing is a complex biological process, including inflammation, cell migration, angiogenesis, extracellular matrix synthesis, collagen deposition, and re-epithelialization^{24,25}. In this study, the administrations of DG extract for 15 days following full-thickness skin wound improved wound closure (Fig. 2) and reduced the congestion around wound area (Fig. 3). Nevertheless, the mean body weight of DG group was decreased compared with saline-treated group (Fig. 1). It seems it was because of metabolic increases by administrations of DG extract.

Recently, much attention has been paid to the rapid healing of wounds. The primary aims of wound healing are in promoting rapid wound closure and preventing excess scarring at the same time¹. The re-epithelialization of the wound is made easier by the underlying contractile connective tissue, which shrinks in size to bring the wound margins toward one another²⁶. In addition, growth factors and other related substances are also released, which are necessary for the initiation and propagation of granulation tissue formation. In this study, DG group showed a significant increase in wound collagen and rapid wound closure as compared to Saline group (Fig. 2). Especially, after day 7, the congestion was also significantly reduced (Fig. 3), as well as increased wound contraction. The percentage of wound contraction in the DG group was higher compared to the Saline group during total experiment and significantly increased on day 5 and 7 than Saline group (Fig. 4). The time required for complete

epithelization of the excision wound is an important parameter to assess the wound healing process. It was found that DG group showed rapid wound epithelization as compared to Saline group on day 7 (Fig. 5). Taken together, DG-treated rats showed faster wound closure and improved tissue regeneration at the wound site.

Angiogenesis, together with cell migration, inflammation, provisional matrix synthesis, collagen deposition and re-epithelialization plays an integral role in the process of skin repair¹³. During wound healing, angiogenic capillary sprouts invade the fibrin-fibronectin rich wound clot and organize into a microvascular networks throughout the granulation tissue. In this study, histopathologically, the inflammatory reaction in dermis of DG was decreased compared with Saline group on day 15 after skin wound induction and the DG group showed increased blood vessel formation (Fig. 6B). Immunohistochemically, the vWF-positive vessels in the dermis of DG were increased compared with Saline group (Fig. 6D).

VEGF has been shown to play a pivotal role in the initiation of angiogenesis, based on its ability to induce the expression of proteases that digest components of the extracellular matrix that impede angiogenesis, to promote endothelial cell proliferation, and to prevent their apoptosis^{27,28}. In skin wound healing, angiogenesis is a crucial event in the formation of new granulation tissue in the proliferative phase. It is well-known that VEGF produced by keratinocytes is one of the most potent angiogenic cytokines. It was demonstrated that VEGF was expressed on macrophages and fibroblasts in human skin wounds²⁹ and VEGF local therapy in db/db mice enhanced neovascularisation at the site of wound through a stimulation of local angiogenesis³⁰. A defect in endogenous VEGF production may contribute to impairment of reparative angiogenesis¹⁵. Our study showed that DG treatment led to increased expression of VEGF as compared with Saline group on day 15 (Fig. 6E, F arrows). This results can represent DG extract improved wound healing by increasing capillary vessels to wound site with modulation of VEGF protein.

In conclusion, our results suggest that DG promotes wound contraction and epithelization and also reduces inflammatory reactions by modulating VEGF protein after skin wound induction.

Conclusion

In this study, the DG extract was orally administrated daily for 15 days after 1.5 cm × 1.5 cm full-thickness skin

wound induction. In results, DG extract made no significant difference in the change of body weight, but DG extract decreased the time of wound healing and congestion around wound and improved wound contraction and epithelization. Moreover, DG extract promoted the growth of vascular vessels of dermis by accelerating vascular endothelial growth factor (VEGF) protein.

References

- Han, D., Kim, H.Y., Lee, H.J., Shim, I., Hahm, D.H. Wound healing activity of gamma-aminobutyric Acid (GABA) in rats. *J Microbiol Biotechnol.* 17(10):1661-1669, 2007.
- Clark, R.A. Cutaneous tissue repair: basic biologic considerations. I. *J Am Acad Dermatol.* 13(5):701-725, 1985.
- Ermertcan, A.T., Inan, S., Ozturkcan, S., Bilac, C., Cilaker, S. Comparison of the effects of collagenase and extract of *Centella asiatica* in an experimental model of wound healing: an immunohistochemical and histopathological study. *Wound Repair Regen.* 16(5):674-681, 2008.
- Luo, J.D., Chen, A.F. Nitric oxide: a newly discovered function on wound healing. *Acta Pharmacol Sin.* 26(3):259-264, 2005.
- Singer, A.J., Clark, R.A. Cutaneous wound healing. *N Engl J Med.* 341(10):738-746, 1999.
- Dubay, D.A., Franz, M.G. Acute wound healing: the biology of acute wound failure. *Surg Clin North Am.* 83(3):463-481, 2003.
- Breitenbach, K.L., Bergera, J.J. Principles and techniques of primary wound closure. *Prim Care.* 13(3):411-431, 1986.
- Yildiz, S., Cimsit, M., Ilgezdi, S., Uzun, G., Gumus, T., Qyrdedi, T., Dalci, D. Hyperbaric oxygen therapy used to treat radiation injury: two case reports. *Ostomy Wound Manage.* 52(5):14-20, 2006.
- Thompson, C., Fuhrman, M.P. Nutrients and wound healing: still searching for the magic bullet. *Nutr Clin Pract.* 20(3):331-347, 2005.
- Folkman, J., Shing, Y. Angiogenesis. *J Biol Chem.* 267(16):10931-10934, 1992.
- Risau, W. Mechanisms of angiogenesis. *Nature.* 386(6626):671-674, 1997.
- Li, J., Zhang, Y.P., Kirsner, R.S. Angiogenesis in wound repair: angiogenic growth factors and the extracellular matrix. *Microsc Res Tech.* 60(1):107-114, 2003.
- Tonnesen, M.G., Feng, X., Clark, R.A. Angiogenesis in wound healing. *J Invest Dermatol Symp Proc.* 5(1):40-46, 2000.
- Ferrara, N. Role of vascular endothelial growth factor in the regulation of angiogenesis. *Kidney Int.* 56(3):794-814, 1999.
- Bitto, A., Minutoli, L., Altavilla, D., Polito, F., Fiumara, T., Marini, H., Galeano, M., Calò, M., Lo Cascio P., Bonaiuto, M., Migliorato, A., Caputi, A.P., Squadrito, F. Simvastatin enhances VEGF production and ameliorates impaired wound healing in experimental diabetes. *Pharmacol Res.* 57(2):159-169, 2008.
- Roy, H., Bhardwaj, S., Ylä-Herttuala, S. Biology of vascular endothelial growth factors. *FEBS Lett.* 580(12):2879-2887, 2006.
- Nissen, N.N., Polverini, P.J., Koch, A.E., Volin, M.V., Gamelli, R.L., DiPietro, L.A. Vascular endothelial growth factor mediates angiogenic activity during the proliferative phase of wound healing. *Am J Pathol.* 152(6):1445-1452, 1998.
- Im, G.M., Jeong, H.W., Kim, H.S., Jeong, W.Y. Oriental Medical Approach on the Allergic Disease. *Korean J. Oriental Physiology & Pathology.* 15(5):831-839, 2002.
- Han, K.H., Park, E.J., Lee, H.J. A Comparative Study of Regulatory Effect of Atopic Allergic Reaction by Prescriptions (A, B). *J Korean Oriental Pediatrics* 19(2):13-30, 2005.
- Song, S.P., Son, D.B., Hwang, C.H., Song, S.H., Hwang, C.Y. Effects of Danggwieumja Administration along with Samhwangseje-gamibang on NC/Nga Atopic Mice. *Korean J. Oriental Physiology & Pathology.* 21(5):1210-1218, 2007.
- Judith, R., Nithya, M., Rose, C., Mandal, A.B. Application of a PDGF-containing novel gel for cutaneous wound healing. *Life Sci.* 87(1-2):1-8, 2010.
- Choi, K.M., Lee, C.W., Lee, M.Y. Effect of Ore Minerals on the Healing of Full-Thickness Skin Injury Model of Rat. *Jounal of the Environmental Sciences.* 17(7):809-816, 2008.
- Jung, S.I., Kang, S.S., Cho, S.K., Choi, S.H. Effect of propolis on healing of full-thickness skin wound in rabbits. *Korea J. Vet. Clin. Med.* 17(1):62-29, 2000.
- Diegelmann, R.F., Evans, M.C. Wound healing: an overview of acute, fibrotic and delayed healing. *Front Biosci.* 9: 283-289, 2004.
- Jacobs, S., Simhaee, D.A., Marsano, A., Fomovsky, G.M., Niedt, G., Wu, JK. Efficacy and mechanisms of vacuum-assisted closure (VAC) therapy in promoting wound healing: a rodent model. *J Plast Reconstr Aesthet Surg.* 62(10):1331-1338, 2009.
- Sugihara, A., Sugiura, K., Morita, H., Ninagawa, T., Tubouchi, K., Tobe, R., Izumiya, M., Horio, T., Abraham, N.G., Ikehara, S. Promotive effects of a silk film on epidermal recovery from full-thickness skin wounds. *Proc*

- Soc Exp Biol Med. 225(1):58-64, 2000.
27. Werner, S., Grose, R. Regulation of wound healing by growth factors and cytokines. *Physiol Rev.* 83(3):835-970, 2003.
 28. Diegelmann, R.F., Evans, M.C. Wound healing: an overview of acute, fibrotic and delayed healing. *Front Biosci.* 9: 283-289, 2004.
 29. Hayashi, T., Ishida, Y., Kimura, A., Takayasu, T., Eisenmenger, W., Kondo, T. Forensic application of VEGF expression to skin wound age determination. *Int J Legal Med.* 118(6):320-325, 2004.
 30. Takamiya, M., Saigusa, K., Aoki, Y. Immunohistochemical study of basic fibroblast growth factor and vascular endothelial growth factor expression for age determination of cutaneous wounds. *Am J Forensic Med Pathol.* 23(3):264-267, 2002.