

# Case Report : Non-surgical Treatment of Inferior Alveolar Nerve Injury as a Result of Overinstrumented Root Canal Treatment

Kook-Jin Bae<sup>1</sup>, D.D.S., Jong-Mo Ahn<sup>1</sup>, D.D.S., M.S.D., Ph.D.  
Chang-Iyuk Yoon<sup>1</sup>, D.D.S., M.S.D., Ph.D., Young-Gon Cho<sup>2</sup>, D.D.S., M.S.D., Ph.D.,  
Ji-won Ryu<sup>1</sup>, D.D.S., M.S.D.,

*Department of Oral medicine<sup>1</sup>, Department of Operative Dentistry<sup>2</sup>,  
School of Dentistry, Chosun University*

During root canal treatment, overinstrumentation with hand or mechanically driven files can perforate the mandibular canal, allowing the extrusion of endodontic sealers, dressing agents, and irrigant solutions out of the tooth and into the canal. The patient may report symptoms such as pain, hyperesthesia, hypoesthesia, anesthesia, dysesthesia and paresthesia.

Such problems must be resolved as quickly as possible to avoid irreversible sequelae caused by certain neurotoxic materials that form part of endodontic sealants. Although there have been no controlled trials of treatment protocols involving endodontically related injuries to the inferior alveolar nerve, the normal therapeutic sequence for this complication is the control of pain and inflammation and, whenever possible, the surgical elimination of the cause.

However, total resolution of pain and reduction in or disappearance of paraesthesia after a non-surgical management have been reported. Antiepileptic drugs such as gabapentin or pregabalin have been used for the treatment of neuropathic pain.

This article describes a case of inferior alveolar nerve(IAN) damage after endodontic treatment of a mandibular right second molar and the treatment with non-surgical approach using prednisone and gabapentin medication, monitoring the patient's condition with clinical neurosensory examination and current perception threshold test(Neurometer).

**Key words** : Current perception threshold, Endodontic complication, Endodontic sealer, Gabapentin, Inferior alveolar nerve injuries

**Corresponding author** : Ji-Won Ryu

*Department of Oral Medicine, Chosun University 421,*

*College of Dentistry*

*Seosuk-dong Dong-Gu, Gwang-Ju, 501-825*

*Tel: 062-220-3897*

*Fax: 062-234-2119*

*E-mail: dentian@chosun.ac.kr*

Received: 2011-08-03

Accepted: 2011-09-01

\* This study was supported by research funds from Chosun University, 2010

## I. INTRODUCTION

The inferior alveolar and lingual nerve injury can occur after several types of dental treatment, including local anesthetic injections<sup>1,2)</sup>, endodontic treatment<sup>3)</sup>, implant placement<sup>1)</sup>, and dentoalveolar surgery, particularly involving the removal of mandibular third molars.<sup>1,4)</sup> These dental treatments can cause permanent nerve damage resulting in anesthesia, paresthesia, and dysesthesia.<sup>5,6)</sup>

One of the potential iatrogenic causes of this

problem is the incorrect treatment of the root canals of a lower molar or premolar (overextension and/or overfilling). The mechanism by which such treatment can damage the inferior alveolar nerve(IAN) may be mechanical, thermal, or chemical.<sup>7)</sup> There have been reports of IAN damage in up to 1% of cases when performing defective root canal treatment (overextended or overfilled) of a lower premolar.<sup>8)</sup> The patient may report symptoms such as pain, hyperesthesia, hypoesthesia, anesthesia, dysesthesia and paresthesia.<sup>9,10)</sup>

Such problems must be resolved as quickly as possible to avoid irreversible sequelae caused by certain neurotoxic materials that form part of endodontic sealants.<sup>11)</sup> Although there have been no controlled trials of treatment protocols involving endodontically related injuries to the inferior alveolar nerve, the normal therapeutic sequence for this complication is the control of pain and inflammation and, whenever possible, the surgical elimination of the cause.<sup>3)</sup> However, total resolution of pain and reduction in or disappearance of paraesthesia after a non-surgical management have been reported.<sup>10,12-14)</sup> Antiepileptic drugs such as gabapentin or pregabalin have been used for the treatment of neuropathic pain.

This article describes a case of IAN damage after endodontic treatment of a mandibular right second molar and the treatment with non-surgical approach using prednisone and gabapentin medication, monitoring the patient's condition with clinical neurosensory examination and current perception threshold test(Neurometer).

## II. CASE REPORT

A 32-year-old woman was referred to the department of oral medicine, Chosun University Dental Hospital(CUDH) for pain and numbness of the right chin, mandibular gingiva and buccal mucosa. 1 day before, in a local clinic, she had undergone root canal treatment of the mandibular right second molar. During the treatment, she felt a sudden, severe pain in the tooth being treated. The treatment was immediately terminated and the endodontic sealer, Vitapex<sup>®</sup>, was injected into the root canal. The pain continued and was so intense the patient could not sleep that night. After 1 day, the pain was reduced because she took the analgesics. However the numbness in the right chin, lower lip, buccal mucosa and gingiva continued.

Clinical and radiographic examinations were taken at CUDH to assess her symptoms. Panoramic and periapical radiography showed radiopaque material in the right mandibular canal(Fig. 1,a,b). We tentatively diagnosed her symptoms as inferior alveolar nerve injury owing to the result of radiographic examination. To confirm this diagnosis, we ordered the Cone Beam-Computed Tomography (CBCT) test for assessment of the relationship between the endodontic sealer(Vitapex<sup>®</sup>) and the mandibular canal. The result was the same as the panoramic examination, radiopaque material was noted in the right mandibular canal(Fig. 2).

Treatment started with an anti-inflammatory regimen including prednisolone(Solondo<sup>®</sup> 5 mg), tapering from 30 mg/day to 5 mg/day over 6 days.

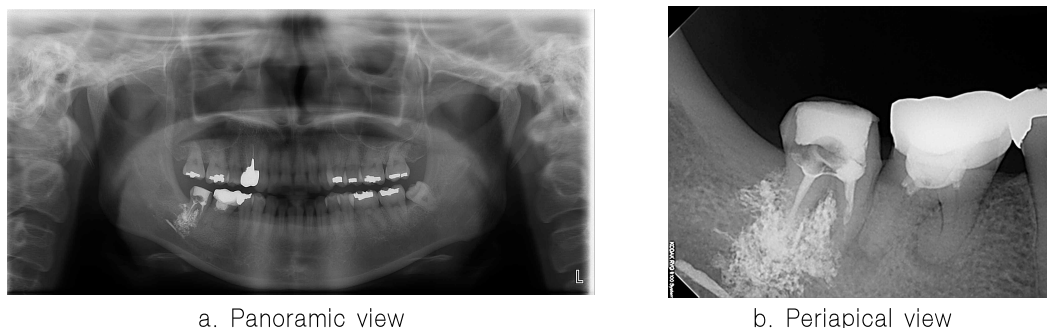


Fig. 1. The results of the radiographic examination at the first visit

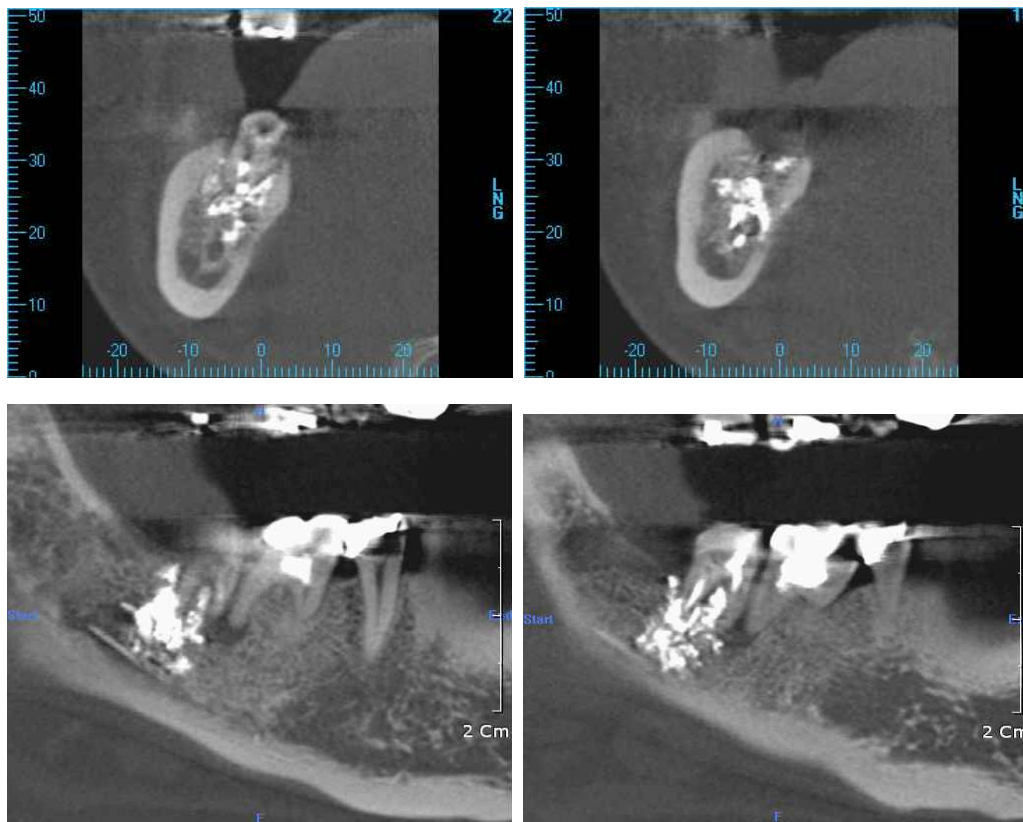


Fig. 2. The result of the Cone-Beam Computed tomography(CBCT) at the first visit

1 week later, the patient revisited and reported that the pain and numbness were slightly relieved. After discussing about treatment options, she preferred the non-surgical treatment to surgical debridement and decompression of the inferior alveolar canal. Gabapentin(Neurontin®) was prescribed, increasing the dosage from 600 mg/day to 1200 mg/day, according to the pain reported in the regular monthly visit. At follow-up appointments, we evaluated the symptoms using three methods; mapping, Clinical Neurosensory Examination(CNE), and the Current Perception Threshold(CPT) test. The affected lesion was mapped for any notable changes in size or position. The CNE evaluated mechanoreceptive and nociceptive function on the affected side versus the non-affected side. For CNE, the pressure, touch, pin prick sensation were tested. Sensation was quantified on a scale of 0 to 100, where 0 is complete anesthesia and 100 is normal sensation compared to

the non-affected site. CPT was assessed by the Neurometer(Neurotron Inc., Baltimore, MD). A noninvasive transcutaneous electrical stimulus was delivered to the skin overlying the chin. The site included the affected side and non-affected contralateral side. Each site received 3 stimulus frequencies, 2,000, 250, and 5Hz, which are known to stimulate A-beta, A-delta, and C fibers, respectively. CNE and Neurometer examination were not done on the same day, except on the first visit, due to the lack of time. Instead, on every follow up visit, only one test was carried out in the order of CNE and Neurometer. The results of the tests follows(Fig. 3, Fig. 4., Table 1.).

After six months of the medication, the patient reported that the sensation had recovered almost completely, but the patient occasionally felt tingling sensation in the right chin area. Finally, the medication was stopped and the patient was referred

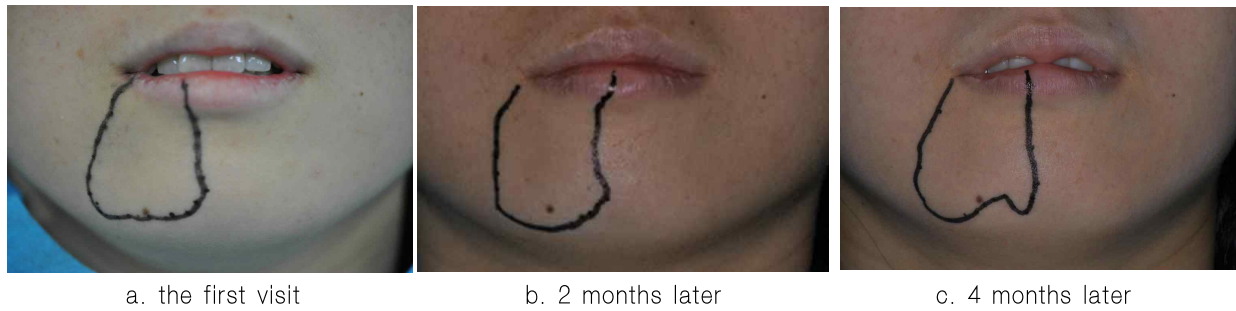


Fig. 3. Comparison of affected lesion

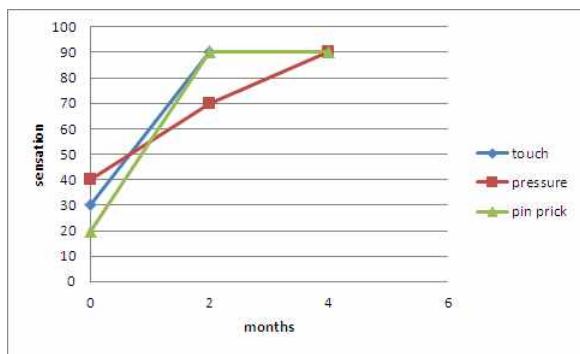


Fig. 4. Comparison of the result of clinical neurosensory evaluation(CNE)

to the department of Operative Dentistry for completion of the root canal treatment of the mandibular right second molar. A final periodic follow up at the end of the dental treatment was planned, but the patient did not return to our clinic.

### III. DISCUSSION

During root canal treatment, overinstrumentation with hand or mechanically driven files can perforate the mandibular canal, allowing the extrusion of endodontic sealers, dressing agents, and irrigant solutions out of the tooth and into the canal.<sup>15)</sup>

Ideally, during the root canal treatment, the filling material should be confined to the root canal.<sup>9)</sup> Overextension and/or overfilling of mandibular molar and premolar is a potential iatrogenic cause of inferior alveolar nerve injury.<sup>6)</sup> Severe endodontic pain after endodontic sealer extrusion requires early diagnosis and prompt management to reduce the risk of permanent nerve damage.<sup>14)</sup>

Meaningful symptoms can be easily obtained by a medical examination and interview with patient.

The patient can easily express what had happened since the event is definite, that is root canal

Table 1. Comparison of the current perception threshold(CPT) test

CPT Measures and Analysis Summary				
side	Frequency	First visit	3 months	5 months
Rt.	2000 Hz	484	112	52
	250 Hz	264	16	5
	5 Hz	163	3	2
Lt.	2000 Hz	132	72	120
	250 Hz	20	10	31
	5 Hz	7	7	9

treatment. In this case, the patient reported severe pain during the root canal treatment, and after taking analgesics, the pain was relieved but the numbness in the affected area persisted.

The radiographic examinations(panoramic and periapical radiograph) revealed a radiopaque material around the mandibular canal.(Fig. 1.a,b) In most case articles, a radiopaque material was found in the panoramic radiograph or periapical radiograph.<sup>6,9,10</sup> In this case, Cone Beam Computed Tomograph(CBCT) was taken additionally.(Fig .2.) The conventional radiographic image of the mandibular canal is dark linear shadow with thin radiopaque superior and inferior borders cast by the lamella of bone that binds the canal. Furthermore, the mandibular canal can be superimposed over the apex of a molar.<sup>16)</sup> Recently, cone beam computed tomography(CBCT) has been proposed as an effective radiographic diagnostic device when endodontic related inferior alveolar nerve or mental foramen paraesthesia is suspected.<sup>17)</sup> We considered that CBCT has more advantage in the diagnosis of such case over the conventional radiograph. By using CBCT, the limitation of conventional radiograph can be overcome. (생략 CBCT has been proposed as an effective radiographic diagnostic device when endodontic related inferior alveolar nerve or mental nerve damage is suspected.)

Studies have shown that all root canal sealants are neurotoxic to some degree.<sup>3)</sup> Even root canal sealants that are believed to be more benign, such as zinc oxide and eugenol and calcium hydroxide (owing to its high pH)<sup>18)</sup>, have been shown to be neurotoxic in vitro<sup>19-24)</sup> and are almost certainly neurotoxic in vivo.<sup>25)</sup> In this case, the patient reported the sharp, severe pain when the doctor injected Vitapex<sup>®</sup> into the root canal of the right mandibular second molar. Vitapex<sup>®</sup> which is a premixed Calcium hydroxide with iodoform paste may gain entry into the mandibular canal, and it can damage the nerve owing to its high pH. Pogrel and Thamby<sup>3)</sup> suggested that root canal sealants' have neurotoxic properties only when they come into direct contact with the individual fascicles, and as

long as they are outside the epineurium, they are safe. In this case, the symptoms of the patient recovered in a short period of time, assessed by clinical neurosensory evaluation(CNE) and the current perception threshold(CPT) test(Fig.4, Table 1), however, the size of the affected lesion was almost the same in the mapping test.(Fig. 3.) It was postulated that Vitapex<sup>®</sup> might have compressed the inferior alveolar nerve, mechanically, but as it did not enter through the perineurium, therefore, there might be no chemical damage in the mandibular canal.

During treatment, we followed the symptoms up with the clinical neurosensory evaluation(CNE) combined with the current perception threshold (CPT) test(Neurometer;Neurotron Inc., Baltimore, MD), this was the uniqueness of this article, as far as we know. Neurometer provides reliable measurement of sensory nerve function for large and small myelinated as well unmyelinated nerve fibers. The stimulator delivers sine wave stimuli at frequencies of 2,000, 250 and 5 Hz, which have been shown to selectively stimulate large myelinated A $\beta$ , small myelinated A $\delta$  and small unmyelinated C fibers, respectively.<sup>16)</sup> Ziccardi VB et al.<sup>26)</sup> suggested that CNE combined with CPT may be used to aid in the assessment of the IAN injuries.

Treatment of this endodontic complication remains controversial, varying from a wait and-see approach, including anti-inflammatory drugs and periodic follow-up<sup>10,12-14)</sup>, to surgical debridement of the inferior alveolar nerve involving bone removal of the vestibular cortical plate<sup>16)</sup> or sagittal mandibulotomy.<sup>27)</sup> In the present case, the patient refused the surgical approach, but agreed to attend frequent follow-up appointments. Therefore, non-surgical management was agreed upon including anti-inflammatory treatment with prednisone and analgesic treatment with gabapentin. Steroid was prescribed to reduce the edema and inflammatory response. Morse DR<sup>25)</sup> advise immediate steroid administration, though there is no agreement regarding the type, dosage or duration of steroid treatment. The antiepileptic medication,

gabapentin(Neurontin®) was selected. Antiepileptic drugs such as pregabalin and gabapentin have been used for the treatment of neuropathic pain.<sup>9)</sup> This binds to the  $\alpha_2\delta$  subunit of calcium channel, however, the precise mechanism by which it produces analgesia is not well understood.<sup>28)</sup>

Finally, we suggest that the non-surgical approach with combination of prednisone and gabapentin was a good option in the management of inferior alveolar nerve damage subsequent to overinstrumentation. Immediate management and periodic follow-up is necessary for obtaining a predictable prognosis

## REFERENCES

1. Pogrel MA, Thamby S. The etiology of altered sensation in the inferior alveolar, lingual, and mental nerves as a result of dental treatment. *Journal of the California Dental Association* 1999;27(7):531,534-538.
2. Pogrel MA, Thamby S. Permanent nerve involvement resulting from inferior alveolar nerve blocks. *Journal of the American Dental Association* 2000;131(7): 901-907.
3. Pogrel MA. Damage to the inferior alveolar nerve as the result of root canal therapy. *Journal of American Dental Association* 2007;138:65-69
4. Robert RC, Bacchetti P, Pogrel MA. Frequency of trigeminal nerve injuries following third molar removal. *Journal of Oral and Maxillofacial Surgery* 2005;63(6):732-736.
5. Pogrel MA. Complications of Third Molar Surgery. *Oral Maxillofac Surg Clin North Am* 1990;2:441.
6. Escoda-Francoli J, Canalda-Sahli C, Soler A, Figueiredo R, Gay-Escoda C. Inferior alveolar nerve damage because of overextended endodontic material: a problem of sealer cement biocompatibility? *Journal of Endodontics* 2007;33(12):1484-1489.
7. Fanibunda K, Whitworth J, Steele J. The management of thermomechanically compacted gutta percha extrusion in the inferior dental canal. *British Dental Journal* 1998;184(7):330-332.
8. Knowles KI, Jergenson MA, Howard JH. Paresthesia associated with endodontic treatment of mandibular premolars. *Journal of Endodontics* 2003;29(11):768-770.
9. López-López J, Estrugo-Devesa A, Jané-Salas E, Segura-Egea JJ. Inferior Alveolar Nerve Injury Resulting From Overextension of an Endodontic Sealer: Non-surgical Management Using the GABA Analogue Pregabalin. *International Endodontic Journal* 2011;Aug 23;44(10):1-7.
10. González-Martín M, Torres-Lagares D, Gutiérrez-Pérez JL, Segura-Egea JJ. Inferior Alveolar Nerve Paresthesia After Overfilling of Endodontic sealer into the mandibular canal. *Journal of Endodontics* 2010;36(8):1419-1421.
11. Kothari P, Hanson N, Cannell H. Bilateral mandibular nerve damage following root canal therapy. *British Dental Journal* 1996;180(5):189-190.
12. Blanas N, Kienle F, Sándor GK. Inferior alveolar nerve injury caused by thermoplastic guttapercha overextension. *Journal of the Canadian Dental Association* 2004;70(6):384 - 387.
13. Poveda R, Bagán JV, Fernández JM, Sanchis JM. Mental nerve paresthesia associated with endodontic paste within the mandibular canal: report of a case. *Oral Surgery, Oral Medicine, Oral Pathology, Oral Radiology, and Endodontics* 2006;102(5):e46 - 49.
14. Froes FG, Miranda AM, Abad Eda C, Riche FN, Pires FR. Non-surgical management of paraesthesia and pain associated with endodontic sealer extrusion into the mandibular canal. *Australian Endodontic Journal* 2009;35(3):183 - 186.
15. Köseoğlu BG, Tanrikulu S, Sübay RK, Sencer S. Anesthesia following overfilling of a root canal sealer into the mandibular canal: a case report. *Oral Surgery, Oral Medicine, Oral Pathology, Oral Radiology, and Endodontics* 2006;101(6):803 - 806.
16. Stuart C. White, Michael J. Pharoah, *Oral Radiology: principles and interpretation*, Fifth edition, St. Louis, 2004, Mosby Inc., pp.184.
17. Gambarini G, Plotino G, Grande NM *et al.* Differential diagnosis of endodontic-related inferior alveolar nerve paraesthesia with cone beam computed tomography: a case report. *International Endodontic Journal* 2011;44(2):176 - 181.
18. Conrad SM. Neurosensory disturbances as a result of chemical injury to the inferior alveolar nerve. *J Oral Maxillofac Surg Clin North Am* 2001;13(2):255-263.
19. Pogrel MA. The results of microneurosurgery of the inferior alveolar and lingual nerve. *Journal of Oral and Maxillofacial Surgery* 2002;60(5):485-489.
20. Asgari S, Janahmadi M, Khalilkhani H. Comparison of neurotoxicity of root canal sealers on spontaneous bioelectrical activity in identified Helix neurones using an intracellular recording technique. *International*

- Endodontic Journal 2003;36(12):891-897.
21. Asrari M, Lobner D. In vitro neurotoxic evaluation of root-end filling materials. Journal of Endodontics 2003;29(11):743-746.
  22. Hume WR. An analysis of the release and the diffusion through dentin of eugenol from zinc oxide-eugenol mixtures. Journal of Dental Research 1984;63(6):881-884.
  23. Hume WR. The pharmacologic and toxicological properties of zinc oxide-eugenol. Journal of the American Dental Association 1986;113(5):789-791.
  24. Hume WR. In vitro studies on the local pharmacodynamics, pharmacology and toxicology of eugenol and zinc oxide-eugenol. International Endodontic Journal 1988;21(2):130-134.
  25. Morse DR. Endodontic-related inferior alveolar nerve and mental foramen paresthesia. Compendium of Continuing Education in Dentistry 1997;18(10):963-968.
  26. Ziccardi VB, Hullett JS, Gomes J. Physical neurosensory testing versus current perception threshold assessment in trigeminal nerve injuries related to dental treatment: a retrospective study. Quintessence International 2009;40(7):603-609.
  27. Scolozzi P, Lombardi T, Jaques B. Successful inferior alveolar nerve decompression for dysesthesia following endodontic treatment: report of four cases treated with mandibular sagittal osteotomy. Oral Surgery, Oral Medicine, Oral Pathology, Oral Radiology, and Endodontics 2004;97(5):625-631.
  28. Dworkin RH, O'Connor AB, Audette J *et al*. Recommendations for the pharmacological management of neuropathic pain: an overview and literature update. Mayo Clinic Proceedings 2010;85(3 Suppl):S3-14.

---

## 국문초록

### 근관 충전제의 과충전에 의한 하치조 신경손상에 관한 비수술적 치료 증례

조선대학교 치의학전문대학원 구강내과학교실<sup>1</sup>  
조선대학교 치의학전문대학원 보존학교실<sup>2</sup>

배국진<sup>1</sup> · 안종모<sup>1</sup> · 윤창륙<sup>1</sup> · 조영곤<sup>2</sup> · 유지원<sup>1</sup>

근관치료 중 수동 또는 엔진구동파일을 사용하다 과도한 기구 조작을 하게 되면, 근관충전제, 드레싱제 그리고 근관세척제가 근관에서 나와 하악관으로 확산될 수 있다. 이 때 환자는 통증, 지각과민, 지각감퇴, 무감각, 이상감각 등을 호소하게 될 것이다.

이런 문제들은 근관충전제에 포함되어 있으면서 생체적합성이 떨어지는 물질들에 의한 비가역적인 손상을 피하기 위해 가능한 빨리 해결되어야 한다. 비록 근관치료와 관련하여 발생한 하치조신경의 손상을 치료하는 진료지침이 비교연구되어 있는 것이 없으나, 이 합병증에 대한 통상의 치료는 통증과 염증을 조절하는 것이고, 가능하다면 수술적인 치료로 근원을 처치하는 것이다.

그러나, 비수술적인 치료로 통증을 완전히 개선하거나 감소시키고 또는 감각이상을 치료하는 것이 보고되어왔다. 가바펜틴(gabapentin) 또는 프리가발린(pregabalin) 같은 항간질제는 신경병증 통증의 치료에 이용되어 왔다.

이번 논문에서는 하악 우측 제 2대구치의 근관치료 후의 하치조신경의 손상과 이에 대해 프레드니솔론과 가바펜틴으로 비외과적 치료를 시행한 것과 임상적으로 신경감각검사와 신경전류인지역치검사(Neurometer)를 통해 경과관찰을 시행하였다.

**주제어** : 전류인지역치검사, 근관치료 합병증, 근관충전제, 가바펜틴, 하치조신경 손상

---