

Interim palatal lift prosthesis as a constituent of multidisciplinary approach in the treatment of velopharyngeal incompetence

Neerja Raj^{1*}, MDS, Vineet Raj², MDS, Himanshu Aeran³, MDS

¹Department of Prosthodontics, Saraswati Dental College and Hospital, Lucknow, Uttar Pradesh, India

²Department of Oral Pathology, Saraswati Dental College and Hospital, Lucknow, Uttar Pradesh, India

³Department of Prosthodontics, Seema Dental College and Hospital, Rishikesh, Uttarakhand, India

The velopharynx is a tridimensional muscular valve located between the oral and nasal cavities, consisting of the lateral and posterior pharyngeal walls and the soft palate, and controls the passage of air. Velopharyngeal insufficiency may take place when the velopharyngeal valve is unable to perform its own closing, due to a lack of tissue or lack of proper movement. Treatment options include surgical correction, prosthetic rehabilitation, and speech therapy; though optimal results often require a multidisciplinary approach for the restoration of both anatomical and physiological defect. We report a case of 56 year old male patient presenting with hypernasal speech pattern and velopharyngeal insufficiency secondary to cleft palate which had been surgically corrected 18 years ago. The patient was treated with a combination of speech therapy and palatal lift prosthesis employing interim prostheses in various phases before the insertion of definitive appliance. This phase-wise treatment plan helped to improve patient's compliance and final outcome. [J Adv Prosthodont 2012;4:243-7]

KEY WORDS: Velopharyngeal incompetence; Velopharyngeal insufficiency; Palatal lift prosthesis; Speech therapy

INTRODUCTION

Speech is a complex motor skill that involves the co-ordination of diverse muscle groups. Gross motor movements of the muscles responsible for inspiration and expiration must be coupled with intricate muscles of the larynx, soft palate, tongue and lips to produce sustained intelligible speech. A defect in the structure, position, or motor control of any element involved with the mechanical production of speech alters the quality of the sound produced. Complete palatopharyngeal closure is required for production of certain speech sounds such as plosives, while phonemes like vowels and nasal consonants require opening of the palatopharyngeal port in varying degrees.¹ The velopharynx is a tridimensional muscular valve located between the oral and nasal cavities, consisting of the lateral and posterior pharyngeal walls and the soft palate, and controls the passage of air. The velopharyngeal sphincter is composed of six muscles, five intrinsic muscles of soft palate (levator veli palatini, tensor veli palatini, musculus uvulae,

palatoglossus, and palatopharyngeus) and the superior constrictor of pharynx.² Velopharyngeal dysfunction may take place when this valve is unable to perform its own closing, due to a lack of tissue or lack of proper movement.³

Cleft palate is one of the most common causes of velopharyngeal insufficiency (VPI) accounting for more than 50% of all cases.² Other causes include trauma, tumors, surgical resections, and neuro-muscular disorders.⁴ Hypernasal speech is the most common symptom of patients with VPI which is caused due to decreased mobility or paralysis of soft palate or pharyngeal muscles. Treatment options include surgical correction, prosthetic rehabilitation, and speech therapy; though optimal results often require a multidisciplinary approach for the restoration of both anatomical and physiological defect.⁵

Palatal lift prosthesis (PLP) is a special appliance, first advocated by Gibbons and Bloomer,¹ and useful for patients with palatopharyngeal incompetence resulting from compromised motor control of the soft palate and related musculature

Corresponding author: Neerja Raj

Department of Prosthodontics, Saraswati Dental College and Hospital, 233, Tiwariganj, Faizabad Road, Chinhhat, Lucknow, 227105, Uttar Pradesh, India
Tel. 91 9336262202: e-mail, neerja_gogia@yahoo.com

Received January 18, 2012 / Last Revision February 6, 2012 / Accepted February 26, 2012

© 2012 The Korean Academy of Prosthodontics

This is an Open Access article distributed under the terms of the Creative Commons Attribution Non-Commercial License (<http://creativecommons.org/licenses/by-nc/3.0>) which permits unrestricted non-commercial use, distribution, and reproduction in any medium, provided the original work is properly cited.

as seen in conditions like myasthenia gravis, cerebrovascular accidents, traumatic brain injuries, cerebral palsies, injuries to the soft palate, and cleft palate. The appliance is used with the objective of displacing the soft palate to the level of normal palatal elevation, enabling closure by pharyngeal wall action.¹

Here we report a case of hypernasality, secondary to VPI, which was treated using multidisciplinary approach with interim PLP as an important constituent.

CASE REPORT

A 56 year old male patient reported to the department of Oral & Maxillofacial Prosthetics, Manipal College of Dental Sciences, Mangalore, India, with a chief complaint of abnormal speech pattern and difficulty in mastication. Patient gave a history of hearing impairment for which he had consulted an otolaryngologist, and was diagnosed as a case of cleft palate which was subsequently corrected surgically eighteen years ago. The patient used a hearing aid and his speech was hypernasal. Clinical examination revealed a scar tissue present in the

uvular region with incompetent soft palate and a bifid uvula (Fig. 1) which did not meet the nasopharynx on swallowing. The mandibular arch was completely edentulous while maxillary arch had both the premolars and first molar missing on the right side and the first and second molars missing on the left side (Kennedy's class II modification I). After careful examination a combination of prosthetic rehabilitation and speech therapy was planned for the patient.

The treatment started with counseling the patient about the nature, function, and limitations of the prosthesis and making him aware about the importance of periodic follow-up. A preliminary impression was made with alginate (Zelgan, Dentsply, Constance, Germany) using modified stock trays and a diagnostic cast was prepared with Type III dental stone (Gypstone, Prevest Denpro Ltd, Jammu, India). Border molding of edentulous area was done with low fusing compound (Pinnacle tracing sticks, DPI, Mumbai, India) and the soft palate was recorded in a superiorly displaced position using impression compound (Pinnacle, DPI, Mumbai, India). The secondary impression was then made using addition polysilicone (Reposil, Dentsply, Milford, USA) and definitive cast was prepared with Type IV dental stone (Kalrock, Kalabhai Karson Pvt. Ltd, Mumbai, India). Simultaneously mandibular border molding was done and final impression was made using zinc oxide eugenol (Neogenate, Septodont, Delhi, India) by conventional method.

Initially, an edentulous interim palatal plate with palatal lift extension (Fig. 2A) was fabricated using heat cure acrylic resin (DPI Heat Cure, DPI, Mumbai, India) and was given to the patient for a period of one month. This was done with the purpose of getting the patient accustomed to the feel of the prosthesis and the pressure exerted by the palatal extensions. After one month bite registration was done using bite registration paste (Reposil, Dentsply, Milford, USA) and a new interim acrylic palatal lift prosthesis replacing the missing teeth along with lower complete denture (Figs. 2B and 2C) having balanced occlusal scheme was given to the patient for another

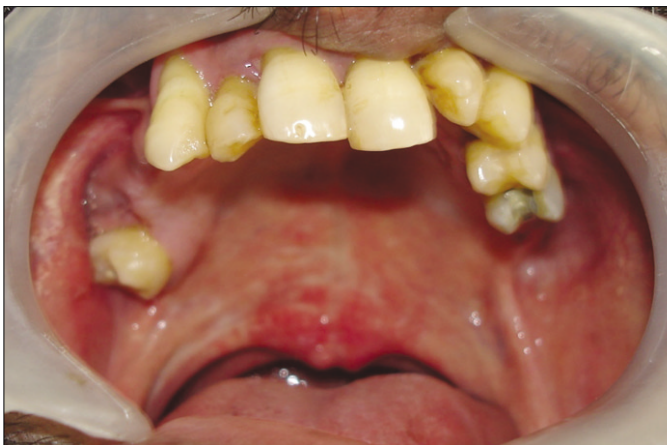

Fig. 1. Pretreatment intraoral view showing low draped soft palate with bifid uvula.

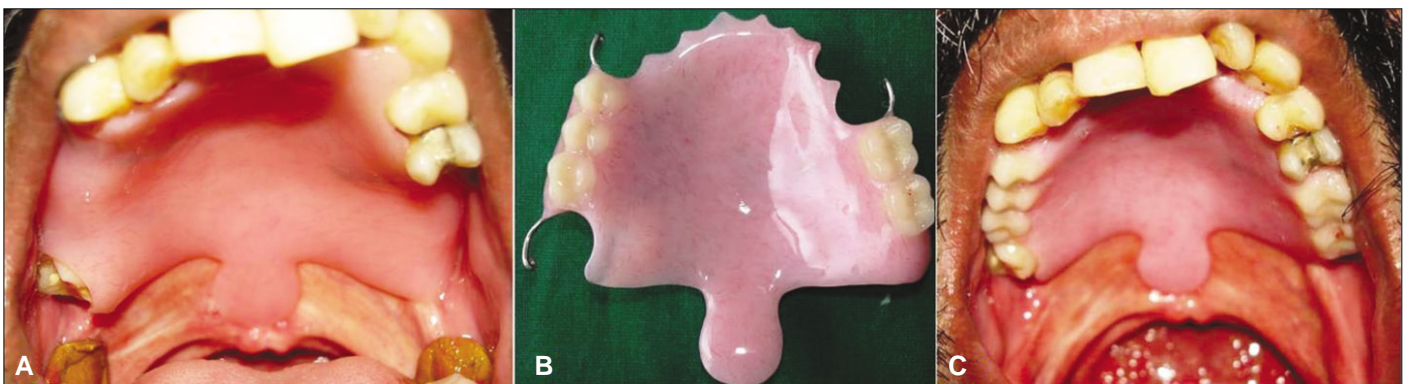


Fig. 2. A: Intra oral view of acrylic edentulous interim palatal lift appliance, B: Dentulous interim palatal lift appliance, C: Intra oral view of dentulous interim palatal lift appliance.

er two months. Patient was kept on periodic follow-up with this prosthesis. Simultaneously, the speech therapy was also started at the Department of Audiology, KMC, Attavara, and once the patient started showing satisfactory response the final cast partial palatal lift prosthesis was planned.

The diagnostic cast was surveyed and mouth preparation was done on maxillary teeth, the right and left canines, left premolars, and right second molar. Guide planes and rests seats were prepared using triangular configuration of support which is effective in neutralizing leverage. The final impression was now made by addition polyvinyl siloxane (Reprosil, Dentsply, Milford, USA) using the double mix single impression technique with rest seats being recorded by light body and remaining areas by regular body and master cast was prepared with Type IV dental stone. Metal frame work was designed to engage most of the remaining teeth to achieve additional retention and support and try-in was done in the patient's mouth (Fig. 3A). Occlusal rims were fabricated and the maxillo-mandibular relation was recorded with adequate inter-occlusal free way space. The final prosthesis was then fabricated, finished and was inserted in the patient's mouth (Fig. 3B). The patient was recalled for periodic follow-up. Audiometric analysis was periodically performed by a speech pathologist using the Temple Street Scale⁶ and change in the speech pattern was evident with the score, being reduced from pre-treatment score of 3 (moderate hypernasality - evident on high and low vowels) to post insertion score of 2 (mild/moderate hypernasality - unacceptable distortion evident on high vowels). Further improvement in speech was observed one month after insertion of the prosthesis and regular sessions of speech therapy. The patient is currently under regular follow-up.

DISCUSSION

Velopharyngeal insufficiency is defined as any malfunctioning which results in imperfect closure of the velopharyngeal apparatus. It can be either due to defect in neuromuscular function (Velopharyngeal incompetence) or due to deficit in tissue (Velopharyngeal inadequacy).⁷ In cases of surgically corrected cleft palate, the most common cause of VPI, there is an inherent deficit in tissue as well as there may be neuromuscular dysfunction due to post surgical scar tissue formation. Hence in VPI due to cleft palate, surgical treatment alone may not be sufficient for completely restoring the phonetics of the patient even after a long postsurgical period, hence the need for a multidisciplinary approach that would aim for physiological and psychological rehabilitation along with anatomical correction has been advocated.⁵

The palatal lift is a device reserved generally for patients in whom there is adequate tissue but poor control of coordination and timing of velopharyngeal movement.^{8,9} The use of a palatal lift not only acts as a passive support but may also stimulate motions of the velum, and the posterior or lateral pharyngeal wall.¹⁰ It may enhance velopharyngeal function or may even completely eliminate the symptoms of velopharyngeal deficiency so that the use of the prosthesis can be discontinued after some time.¹⁰

VPI is associated with variety of speech disorders including hypernasality, impaired articulation, and reduced oral pressures. In such cases prosthetic management may be the treatment of choice. Patient whose VPI symptoms are from flaccid, low draped soft palate incapable of movement during speech or swallowing, often benefit from use of palatal lift speech prosthesis which

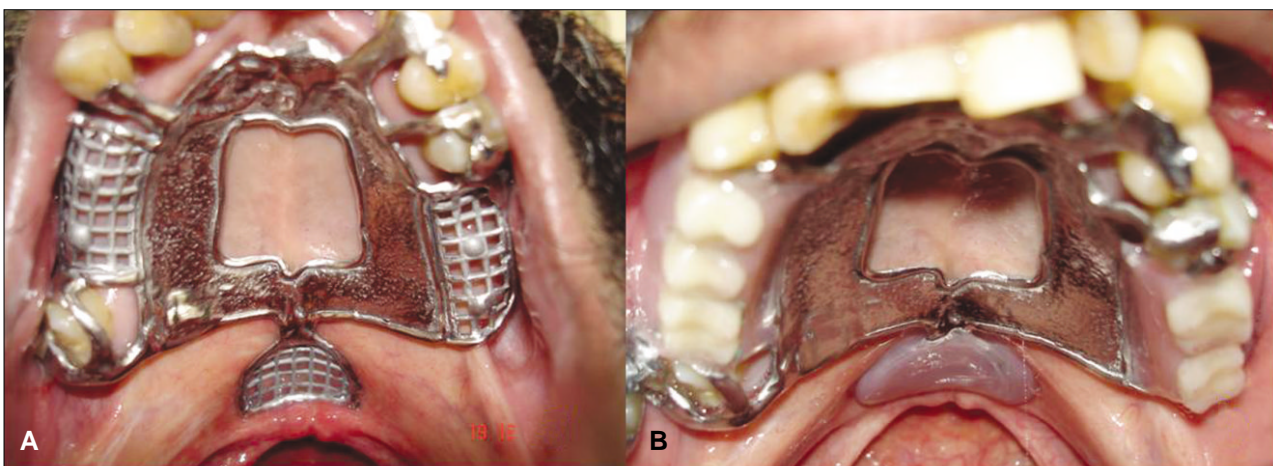


Fig. 3. A: Trial metal framework showing the palatal extension with occlusal rests on canines, premolar, and molars and direct retainers on maxillary right second molar, canine and maxillary left second premolar, B: Intraoral view of definitive palatal lift prosthesis showing considerable elevation of soft palate that will help in velopharyngeal closure.

achieves acceptable speech by elevation of soft palate in a posterior and superior direction.¹¹ Also, the palatal lift may cause changes in the neuromuscular environment of the patient's velopharynx and the simulation of resulting prosthetic may reduce disuse atrophy and enhance function.¹² It has been suggested that the use of the palatal lift for a sufficient time period may cause the palate to be held in an elevated position as the levators and other velopharyngeal muscles may assume more appropriate length.¹³ Although a cast metal palatal lift prosthesis may provide myofunctional therapeutic advantages, the patient acceptance, especially those having long standing drooped soft palate, is usually low. The reason for non-acceptance could be due to the soreness created by a strong lifting force exerted by the palatal extension. An interim palatal lift prosthesis made of polymethyl methacrylate can help the patient to get accustomed to the palatal extension in a gradual manner as the force exerted by this interim prosthesis is lesser and can be gradually increased by incrementing the palatal extension in subsequent visits.¹ As seen in this case, a phase wise treatment, using initially an edentulous interim prosthesis followed by a dentulous one before the final rehabilitation with a definitive PLP, helped to improve patient compliance both physically as well as psychologically. The edentulous interim helps the patient to adapt to the feel and mild pressure exerted by the palatal extensions before occlusal and masticatory load come into play with the use of a dentulous prosthesis. An interim PLP is also indicated for patients whose dental and maxillofacial development is incomplete. These individuals may require successive prostheses during their continued growth. Other advantages of interim PLP include lesser laboratory time and expense. Consequently, the interim prosthesis can be used initially to evaluate patient compliance, motivation, and prosthetic efficacy before embarking on a definitive treatment.

Palatal anatomy particularly that of soft palate needs special attention while planning fabrication of palatal lift appliance. A low drooping soft palate would present a greater difficulty in lifting as compared to a more horizontal palate.¹⁴ Muscular activity of palatal, pharyngeal and glossopharyngeal muscles also needs to be considered as it is desirable to have relatively normal or even hypotonic muscle tone for better results as hypertonic palatal muscles will tend to push the appliance down and may cause discomfort or soreness, leading to poor patient compliance.⁹ Presence of fibrotic scar tissue post surgery may also reduce palatal elasticity and limit the extent of lift by the appliance.

The evaluation of clinical efficacy of the appliance by an experienced speech pathologist is essential and should include assessing the resonance and nasal emission, assessment of articulation and intelligibility, and reduction in existing compensatory mechanisms like glottal stops, pharyngeal fricatives, facial grimace. Cold mirror test may be employed to assess the escape

of air through nostrils during phonation. Other methods which may provide information on the effectiveness of the appliance include lateral cephalograms, nasoendoscopy, videofluoroscopy, and aerodynamics.¹⁵ In the present case perceptual rating of hypernasality was performed using the Temple Street Scale which has been shown to demonstrate a good correlation with nasometric analysis.⁶

Maladaptive articulation when present for long time requires the combination of prosthetic as well as speech therapy.⁸ The speech compensatory mechanisms among congenital cleft patients are deep rooted habits that cannot be eliminated simply by using the palatal prosthesis.³ In cases of mild VPI and certainly in all postoperative cases, speech therapy does improve velopharyngeal function and is also important in correcting compensatory articulation habits that develop as a result of longstanding VPI.¹

CONCLUSION

A multidisciplinary approach when used for the treatment of any deep rooted pathology often gives good prognosis. As seen in this case, the combination of prosthetic and speech therapy when undertaken helped achieve satisfactory therapeutic results for the patient. The interim palatal lift prosthesis helps the patient to gradually adapt to the feel and load of the final appliance and improves patient acceptability and treatment outcome. A collaborative effort by a team consisting of maxillofacial surgeon, prosthodontist, and speech and language therapist is recommended for comprehensive management of patients having VPI.

REFERENCES

1. Curtis TA, Beumer J. Speech, palatopharyngeal function, and restoration of soft palate defects. In: Beumer J, Curtis TA, Firtell DN, editors. *Maxillofacial Rehabilitation- Prosthodontic and Surgical Consideration*. St. Louis; CV Mosby Company; 1979. p. 244-91.
2. Cotton RT, Willging JP. Velopharyngeal Insufficiency. In: Bluestone CD, Stool SE, Kenna MA, editors. *Pediatric Otolaryngology*, 3rd Edition, Philadelphia; WB Saunders Company; 1995. p. 1621-31.
3. Pinto JH, Pegoraro-Krook MI. Evaluation of palatal prosthesis for the treatment of velopharyngeal dysfunction. *J Appl Oral Sci* 2003;11:192-7.
4. Weber J Jr, Chase RA. Stress velopharyngeal incompetence in an oboe player. *Cleft Palate J* 1970;7:858-61.
5. Sell D, Mars M, Worrell E. Process and outcome study of multidisciplinary prosthetic treatment for velopharyngeal dysfunction. *Int J Lang Commun Disord* 2006;41:495-511.
6. Sweeney T, Sell D. Relationship between perceptual ratings of nasality and nasometry in children/adolescents with cleft palate and/or velopharyngeal dysfunction. *Int J Lang Commun Disord* 2008;43:265-82.
7. Loney RW, Bloem TJ. Velopharyngeal dysfunction: recommendations for use of nomenclature. *Cleft Palate J* 1987;24:334-5.
8. Witt PD, Rozelle AA, Marsh JL, Marty-Grames L, Muntz

- HR, Gay WD, Pilgram TK. Do palatal lift prostheses stimulate velopharyngeal neuromuscular activity? *Cleft Palate Craniofac J* 1995;32:469-75.
9. La Velle WE, Hardy JC. Palatal lift prostheses for treatment of palatopharyngeal incompetence. *J Prosthet Dent* 1979;42:308-15.
 10. Beery QC, Rood SR, Schramm VL Jr. Pharyngeal wall motion in prosthetically managed cleft palate adults. *Cleft Palate J* 1983;20:7-17.
 11. Karnell MP, Rosenstein H, Fine L. Nasal videoendoscopy in prosthetic management of palatopharyngeal dysfunction. *J Prosthet Dent* 1987;58:479-84.
 12. Mazaheri M, Mazaheri EH. Prosthodontic aspects of palatal elevation and palatopharyngeal stimulation. *J Prosthet Dent* 1976;35:319-26.
 13. Hardy JC, Netsell R, Schweiger JW, Morris HL. Management of VP dysfunction in cerebral palsy. *J Speech Hear Disord* 1969;34:123-37.
 14. Eckert SE, Desjardins RP, Taylor TD. Clinical Management of the Soft Palate Defect. In: Taylor TD, editor. *Clinical Maxillofacial Prosthetics*. Chicago; Quintessence Publishing Co, Inc; 2000. p. 121-31.
 15. Crockett DM. Velopharyngeal incompetence. In: Healy GB, editors. *Common Problems in Pediatric Otolaryngology-Head and Neck Surgery*. London; Year Book Medical Publisher; 1990. p. 275-88.