

RESEARCH COMMUNICATION

Clinical Significance of Axin and β -catenin Protein Expression in Primary Hepatocellular Carcinomas

Cheng-Nong Guan*, Xin-Ming Chen, Hai-Qing Lou, Xiang-Hui Liao, Bao-Ying Chen, Pei-Weng Zhang

Abstract

The aim of the present research was to investigate clinicopathologic correlations of immunohistochemically-demonstrated axin (axis inhibition) and β -catenin expression in primary hepatocellular carcinomas (HCCs), in comparison with paraneoplastic, cirrhotic and normal liver tissues. Variation in Axin expression across groups were significant ($P < 0.01$), correlating with alpha fetoprotein (AFP), HBsAg, cancer plugs in the portal vein, and clinical stage of HCCs ($P < 0.05$); however, there were no links with sex, age, and tumour size ($P > 0.05$). Differences in cell membrane β -catenin expression were also statistically significant ($P < 0.01$), again correlated with AFP, HBsAg, cancer plugs in the portal vein, and clinical stage in HCCs ($P < 0.05$) but not with sex, age, and tumour size ($P > 0.05$). Axin expression levels in tissues with reduced membrane β -catenin were low ($P < 0.05$), also being low with nuclear β -catenin expression ($P < 0.05$). Axin and β -catenin may play an important role in the genesis and progression of HCC via the Wnt signal transmission pathway. Simultaneous determination of axin, β -catenin, AFP, and HBsAg may be useful for early diagnosis, and metastatic and clinical staging of HCCs.

Keywords: Axin - β -catenin - hepatocellular - immunohistochemistry

Asian Pacific J Cancer Prev, **13**, 677-681

Introduction

The Wnt signal transduction pathway is composed of a series of cancer genes and tumour-suppressor genes that encodes proteins that contact each other and form a complex signal transmission network. Abnormalities in signal transduction are closely related to tumours and abnormal embryonic development (Kikuchi, 1999). Axin is a tumour-suppressor gene discovered through mice gene fusion (Zeng et al., 1997). As a structural protein, Axin binds many important members of the Wnt signal transduction pathway, participates in many regulatory processes in signal transmission pathways, and plays a key role in individual development, cell proliferation, and carcinogenesis (Luo and Lin, 2004). β -Catenin is an important intracellular glycoprotein. Coding genetic mutations, abnormal protein expression, and ectopic of β -catenin are related closely with tumourigenesis or metastasis. Abnormal β -catenin expression mediates the abnormal activation of the Wnt signalling pathways, transforming membrane β -catenin into cytoplasmic and nuclear β -catenin; this increase in nuclear β -catenin levels activates target genes, initiates the cell cycle, and promotes cell hyperplasia, which eventually leads to tumour formation (Hasegawa et al., 2001).

The relationships between Axin and β -catenin expression and hepatocellular carcinoma (HCC), as well

as their correlation with the clinical and pathological features have not been reported.

Materials and Methods

Specimen

For the HCC specimens, 30 samples were obtained from the Affiliated Hospital of Guangzhou Medical College from July 2007 to December 2010. The patients did not receive any treatment, such as radiation, chemotherapy, microwave knife, and interventions, before the operation. The medical records were intact and all cases were pathologically confirmed as HCC. Cancerous and normal tissues (2 cm to 5 cm from the tumour edge, as confirmed through histopathology) of each patient were collected, fixed in formalin, paraffin-embedded, and cut into 4 μ m thick slices. A total of 30 patients, including 18 males and 12 females, with ages between 29 and 75 years old and an average of 50.5 years were enrolled into the study. Among them, 21 were HBsAg (+) and 22 had alpha fetoprotein (AFP) ≥ 400 ng/ml. The clinical staging were as follows: 12 cases were in stage I, 7 cases were in stage II, 11 cases were in stage III, 16 cases were from portal venous tumour emboli, 3 cases were from splenic metastasis, and 4 cases were distant metastasis.

For the cirrhosis specimen: A total of 25 liver cirrhosis samples were obtained from the liver biopsies of

Department of Oncology, the Affiliated Hospital of Guangdong Medical College, Zhanjiang, China *For correspondence: chengnongguancn@163.com

patients at the Affiliated Hospital of Guangzhou Medical College from July 2007 to December 2010, which were pathologically confirmed as cirrhosis.

Immunohistochemistry

The excised tissues were fixed with 10% formalin and embedded in paraffin, and 4 μ m thick slices were created from each sample. After dewaxing, debenzolization, and hydration, the expression of Axin and β -catenin were detected via the streptavidin-peroxidase method. The primary antibodies were rabbit anti-human Axin human polyclonal antibodies (1:50) and rabbit anti-human β -catenin monoclonal antibodies (1:600). PBS was used as the negative control and normal liver tissue was used as the positive control. Antigens dyed as palm or brown were considered positive results.

The results were judged as follows: (1) normal positive Axin expression mainly localized in the cytoplasm as yellowish-brown particle sediment. The tissue expression of positive and negative standards was performed according to the method by Nakajima et al. (2003) with minor modifications, i.e., according to the sum of the cell staining intensity and stained cell proportion: 1) Staining intensity score: no staining was given a score of zero, mild staining was given a one, moderate staining was given a two, and highly stained specimens were given a three. 2) Staining area score: no cell staining was assigned a score of zero, cell staining < 25% was given a one, cell staining from 25% to 50% was given a two, cell staining >50% was given a three. If the sum of above two scores is ≥ 2 , the result was considered positive and those with <2 were negative. (2) Normal positive β -catenin expression was located on the cell membrane, and distributed along the cell membrane continuity as small brown granules. The criteria were according to Pirinen (Pirinen et al., 2001). A total of 10 high magnification fields were randomly selected from each section, and 100 tumour cells were counted from every field. The continuity of staining was observed and the percentage of positive cells was calculated. Cells with no colouring were treated as negative (-); discontinuous membrane staining and membrane-positive tumour cells <90% was considered

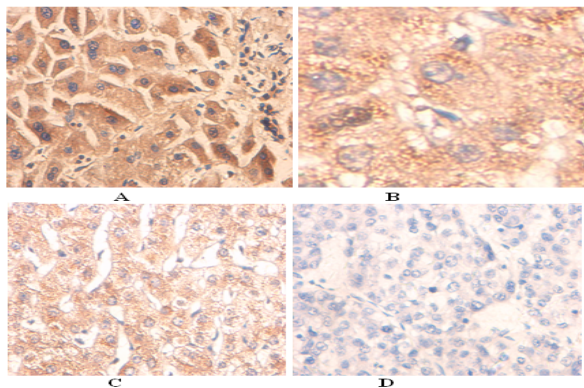


Figure 1. Axin Protein Expression in Different Liver Tissues. A. Axin protein expression in the normal liver tissue (highly positive expression, SPx400); B. Axin protein expression in the liver cirrhosis (weak positive expression, SPx400); C. Axin protein expression in the liver paracancer tissues (highly positive expression, SPx400); D. Axin protein expression in the hepatocellular carcinoma (negative expression, SPx400)

Table 1. Axin Protein Expression in Different Liver Tissues

Group	N	Axin staining degree		Positive rate (%)
		Negative	Positive	
normal ¹	20	3	17	85
liver cirrhosis ²	25	2	23	92
paracancer ³	30	3	27	90
carcinoma ⁴	30	20	10	33.3

Note: 2 to 1 $X^2=0.714$ $P=0.398$; 4 to 1 $X^2=8.598$ $P=0.003$; 3 to 1 $X^2=0.009$ $P=0.923$; 4 to 2 $X^2=9.000$ $P=0.002$; 3 to 2 $X^2=0.655$ $P=0.419$; 4 to 3 $X^2=20.37$ $P<0.001$

as decreased membrane expression, whereas continuous cell membrane staining and membrane-positive tumour cells >90% were considered normal membrane expression. If more than 10% of the cells were tumour cells under nuclear staining, the result was considered positive nuclear expression, whereas no staining represented decreased membrane expression or abnormal positive nuclear expression.

Statistical analysis

The data was analysed using SPSS13.0 package. The relationship between Axin and β -catenin expression levels and the clinical and pathologic features of HCC was analysed using Pearson's χ^2 test and Spearman's related analysis and statistical method. Differences with $P < 0.05$ were considered statistically significant.

Results

Axin protein expression

As shown in Figure 1, Axin is positively expressed in most liver paracancers, liver cirrhosis, and normal liver tissues (most of the cytoplasm was yellowish-brown particles), and was not expressed in most of the cytoplasm of HCC tissue (most of the cytoplasm is without or with only a small amount of yellowish-brown particles). The positive expression rate of Axin in HCC was significantly lower than the rate in liver paracancers, liver cirrhosis, and normal liver tissue, which showed significant differences ($P < 0.01$; Table 1).

The relationship between Axin protein expression and the clinicopathologic features of HCC

The positive frequency of Axin protein expression in the AFP ≥ 400 ng/ml and <HBsAg (+) group was less than that in the AFP <400 ng/ml HBsAg (-) group; the difference was statistically significant ($P < 0.05$). In the HCC with and without portal venous tumour thrombi, the positive Axin expression rates were 12.5% (2/16) and 57.1% (8/12), respectively. The difference was statistically significant ($P < 0.01$). Among the stages I-II and stage III HCC patients, the positive Axin expression rates were 47.4 (9/19) and 9.09% (1/11), respectively. The difference was statistically significant ($P < 0.05$). No relationship was observed between Axin protein expression and patient gender, age, and tumour size ($P > 0.05$; Table 2).

β -Catenin protein expression in liver tissue

As shown in Figure 2, the β -catenin is expressed

Table 2. The Relationship Between Axin Protein Expression and Hepatocellular Carcinoma Clinical Pathological Features

Group	N	β -catenin staining degree		Positive rate(%)	χ^2	P value
		Negative cases	Positive cases			
Gender						
Male	18	12	6	33.3	0	1
Female	12	8	4	33.3		
Age						
<50	13	7	6	46.2	1.697	0.193
\geq 50	17	13	4	23.5		
Tumor size						
<5	11	9	2	18.2	1.794	0.18
\geq 5	19	11	8	42.1		
AFP(ng/ml)						
<400	8	2	6	75	8.523	0.004
\geq 400	22	18	4	18.2		
HBsAg						
(+)	21	17	4	19.1	6.429	0.012
(-)	9	3	6	66.7		
Portal venous tumor thrombus						
No	14	6	8	57.1	6.696	0.009
Yes	16	14	2	12.5		
Clinical stage						
I-II	19	10	9	47.4	4.953	0.032
III	11	10	1	9.1		

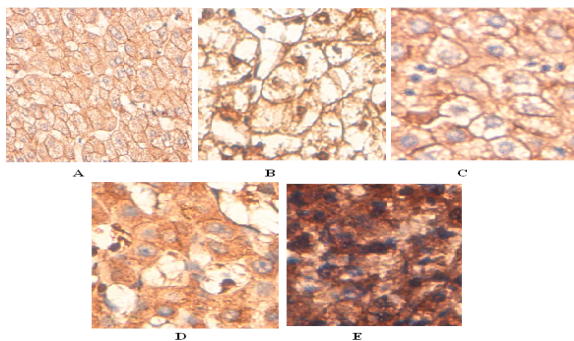


Figure 2. β -catenin Protein Expression in Different Liver Tissues. A. β -catenin protein expression in the normal liver tissue (SP \times 400); B. β -catenin protein expression in the liver cirrhosis (SP \times 400); C. β -catenin protein expression in the liver paracancer tissues (SP \times 400); D. β -catenin protein expression in the hepatocellular carcinoma (cell membrane discontinuous, rupture, cytoplasm weak expression, SP \times 400); E. β -catenin protein expression in cytoplasm and nuclei (SP \times 400)

normally in the cellular membrane of most liver paracancer tissues, liver cirrhosis, and normal liver tissue (most of the cell membranes have yellowish-brown particles), and has lower expression levels in most cellular membranes of HCC tissue, i.e., most of the cell membranes are discontinuous and ruptured, And their cytoplasm and nuclei show yellowish-brown particles). The reduction in membrane β -catenin expression in HCC was significantly higher than that in paracancer, liver cirrhosis, and normal liver tissue; the difference was statistically significant ($P < 0.01$; Table 3).

The relationship between β -catenin expression and the clinicopathologic features of HCC

The membrane β -catenin expression rates in the AFP \geq 400 ng/ml and <HBsAg (+) group was less than that in

Table 3. β -catenin Protein Expression in Different Liver Tissues

Group	N	β -catenin expression		Membrane decreasing rate(%)
		Membrane normal	Membran decreasing	
normal ¹	20	17	3	15
liver cirrhosis ²	25	21	4	16
paracancer ³	30	17	13	40.3
carcinoma ⁴	30	6	24	80

Note: 2 to 1 $X^2=0.096 P>0.05$; 4 to 1 $X^2=14.28 P<0.05$; 3 to 1 $X^2=3.124 P>0.05$; 4 to 2 $X^2=9.452 P<0.05$; 3 to 2 $X^2=1.496 P>0.05$; 4 to 3 $X^2=8.531 P<0.05$

Table 4. The Relationship Between β -catenin Protein Expression and Hepatocellular Carcinoma Clinical Pathological Features

Group	N	β -catenin staining degree		Positive rate(%)	χ^2	P value
		Negative cases	Positive cases			
Gender						
Male	18	4	14	77.8	0.139	0.709
Female	12	2	10	83.3		
Age						
<50	13	2	11	84.6	0.305	0.581
\geq 50	17	4	13	76.5		
Tumor size						
<5	11	4	7	63.6	2.907	0.088
\geq 5	19	2	17	89.5		
AFP(ng/ml)						
<400	8	4	4	50	6.136	0.013
\geq 400	22	2	20	90.9		
HBsAg						
(+)	21	2	19	90.5	4.802	0.028
(-)	9	4	5	55.6		
Portal venous tumor thrombus						
No	14	5	9	64.3	4.051	0.044
Yes	16	1	15	93.8		
Clinical stage						
I-II	19	6	13	68.4	4.342	0.037
III	11	0	11	100		

the AFP < 400 ng/ml and HBsAg (-) group; the difference was statistically significant ($P < 0.05$). In the HCC with and without portal venous tumour thrombi in HCC, the membrane β -catenin expression rates were 93.8% (15/16) and 64.3% (9/14), respectively; the difference was statistically significant ($P < 0.05$). In the stages I-II and stage III HCC patients, the membrane β -catenin expression rates were 68.4 (13/19) and 100.0% (11/11); the difference was statistically significant ($P < 0.05$). There was no relationship between the abnormal membrane β -catenin expression and patient gender, age, and tumour size ($P > 0.05$; Table 4).

Relationship between Axin and β -catenin protein expression in HCC

In patients with lower β -catenin protein membrane expression, the positive Axin protein expression rate was 25.0% (6/24), which is less than that in normal cases 66.7% (4/6). There was a positive correlation between abnormal Axin expression and abnormal membrane β -catenin expression ($R_s = 0.354, P < 0.05$). In the cases with positive nuclear β -catenin expression, the Axin

Table 5. Relationship Between Axin and Beta-catenin Protein Expressions in Hepatocellular Carcinoma

β -catenin	Axin		Total
	Negative	Positive	
Membrane normal	2	4	6
Membrane decreasing			
Nucleic negative	7	5	24
Nucleic positive	11	1	
Total	20	10	30

expression rate was 8.3% (1/12), which is less than that in the negative cases 41.7% (5/12). There was a negative correlation between abnormal Axin expression and nuclear β -catenin expression (Rs = 0.385, P < 0.05; Table 5).

Discussion

The Wnt signal transduction pathway was discovered in the genetic analysis of fly polarity development and *Xenopus laevis* embryonic axiation, which plays an important regulatory role in cell proliferation, cell morphology, cell adhesion, cell movement, and body development and differentiation (Kikuchi et al., 1999). As a structural protein in the Wnt signalling pathway, Axin can assemble APC, GSK-3 β , β -catenin, and CKI α to form the β -catenin degradation complex that promotes β -catenin phosphorylation and degradation (Hino et al., 2003). Normally, cytoplasmic CKI α and GSK-3 β phosphorylates β -catenin. The phosphorylated β -catenin is then identified by ubiquitin and ubiquitination, and is then hydrolysed by the protease complex. Therefore, the β -catenin cells are always maintained at a low level (Liu et al., 2002).

The mechanism of the abnormal Axin expression that causes tumorigenesis is not completely clear. Wnt, JNK signal, and p53 expression are mainly involved in carcinogenesis: 1) Axin protein expression is reduced, and the activation of target genes related closely with carcinogenesis in Wnt signalling pathways (c-myc, cyclinD1, MMP-7) may decrease (Takahashi et al., 2002); 2) Axin combines with MEKK1 and activates the downstream factor MEKK4 and MEKK7, which cause further activation of the JNK signalling pathway. Axin induces by activating the JNK signalling system and reducing β -catenin (Neo et al., 2000); 3) mice and *X. laevis* embryonic axiation develop abnormally with Axin mutations, which indicates that Axin plays an important regulatory role in embryonic development (Zeng et al., 1997); 4) Axin activates p53 through HIPK2 (Rui et al., 2004).

The results of the present study show that the expression of Axin in HCC is significantly lower than in liver paracancer, liver cirrhosis, and normal liver tissue (P < 0.01); this suggests that abnormal Axin expression is related to hepatocellular carcinogenesis.

The differences in Axin expression between HCC with and without portal venous tumour thrombi, and among stages I, II, and III HCC patients, were statistically significant (P < 0.05), which suggests a relationship between abnormal Axin expression and liver cancer portal venous thrombus formation and clinical stage, wherein the

late clinical stages have lower positive expression rates.

β -Catenin is an important intracellular glycoprotein that participates in cell adhesion and plays an important role in the Wnt signal transduction pathway. When cytoplasmic free β -catenin exceeds the APC degradation capacity, the redundant β -catenin enters the nucleus to activate the Wnt signalling pathway, initiates the transcription of target genes, such as c-myc, cyclinD1, and so on, and causes cell proliferation, invasion, and metastasis (Karim et al., 2004). Some reports found abnormal β -catenin expression in a wide variety of tumour; however, the expression rate in different tumours were also different (Ashibara et al., 2002; Ueta et al., 2002). The reduction in membrane β -catenin expression in HCC was significantly higher than that in paracancer, liver cirrhosis, and normal liver tissue; the difference was statistically significant (P < 0.01), which suggests a relationship between abnormal β -catenin expression and HCC, with β -catenin protein accumulating in the nuclei of HCC cells. In HCC with and without portal venous tumour thrombi, as well as stages I, II, and III HCC patients, the differences in membrane β -catenin expression were statistically significant (P < 0.05), suggesting that there was a relationship between abnormal membrane β -catenin expression and liver cancer portal venous thrombus formation and clinical stage.

A melanoma cell study found that increased β -catenin protein is mainly related with its own mutations, wherein the β -catenin mutations can increase its stability and make it non-degradable. When cytoplasmic free β -catenin cannot be timely degraded, β -catenin starts to accumulate, and the excessive accumulation of β -catenin is transferred to the cell nucleus, which initiates the transcription of target genes, such as c-myc, cyclinD1, and so on, and causes cell proliferation, invasion, and metastasis. Therefore, abnormal β -catenin expression in HCC and its nuclear accumulation may be caused by decreased β -catenin degradation.

In patients with reduced β -catenin membrane protein expression, positive Axin expression was lower than that in cases with normal membrane β -catenin expression. There was a positive correlation between abnormal Axin expression and abnormal membrane β -catenin expression. There was a negative correlation between abnormal Axin expression and nuclear β -catenin expression. The results suggested that Axin expression downregulates nuclear β -catenin accumulation, and may inhibit tumour cell differentiation and proliferation. The reduction in Axin expression may result in uncontrolled nuclear β -catenin accumulation, and activates the downstream target genes, which leads to tumour formation.

Axin has different mutation frequencies in colon cancer (Jin et al., 2003) and bladder tumour tissue (Daa et al., 2004). In Axin gene mutations in primary HCC cells, β -catenin accumulation was found in the cytoplasm and the nucleus, and β -catenin/Tcf transcription activity was enhanced. When adenoviral vectors were used to transfect the wild-type Axin gene, the accumulated β -catenin was reduced significantly because of APC in the HCC cells or Axin mutation. However, the amount of accumulated β -catenin protein did not change in the HCC cells with

β -catenin mutations, but the amount of β -catenin in the nucleus was reduced significantly and the HCC cell apoptosis rate was increased.

The present study also shows that abnormal Axin expression was negatively correlated significantly with nuclear β -catenin expression. This result suggests that functional Axin mutations may be one of the aetiologies of liver carcinogenesis. Axin mutation disrupts the APC binding site for Axin, which removes the ability of APC to promote β -catenin degradation when cytoplasmic free β -catenin exceeds APC degradation. The β -catenin in liver tissue cells accumulate and excess β -catenin protein is transferred to the nucleus, which binds to the LEF/TCF nuclear transcription factor family members to stimulate the expression of cancer genes, such as c-myc, cyclinD1, fra-1, c-jun, causing abnormal cellular proliferation that eventually causes liver cells to become cancerous.

In HCC, the differences in Axin expression, as well as in membrane β -catenin expression among the AFP \geq 400 ng/ml, the HBsAg (+) < 400 ng/AFP < ml, and the HBsAg (-) group were statistically significant ($P < 0.05$). This result showed that Axin and abnormal β -catenin protein expression are closely related with AFP level and HBsAg, and can be used as a clinical diagnostic index for HCC.

In summary, Axin and abnormal β -catenin expression in HCC organization may participate in hepatocellular carcinogenesis and development. Axin and β -catenin causes liver cell carcinogenesis through the Wnt signal transduction pathways. Differences in Axin and β -catenin expression are related to the AFP level, HbsAg, portal tumour, portal venous tumour thrombus formation, and the clinical stage in HCC patients, which indicates that a combined test for Axin, β -catenin protein AFP, HbsAg, and others can be used for the early diagnosis, metastatic and clinical staging of HCC.

Acknowledgements

This study was supported by Industrial Technology Research and Development Funds, Guangdong Province (No: 2007B031513002).

References

- Ashibara K, Saito T, Mizumoto H, et al (2002). Mutation of beta-catenin gene in endometrial cancer but not in associated hyperplasia. *Med Electron Microsc*, **35**, 9-15.
- Daa T, Kashima K, Kaku N, et al (2004). Mutations in components of the Wnt signaling pathway in adenoid cystic carcinoma. *Mod Pathol*, **17**, 1475-82.
- Hasegawa T, Yokoyama R, Matsuno Y, et al (2001). Prognostic significance of histologic grade and nuclear expression of beta-catenin in synovial sarcoma. *Hum Pathol*, **32**, 257-63.
- Hino S, Michiue T, Asashima M, et al (2003). Casein kinase I epsilon enhances the binding of Dvl-1 to Frat-1 and is essential for Wnt-3a-induced accumulation of beta-catenin. *J Biol Chem*, **278**, 14066-73.
- Jin L H, Shao QJ, Luo W, et al (2003). Detection of point mutations of the Axin1 gene in colorectal cancers. *Int J Cancer*, **107**, 696-9.
- Karim R, Tse G, Putti T, et al (2004). The significance of the Wnt pathway in the patho-logy of human cancers. *Pathology*, **369**, 120-8.

- Kikuchi A (1999). Roles of Axin in the Wnt signalling pathway. *Cell Signal*, **11**, 777-88.
- Liu C, Li Y, Semenov M, et al (2002). Control of beta-catenin phosphorylation/degradation by a Dual-kinase mechanism. *Cell*, **108**, 837-47.
- Luo W, Lin SC (2004). Axin: a master scaffold for multiple signaling pathways. *Neurosignals*, **13**, 99-113.
- Nakajima M, Fukuchi M, Miyazaki T, et al (2003). Reduced expression of Axin correlates with tumour progression of oesophageal squamous cell carcinoma. *Br J Cancer*, **88**, 1734-9.
- Neo SY, Zhang Y, Yaw LP, et al (2000). Axin-induced apoptosis depends on the extent of its JNK activation and its ability to down-regulate beta-catenin levels. *Biochem Biophys Res Commun*, **272**, 144-50.
- Pirinen RT, Hirvikoski P, Johansson RT, et al (2001). Reduced expression of α -catenin, β -catenin, and γ -catenin is associated with high cell proliferative activity and poor differentiation in nonsmall cell lung cancer. *J Clin Pathol*, **54**, 391-5.
- Rubinfeld B, Robbins P, EL-Gamil M, et al (1997). Stailization of β -catenin by genetic defects in melanoma cell line. *Science*, **275**, 1790-2.
- Rui Y, Xu Z, Lin S, et al (2004). Axin stimulates p53 functions by activation of HIPK2 kinase through Multimeric complex formation. *EMBO J*, **23**, 4583-94.
- Satoh S, Daigo Y, Furukawa Y, et al (2000). AXIN1 mutations in hepatocellular carcinomas, and growth suppression in cancer cells by virus-mediated transfer of AXIN1. *Nat Genet*, **24**, 245-50.
- Takahashi M, Tsunoda T, Seiki M, et al (2002). Identification of membrane-type matrix metalloproteinase-1 as a target of the beta-catenin/Tcf4 complex in human colorectal cancers. *Oncogene*, **21**, 5861-7.
- Ueta T, Ikeguchi M, Hirooka Y, et al (2002). Beta-catenin and cyclin D1 expression in human hepatocellular carcinoma. *Oncol Rep*, **9**, 1197-203.
- Zeng L, Fagotto F, Zhang T, et al (1997). The mouse Fused locus encodes Axin, an inhibitor of the Wnt signaling pathway that regulates embryonic axis formation. *Cell*, **90**, 181-92.
- Zeng L, Fagotto F, Zhang T, et al (1997). The mouse Fused locus encodes Axin, an inhibitor of the Wnt signaling pathway that regulates embryonic axin formation. *Cell*, **90**, 181-92.