

Clinical Article

Decompressive Hemicraniectomy and Duroplasty in Toddlers and Preschool Children with Refractory Intracranial Hypertension after Unilateral Hemispheric Stroke

Sang-Kook Lee, M.D., Sang-Dae Kim, M.D., Se-Hoon Kim, M.D., Dong-Jun Lim, M.D., Jung-Yul Park, M.D.

Department of Neurosurgery, Korea University Ansan Hospital, Ansan, Korea

Objective : Life-threatening hemispheric stroke is associated with a high mortality and morbidity. Decompressive hemicraniectomy has been regarded as an effective treatment option for refractory intracranial hypertension. Here, we reported the clinical course of 5 children with decompressive craniectomy and duroplasty after non-traumatic refractory intracranial hypertension.

Methods : Four toddlers and one preschool-girl were included in this study; there were 3 boys and 2 girls with a mean age of 34.6 months (range 17-80). Decompressive craniectomy including duroplasty was performed in cases of dilatation of pupil size after intensified standard medical therapy had proven insufficient. All children had a Pediatric Glasgow Coma Scale score <8 at pre-operation state. The mean time-point of craniectomy after stroke attack was 12 hours (range 4-19).

Results : During the long-term follow-up period (mean 47.6 months), no children died. One year later, when we checked their Glasgow Outcome Scale scores, only one toddler received a score of 4 (moderate disability). But the others had good recoveries although they had minor physical or mental deficits. According to the Pediatric Cerebral Performance Category Scale, 4 children received a score of 2 (mild disability).

Conclusion : Despite our small cases, we suggest that decompressive hemicraniectomy and duroplasty is an acceptable and life-saving treatment for refractory intracranial hypertension after unilateral hemispheric stroke in toddlers and preschool children.

Key Words : Decompressive craniectomy · Stroke · Pediatric · Outcome.

INTRODUCTION

Stroke is rare in children, however, a common cause of neurological disease, and it is a major cause of death ranks in the top ten in pediatric period^{11,15}. Documented incidence has been reported as 2.5-8/100000 children/year^{12,13}.

Medical treatment includes maintaining cerebral perfusion pressure with hyperventilation and osmotherapy, barbiturate coma and in case of thrombotic ischemia, thrombolytic procedure, and anticoagulant therapy. However, if all medical treatment is fail to drop the intracranial pressure (ICP) and deterioration of patient progressed, alternative treatments, such as surgical decompression could be mandatory.

The common rationale of decompressive craniectomy with or without duroplasty is to let the volume expansion of the swelling brain to extracranial space via removed skull flap and prevent cerebral herniation and secondary damage of brain parenchyme.

In case of traumatic brain injury, decompressive craniotomy for pediatric patient has been reported²⁰. However, there has not been a definite evidence or standard guideline for decompressive craniectomy for pediatric patient with non-traumatic acute stroke with uncontrolled refractory high intracranial pressure.

We will introduce our series about the functional and clinical outcome after decompressive craniectomy to control refractory high ICP due to non-traumatic acute stroke in pediatric patient.

• Received : November 17, 2011 • Revised : January 25, 2012 • Accepted : February 24, 2012

• Address for reprints : Sang-Dae Kim, M.D.

• Department of Neurosurgery, Korea University Ansan Hospital, 123 Jeokgeum-ro, Danwon-gu, Ansan 425-707, Korea

• Tel : +82-31-412-5053, Fax : +82-31-412-5054, E-mail : neuron19@korea.ac.kr

• This is an Open Access article distributed under the terms of the Creative Commons Attribution Non-Commercial License (<http://creativecommons.org/licenses/by-nc/3.0>) which permits unrestricted non-commercial use, distribution, and reproduction in any medium, provided the original work is properly cited.

MATERIALS AND METHODS

Between March 2004 and December 2006, decompressive hemicraniectomy and duroplasty was performed in 5 toddlers and preschool children with non-traumatic, malignant refractory high ICP. Patient characteristics and outcome were summarized in Table 1.

Any patient have no trauma history, and refractory high ICP was diagnosed as clinical evidence of acute stroke, massive infarction or hemorrhage with midline shift, compression of basal cisterns in conventional radiologic examination such as computed tomography (CT) and magnetic resonance image (MRI) and, neurological deterioration consisting of decreased level of consciousness or increasing levels of sedation, or somnolence or stupor compared with baseline status at admission¹⁷⁾. And we regard sustained refractory high ICP as a failure of intensified standard medical therapy.

All operations were performed by one pediatric neurosurgeon and all patients received treatment in pediatric intensive care unit of one medical center.

Medical treatment

In all patients, CT or MRI was obtained immediately, after stabilization of ventilation and hemodynamics at first. Blood sugar, body temperature, ventilation/oxygenation, blood volume and trans-cutaneous oxygen saturation, arterial blood pressure was continuously monitored and controlled in pediatric intensive care unit. Clinical and neurologic status was evaluated with the Glasgow Coma Scale (GCS). To reduce ICP, hyperosmolar therapy is typically begun with use of osmotic diuretics such as mannitol as needed.

Decompressive craniectomy was performed in cases of failure of intensified standard medical therapy.

Surgical protocol

Craniectomy involved the removal of a large bone flap ipsilateral to the involved hemisphere including frontal, parietal, and temporal bone.

er to the involved hemisphere including frontal, parietal, and temporal bone.

A large skin flap was lifted from the skull with meticulous blood control, multiple burr holes were made, large bone flap removed. In the temporal region, the craniectomies were extended toward the floor of the middle fossa to maximize decompression. Multiple openings in the dura were made; a dural patch was placed and sutured. In every case, intra-cerebral pressure monitor probe was positioned epidural space of bone margin.

The bone flaps were stored in a bone bank and then, following improvement of clinical and neurologic status, cranioplasty was performed 3 to 6 months later.

Neurological outcomes were evaluated using neurological examinations. Glasgow Outcome Scale (GOS)⁵⁾, and Pediatric Cerebral Performance Category Scale (PCPCS)⁴⁾ (Table 2) calculated every 6 months after discharge.

RESULTS

Five pediatric patients were treated with decompressive hemicraniectomy with duroplasty for non-traumatic and refractory intracranial hypertension after unilateral hemispheric stroke. Four patients were toddler and one patient was pre-school girl. Three were boy and two were girl. The mean age was 34.6 months old (range 17-80 months).

Four cases were caused by ischemic stroke, and another one case was hemorrhagic stroke. One case of hemorrhagic stroke, patient had been diagnosed by thrombocytopenia. One case of ischemic stroke, patient had atrial septal defect (ASD). And including this patient three cases of ischemic stroke patients were taken angiography; however there was no abnormal findings in angiography. In all patients, conventional laboratory result and special serum anti-body test, including anti-phospholipid antibody were within normal range. At the time of operation, all patients had a GCS score <8 (median 7, range 6-8) and all patients had unilateral mydriasis. Surgical decompressive hemicraniectomy

Table 1. Patient characteristics and outcome

Case No.	Sex/Age (months)	Etiology	Pre-operative GCS score	Pre-operative Pupil status	Time point of operation (hour)	Duration of follow up (months)	PCPCS score at post operative 3 years	GOS score	Neurologic deficit or sequelae
1	M/33	Right middle cerebral artery territory infarction	6	Right side mydriasis	19	36	2	5	Mild left hemiparesis, Behavioral disorders & strabismus
2	F/17	Embolic hemorrhagic infarction atrial septal defect	7	Right side mydriasis	5	41	2	5	Mild left side hemiparesis, Behavioral disorders & strabismus
3	M/26	Left MCA territory infarction	6	Left side mydriasis	18	68	3	4	Mild right side hemiparesis, cognitive disorders, hydrocephalus
4	M/17	Left basal ganglia, infarction	8	Left side mydriasis	14	38	2	5	Mild right side hemiparesis, behavioral disorders
5	F/80	Intra cerebral hemorrhage basal ganglia, thrombocytopenia	8	Right side mydriasis	4	55	2	5	Mild left side hemiparesis

GCS : Glasgow Coma Scale, PCPCS : Pediatric Cerebral Performance Category Scale, GOS : Glasgow Outcome Scale, MCA : middle cerebral artery

Table 2. Pediatric Cerebral Performance Category Scale (PCPCS)

Score	Category	Clinical feature
1	Normal	<ul style="list-style-type: none"> • Normal at age appropriate level • School age child attends regular school classroom
2	Mild disability	<ul style="list-style-type: none"> • Conscious alert and able to interact at an age appropriate level • School age child attending regular school classroom but grade perhaps not appropriate for age • May have a mild neurologic deficit
3	Moderate disability	<ul style="list-style-type: none"> • Conscious • Sufficient cerebral function for age-appropriate independent activities of daily life • School age child attending special education classroom • May have learning deficit
4	Severe disability	<ul style="list-style-type: none"> • Conscious • Dependent on others for daily support because of impaired brain function
5	Coma or vegetative state	<ul style="list-style-type: none"> • Any degree of coma without any of the criteria for brain death • Unawareness even if awake in appearance without interaction with the environment • Cerebral unresponsiveness • No evidence of cortical function and not aroused by verbal stimuli • Possibly some reflexive responses spontaneous eye opening and/or sleep-wake cycles
6	Brain death	<ul style="list-style-type: none"> • Apnea OR • Areflexia OR • Electroencephalographic (EEG) silence

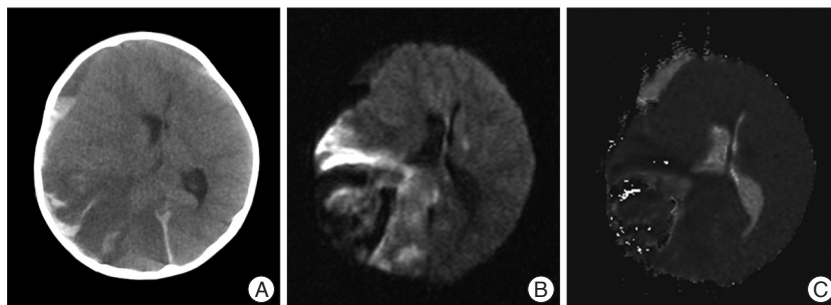


Fig. 1. A : Non enhanced brain CT revealed an acute right-sided middle cerebral artery territory infarct with mass effect manifested as right lateral ventricular compression, attenuation of the basal cisterns and right convexity sulci effacement. Because of midline shift due to severe brain parenchymal swelling, posterior horn of lateral ventricle was not seen. And hemorrhagic transformation was also noted at same side area. B and C : DWI MRI scan of his brain revealed that lesion was appropriate for acute cerebral infarction with hemorrhagic transformation with significant mid-line shift. CT : computed tomography, DWI : diffusion weighted image, MRI : magnetic resonance imaging.

tomies were performed at a mean of 12 hours (range 4-19 hours). In all cases we had performed supratentorial hemicraniectomies. There was no bilateral or occipital craniectomy case. The mean peak ICP was 28.6 mm Hg (range 25-30 mm Hg). And the ICP of all patients were dropped to normal range within one and half days after operation.

There were no surgical complications, such as cerebrospinal fluid leak or wound infection, even after cranioplasty. One of ischemic stroke patient had got a ventriculoperitoneal shunt operation because of post-stroke hydrocephalus.

The mean follow-up period was 47.6 months (36-68 months). GOS and PCPCS for 5 patients had been measured to evaluate postoperative neurological outcome. Based on the regular follow up GOS scores, 5 patients had shown satisfied recoveries : 4 had good recoveries (GOS score of 5), and 1 had moderate dis-

abilities (GOS score of 4). And there was no patient shown severe disability or death. The PCPCS scores also had revealed contend results : 4 patients received scores of 2, and only one patient scored of 3.

Patient presentation

A 17-month-old girl was transferred to our emergency department with decreased mentality. Neurological examination revealed a stuporous child without occasional spontaneous eye opening. Her right pupil was 6 mm in size and was not response to light. And her left pupil was 3 mm and was sluggishly re-

active to light. Hemiplegia, hyper-reflexia, and Babinski's sign were observed on the left side. Preoperative GCS score was 7. In general physical examination, she had an ejection systolic murmur. By pediatriccardiologist consultation, patient was diagnosis with ASD.

Initial brain CT scan was suggestive of acute infarction and hemorrhagic transformation atright temporal area. And emergency MRI sturdy was performed with MR angiography and diffusion-weighted image. There was no arterial filling defect on cerebral MR angiography. But there was appropriate for acute cerebral infarction with hemorrhagic transformation with significant mid-line shift. She was given high doses of mannitol and hypertonic saline. However, there was no neurologic improvement.

Decompressive surgery was performed 5 hours following her

loss of consciousness. After surgery, she was treated in pediatric intensive care unit with be kept intubated for 7 days.

A brain CT at the time of post-operative 7 days revealed sustained brain swelling, but midline shift did not noted anymore. The immediate post-operative ICP was 28 mm Hg. The ICP dropped to normal gradually within one day after surgery. At the time of postoperative 3-month, she returned for an elective cranioplasty. The bone flap was secured without any complications.

At the end of follow-up, 41 months after surgery, this patient maintained a PCPCS of 2, and GOS of 5, and she had showed mild left side hemiparesis, mild behavioral disorder and strabismus.

DISCUSSION

In stroke patient, most common cause of death is due to uncontrolled ICP associated with large hemispheric infarctions^{10,12}. When it is present, it is associated with a dramatic increase in mortality. In addition, early ICP elevation in patients with large hemispheric infarctions is highly concluded with high mortality¹⁶. It means that the one of most important goal of acute phase stroke treatment is control the ICP and prevent a secondary damage due to brain swelling.

In spite of many clinical and experimental trials on medical therapeutic method, most of them have not been shown to benefit pediatric stroke patient. There has been a widely accepted definite guideline for oxygen saturation, temperature, serum glucose level, blood pressure for adult stroke patient¹. However, for pediatric stroke patient, even in many of mostly basic and elementary medical guideline has not been established yet¹⁴.

To prevent and control ICP, thrombolytic therapy such as clot lysis has an accepted role in acute stroke treatment. In adult stroke patient group, there are antithrombotic management of adult ischemic stroke protocol and guideline published by the American Heart Association¹, such as intravenous tissue plasminogen activator, intra-arterial thrombolysis and oral administration of aspirin. But, for pediatric stroke patient, there is no guideline of this useful treatment method either¹⁴.

To the best of our knowledge, the first report about the benefits of decompressive hemicraniectomy in pediatric patient was described by Carter et al.³ at 1997. However, from this time, only a few report deals with decompressive craniectomy for pediatric patient were published.

In adult acute stroke patient group, the effect of decompressive craniectomy also has been established. Vahedi et al.²¹ reported that in a meta-analysis combining the data of 93 subjects from three small, randomized, controlled trials, mortality for conservative management in adult ischemic stroke patients with early brain edema was 71% as compared with 22% for decompressive surgical intervention.

Nowadays, some case reports and review has been published favorable outcome after decompressive surgery in childhood acute stroke^{2,17}. It is not often however in some article, decompressive craniotomy have been regarded as emerging procedure

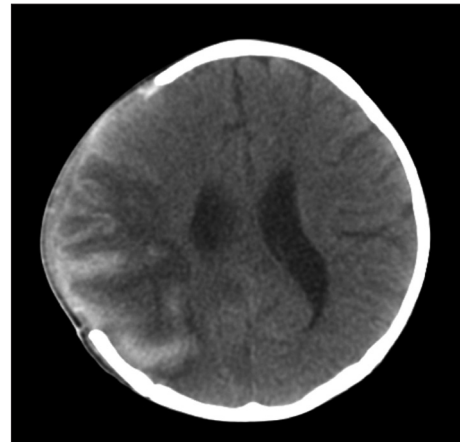


Fig. 2. Brain CT at the time of post-operative 7 days revealed sustained brain swelling with decompressive craniectomy, but midline shift did not noted anymore.

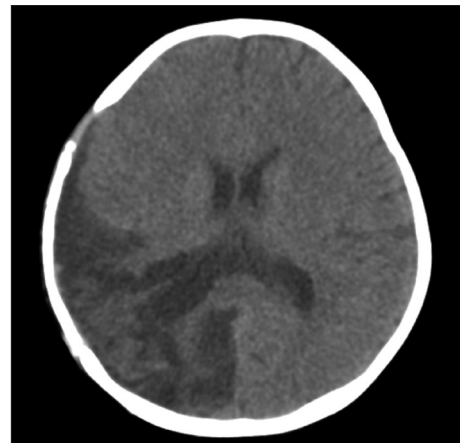


Fig. 3. Three years later, there was encephalomalacic change in right-sided middle cerebral artery territory. The bone flap was secured.

can save life, for pediatric stroke patient^{6,11}, even guideline for craniectomy was introduced¹¹. In point of fact, there is some debate indications and optimal timing of decompressive craniectomy^{12,19}. Widely accepted proper operation timing is immediately after signs of herniation and a midline shift which was defined as a more than equals 5-mm contralateral shift of the midline structures on the preoperative cranial CT scan on septum pellucidum level, compressed basal cisterns, or uncus herniation--had to be present on cranial CT had been noted. Recent studies in adult stroke group have shown that this procedure not only reduces mortality but also improves neurological functional outcome. Especially when operation is performed in the early hours^{8,12,18}. This procedure may be life-saving if done early in cases of impending herniation, is associated with good outcomes in pediatric stroke patients^{9,11}. Maybe if operation was performed earlier, it may minimize the vicious circle of brain swelling, increased ICP, ischemia, and infarction¹².

In our series, four toddlers and one pre-school girl with refractory high ICP due to non-traumatic, ischemic and hemorrhagic stroke were treated with decompressive craniectomy. All

had GCS scores <8 at operation. All of them were survived and have a relatively satisfied recovery. Four patient received PCPCS score of 2 (mild disability) and only one received that of 3 (moderate disability) after 3 years later post operation. These results showed that decompressive craniectomy can not only play a rescuer therapeutic role but also guaranty acceptable clinical outcome in the treatment regimen in non-traumatic, refractory high ICP in pediatric field.

In some articles, decompressive craniotomy has been tried to apply more alternative pediatric field. Meningitis and encephalitis could be not very rare diseases of pediatric period. And these diseases could make a malignant intracranial hypertension. Even in adult, effectiveness of decompressive craniectomy has been not established firmly. Aghakhani et al.²⁾ report that decompressive craniectomy was performed in pediatric patient with malignant intracranial hypertension due to infectious encephalitis. In adult patient group, there had been not infrequently reported that malignant intracranial hypertension due to encephalitis treated with decompressive craniectomy. Now, even in case of pediatric patient with infectious disease in central nerve system, decompressive craniectomy could be considered as life-saving-treatment options.

Gordon et al.⁷⁾ report that pediatric stroke can affect not only patient itself, but also his or her whole family. Over half of stroke survivors have suffer from decrease in quality of life and affects the entire family, and relates to both neurological deficits and psychosocial factors¹¹⁾. Hence, if all medical treatment is fail to drop the ICP in non-traumatic pediatric acute stroke patient, without hesitation, a decompressive craniectomy could be regarded as next step treatment option.

CONCLUSION

In this study, we describes the young pediatric patients have undergone decompressive hemicraniectomy for a non-traumatic acute hemispheric stroke. It also shows that decompressive hemicraniectomy can be lifesaving and can besafely performed in toddler and pre-school children. And young children can get a survival and relatively independence and family satisfaction. Decompressive hemicraniectomy should be considered as an alternative therapy for patients with life-threatening brains welling refractory to medical management.

References

1. Adams HP Jr, del Zoppo G, Alberts MJ, Bhatt DL, Brass L, Furlan A, et al. : Guidelines for the early management of adults with ischemic stroke : a guideline from the American Heart Association/American Stroke Association Stroke Council, Clinical Cardiology Council, Cardiovascular Radiology and Intervention Council, and the Atherosclerotic Peripheral Vascular Disease and Quality of Care Outcomes in Research Interdisciplinary Working Groups : The American Academy of Neurology affirms the value of this guideline as an educational tool for neurologists. *Circulation* 115 : e478-e534, 2007

2. Aghakhani N, Durand P, Chevret L, Parker F, Devictor D, Tardieu M, et al. : Decompressive craniectomy in children with nontraumatic refractory high intracranial pressure. Clinical article. *J Neurosurg Pediatr* 3 : 66-69, 2009
3. Carter BS, Ogilvy CS, Candia GJ, Rosas HD, Buonanno F : One-year outcome after decompressive surgery for massive nondominant hemispheric infarction. *Neurosurgery* 40 : 1168-1175; discussion 1175-1176, 1997
4. Chesnut RM : The management of severe traumatic brain injury. *Emerg Med Clin North Am* 15 : 581-604, 1997
5. Chi CS, Law KL, Wong TT, Su GY, Lin N : Continuous monitoring of intracranial pressure in Reye's syndrome--5 years experience. *Acta Paediatr Jpn* 32 : 426-434, 1990
6. Cho DY, Chen TC, Lee HC : Ultra-early decompressive craniectomy for malignant middle cerebral artery infarction. *Surg Neurol* 60 : 227-232; discussion 232-233, 2003
7. Gordon AL, Ganesan V, Towell A, Kirkham FJ : Functional outcome following stroke in children. *J Child Neurol* 17 : 429-434, 2002
8. Greenwood J Jr : Acute brain infarctions with high intracranial pressure : surgical indications. *Johns Hopkins Med J* 122 : 254-260, 1968
9. Gupta R, Connolly ES, Mayer S, Elkind MS : Hemicraniectomy for massive middle cerebral artery territory infarction : a systematic review. *Stroke* 35 : 539-543, 2004
10. Hacke W, Schwab S, Horn M, Spranger M, De Georgia M, von Kummer R : 'Malignant' middle cerebral artery territory infarction : clinical course and prognostic signs. *Arch Neurol* 53 : 309-315, 1996
11. Kirton A, deVeber G : Therapeutic approaches and advances in pediatric stroke. *NeuroRx* 3 : 133-142, 2006
12. Lee MC, Frank JJ, Kahana M, Tonsgard JH, Frim DM : Decompressive hemicraniectomy in a 6-year-old male after unilateral hemispheric stroke. Case report and review. *Pediatr Neurosurg* 38 : 181-185, 2003
13. Lynch JK, Hirtz DG, DeVeber G, Nelson KB : Report of the National Institute of Neurological Disorders and Stroke workshop on perinatal and childhood stroke. *Pediatrics* 109 : 116-123, 2002
14. Monagle P, Chan A, Massicotte P, Chalmers E, Michelson AD : Anti-thrombotic therapy in children : the Seventh ACCP Conference on Antithrombotic and Thrombolytic Therapy. *Chest* 126 : 645S-687S, 2004
15. Murphy S : Deaths : final data for 1998. *Natl Vital Stat Rep* 48 : 1-105, 2000
16. Ng LK, Nimmannitya J : Massive cerebral infarction with severe brain swelling : a clinicopathological study. *Stroke* 1 : 158-163, 1970
17. Ramaswamy V, Mehta V, Bauman M, Richer L, Massicotte P, Yager JY : Decompressive hemicraniectomy in children with severe ischemic stroke and life-threatening cerebral edema. *J Child Neurol* 23 : 889-894, 2008
18. Rieke K, Schwab S, Krieger D, von Kummer R, Aschoff A, Schuchardt V, et al. : Decompressive surgery in space-occupying hemispheric infarction : results of an open, prospective trial. *Crit Care Med* 23 : 1576-1587, 1995
19. Tan MA, Salonga AM, Jamora RD : Decompressive hemicraniectomy in a 2-year-old girl with a left middle cerebral artery infarct. *Childs Nerv Syst* 22 : 523-525, 2006
20. Taylor A, Butt W, Rosenfeld J, Shann F, Ditchfield M, Lewis E, et al. : A randomized trial of very early decompressive craniectomy in children with traumatic brain injury and sustained intracranial hypertension. *Childs Nerv Syst* 17 : 154-162, 2001
21. Vahedi K, Hofmeijer J, Juettler E, Vicaut E, George B, Algra A, et al. : Early decompressive surgery in malignant infarction of the middle cerebral artery : a pooled analysis of three randomised controlled trials. *Lancet Neurol* 6 : 215-222, 2007