

An Alternative Approach to Needle Placement in Cervicothoracic Epidural Injections

Department of Anesthesiology and Pain Medicine,
Gangneung Asan Hospital, University of Ulsan College of Medicine, Gangneung,
*Asan Medical Center, University of Ulsan College of Medicine, Seoul, Korea

Seung Yong Park, MD*, Jung Gil Leem, MD*, Sung Hwan Jung, MD,
Young Ki Kim, MD, and Won Uk Koh, MD*

The use of fluoroscopy guidance together with the loss of resistance technique during epidural injections has been advocated lately; moreover, epidural injections in the absence of fluoroscopic guidance have a high rate of inaccurate needle-tip placement during the injections. However, the approach to the lower cervical and upper thoracic epidural space may be challenging due to its obscure lateral fluoroscopic views from overlying normal tissue structures. In this case, we report an alternative oblique C-arm fluoroscopy guided view approach to supplement the standard anterior-posterior and lateral fluoroscopic views to facilitate successful needle placement and precise anatomical localization of the epidural space. (Korean J Pain 2012; 25: 183-187)

Key Words:

alternative, epidural, fluoroscopy, oblique.

The loss of resistance technique (LOR) is commonly used to identify the epidural space. It relies on the denseness of the ligamentum flavum and the sudden absence of resistance through a syringe filled with air or saline as the needle passes through the ligament [1-4]. However, it is occasionally difficult to use the LOR technique under certain clinical circumstances and previous reports have suggested the LOR technique in the absence of C-arm fluoroscopic guidance may be inadequate for identifying the epidural space, and a high incidence of inaccurate needle-tip placement has been reported [1,2]. Furthermore, a

false LOR may occur between the fascial planes, and a high incidence of discontinuity in the ligamentum flavum has been reported at the cervical and high thoracic levels [3,4], and the use of air for LOR is advantageous because it is simple and convenient; however, it may cause complications such as an air embolism, subcutaneous emphysema, pneumocephalus, or incomplete nerve block [4]. It is well known that fluoroscopic guidance is a useful tool for locating the epidural space and reducing potential risks [2]. However, the distal cervical and proximal thoracic spinal region are obstacles for fluoroscopy, as the lateral views

Received May 7, 2012. Revised June 7, 2012. Accepted June 8, 2012.

Correspondence to: Young Ki Kim, MD

Department of Anesthesiology and Pain Medicine, Gangneung Asan Hospital, University of Ulsan College of Medicine, Bangdong-ri, Sacheon-myeon, Gangneung 210-711, Korea

Tel: +82-33-610-3401, Fax: +82-33-641-8180, E-mail: ykkim@gnah.co.kr

© This is an open-access article distributed under the terms of the Creative Commons Attribution Non-Commercial License (<http://creativecommons.org/licenses/by-nc/3.0/>), which permits unrestricted non-commercial use, distribution, and reproduction in any medium, provided the original work is properly cited.

Copyright © The Korean Pain Society, 2012

are obscured by the overlying soft tissue structures especially when the patient is obese, has broad shoulders, or has a short neck [5]. A modified oblique fluoroscopic view can be used to compensate for the artifacts and radio-opacities produced by the normal adjacent anatomic structures, thereby allowing adequate visualization for localization [5,6].

In the following case, we report an alternative oblique C-arm fluoroscopy guided view approach to supplement the standard anterior-posterior (AP) and lateral fluoroscopic views for facilitating successful needle placement and precise anatomic localization of the epidural space.

CASE REPORT

A 34-year-old male patient was admitted for an occipital headache that had started 1 month prior to his visit. He had no history of head trauma, injury to the spine or dura puncture. The headache was postural in nature because the headache occurred when he stood up or sat, and it subsided when he lay down. The character of the headache was a dull, continuous pain in the occipital area with some radiating pain to the parietal and frontal areas. Visual analog scale (VAS) score was 8–9 points and dizziness was accompanied when standing or sitting. However, when he lay down, the VAS score decreased to 1–2 points. Physical and neurological examinations were performed on the day of admission and no abnormal findings were observed. Brain magnetic resonance imaging showed no abnormal findings and laboratory data on the patient were also within normal limits. Radionuclide cisternography was checked and it showed possible cerebrospinal fluid leakage at the cervicothoracic junction level (Fig. 1) and the patient was diagnosed with spontaneous intracranial hypotension. Conservative management was administered including hydration, bed rest, and NSAIDs. Yet, the symptom persisted and the patient was referred to the pain clinic for an epidural blood patch. The patient was 175.2 cm high and his body weight was 77 kg. His occupation was aquaculture, breeding abalone. The patient was not obese, but he had a relatively well-developed musculature. Upon entering the operation room, the patient was placed in the prone position on the C-arm table. Both arms of the patient were placed over his head. The lower cervical area and the upper thoracic area were prepared and the skin was anesthetized with a local anesthetic agent. A modified 18G Tuohy needle

was inserted at the C7–T1 intervertebral space and it was advanced at the anteroposterior (AP) view. For further advancement and visual identification of the epidural space, the C-arm was rotated to the lateral plane. The patient had very well developed shoulder muscles; therefore, the true lateral view image of the C7 and T1 vertebrae was difficult to obtain due to the superimposition of the shoulder muscles and bones (Fig. 1C). The optimal oblique view provided an increasingly more distinct image of the cervicothoracic junction and the needle was further advanced accompanied by the LOR technique and the imaging of the intermittent AP plane view (Fig. 2A). To obtain sufficient visualization, the C-arm unit was rotated in the AP/lateral plane until a perpendicular view of the target level lamina was achieved. The lamina was visualized as an enface image of a hollow tube (Fig. 2B, D). A hollow tube means the cross-sectional view of the target lamina as the per-

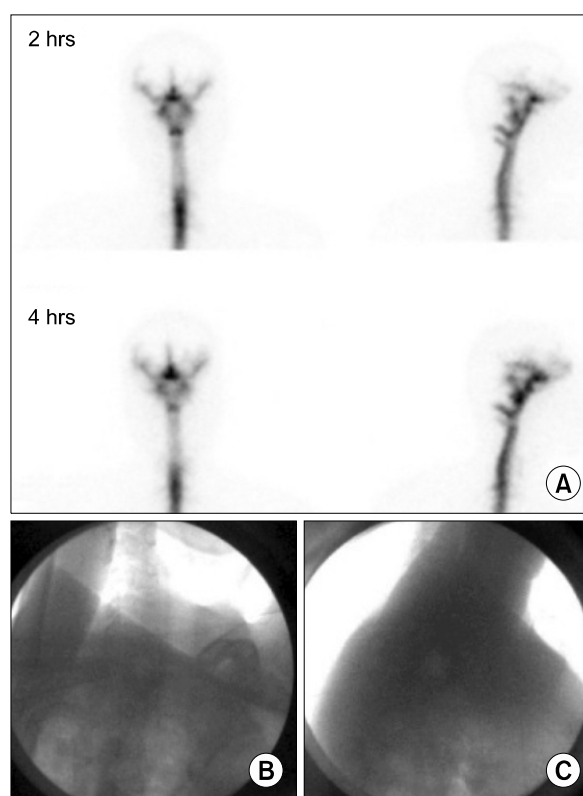


Fig. 1. Cisternography. Alternative and the standard lateral views under fluoroscopy. Cisternography revealed the CSF leakage at the C-C and C-T junction (A). Alternative (B) and the standard lateral views (C) were showed. Note that adequate lateral view was difficult to obtain due to normal shoulder structures.

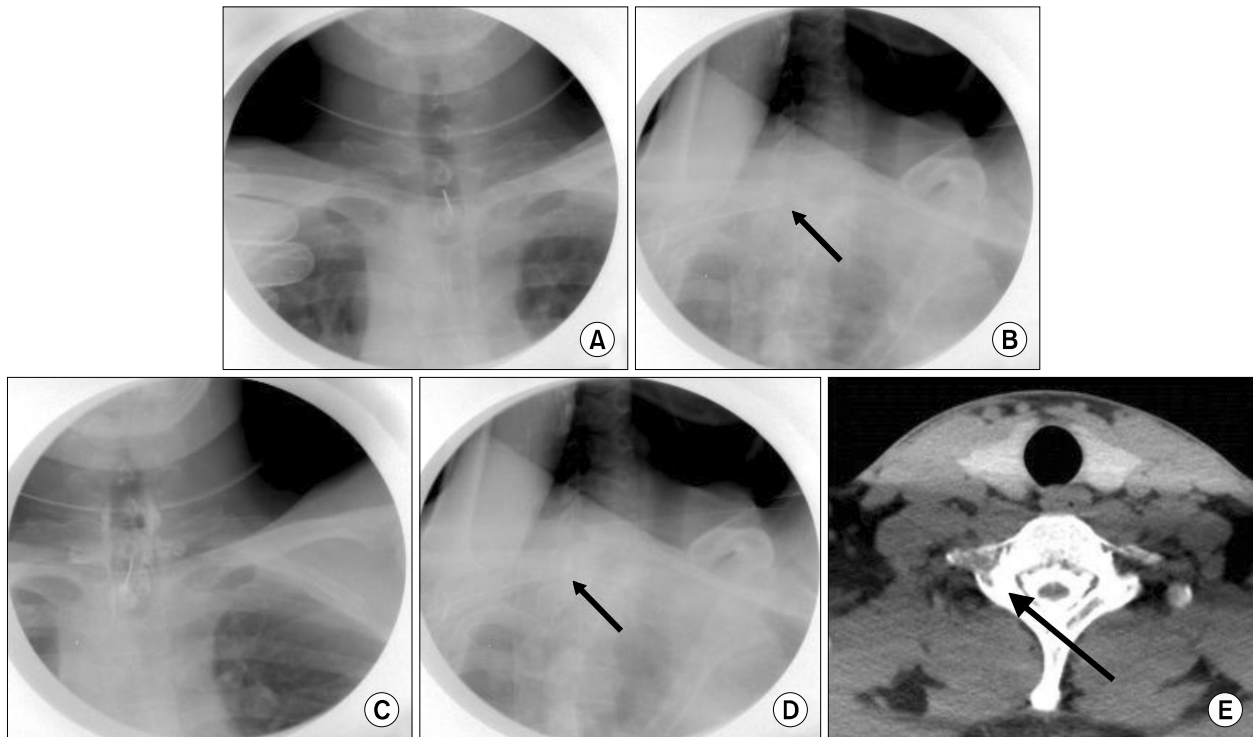


Fig. 2. AP and the alternative oblique views under fluoroscopy. AP view (A) and the alternative oblique view (B) under fluoroscopy; the contralateral laminae are seen in complete cross-section view. Epidural space was confirmed with contrast dye injection (C and D). Angle of the X-ray beam was parallel to the C7 lamina plane (E). Arrow indicated a hollow tube.

pendicular view of the target level when the target lamina is parallel with X-ray beam. The angle of the oblique position of the C-arm unit was calculated in reference to the cervical CT findings (Fig. 2E). As the needle entered the interlaminar opening, radiocontrast dye was administered. The AP view along with the oblique view was acquired to confirm the positioning of the needle tip in the epidural space (Fig. 2) and then 8ml of autologous blood was injected. On rounds the next day, the patient reported a pain score of 1/10 on the VAS. He was discharged 3 days after the procedure without any remaining symptoms.

DISCUSSION

Spontaneous intracranial hypotension is a syndrome consisting of low cerebrospinal fluid pressure, which occurs without preceding events such as a dura puncture, back trauma, or surgical operation procedures. When the symptoms persist or it is intolerable and refractory to conservative management, an autologous epidural blood patch

can be performed. An EBP is known to be highly effective in the management of SIH since it immediately alleviates the symptoms of this disorder [7]. The injection of autologous blood into the epidural space is approached by the loss of resistance technique (LOR) with or without C-arm fluoroscopy guidance [8]. The most common CSF leakage site of SIH is the cervicothoracic junction level. Thus, the epidural space of the cervicothoracic junction level is very difficult to confirm for EBP with C-arm fluoroscopy guidance.

Traditionally, the LOR technique is used with the AP fluoroscopy view to assure correct midline insertion of the epidural needle. This technique depends on the sudden absence of resistance of an air or saline filled syringe because the needle passes through the ligamentum flavum and enters the epidural space. However, it is occasionally difficult to use the LOR technique due to anatomical variations, and a false LOR may be present between the fascial planes, which increase the uncertainty of the needle depth [3,4]. The depth of the cervical epidural space is very small

(1–1.5 mm) [9], and the distance to the dura and the depth of the epidural space have been found to be variable [10]. Shallow advancement due to a false LOR may lead to inappropriate treatment, and deeper advancement of the needle may result in penetration of the dura, subarachnoid space, and spinal cord, which can lead to serious complications [11]. To avoid an inappropriate needle position and safely access the epidural space, a lateral fluoroscopic view is obtained and access to the epidural space is supplemented by a view of the needle movement related to the bony landmarks. However, the lateral view occasionally cannot provide a clear view in the lower cervical and upper thoracic spine regions because the shoulder of the patient may interfere with obtaining an adequate lateral view. It is especially challenging in patients who are obese with a short neck and broad shoulders. To overcome these circumstances, the patient and the staff members are usually instructed to pull down the patient's arms toward the toes to lower the shoulders. These techniques can improve the lateral view; however, in some cases, it may be insufficient. Additionally, it is not safe to do this while the needle is being inserted into the spinal canal. Numerous techniques have been studied to overcome this situation and to provide sufficient visual anatomy of the lower cervical and upper thoracic bony landmarks. Recently, Abbasi and Malhotra suggested a swimmer's view as an alternative method when the lateral view is inadequate [12], and Zhu et al. used an alternative oblique fluoroscopic view by placing a cervical spinal cord stimulator (SCS) at the target space [6]. Both techniques were reported to be effective in managing patients with inadequate lateral fluoroscopic views. Zhu et al. used the paramedian approach technique at the target interlaminar space in placing the cervical SCS. They used the optimal oblique view of fluoroscopy and the perpendicular view of the target lamina. In our case, we used the midline approach technique at the target lamina level. This means we approached the needle to the target interlaminar space perpendicularly in the AP view. We obtained an oblique view to overcome the inadequate lateral view in a patient with well-developed shoulder muscles. There are three key-points to be noted: first, the C-arm should be rotated until the complete cross-sectional view of the target level lamina is obtained; second, an intermittent true AP view should be obtained to secure the absolute midline entry of the needle tip; third, as this oblique view does not give the true depth as a true lateral

view does, the needle should be advanced a millimeter at a time. Moreover, we recommend the use of the LOR technique together with fluoroscopy guidance when the needle reaches the post margin of the target lamina during the penetration of the ligamentum flavum.

Here, we report an alternative oblique view for epidural blood patch at the cervicothoracic junction when obtaining a sufficient lateral view is impossible due to normal anatomical structures. This technique can also be applied to epidural steroid injections. The relative depth of the needle can be visualized in challenging cases with the obscure lateral view; therefore, accessing the epidural space more safely through direct visualization is possible during the procedure. However, as this technique is not a true lateral view, the use of it should be limited to patients where a true lateral view of the needle tip and the precise anatomy of the area of injection cannot be visualized and should not be considered as a standard technique. In conclusion, the described oblique view can be a good alternative method in a subset of patients in which attempts at viewing the lateral view fail.

REFERENCES

1. Bartynski WS, Grahovac SZ, Rothfus WE. Incorrect needle position during lumbar epidural steroid administration: inaccuracy of loss of air pressure resistance and requirement of fluoroscopy and epidurography during needle insertion. *AJNR Am J Neuroradiol* 2005; 26: 502–5.
2. Goel A, Pollan JJ. Contrast flow characteristics in the cervical epidural space: an analysis of cervical epidurograms. *Spine (Phila Pa 1976)* 2006; 31: 1576–9.
3. Lirk P, Kolbitsch C, Putz G, Colvin J, Colvin HP, Lorenz I, et al. Cervical and high thoracic ligamentum flavum frequently fails to fuse in the midline. *Anesthesiology* 2003; 99: 1387–90.
4. Kim TS, Shin SS, Kim JR, Kim DY. Air bubbles mimic disc herniation in MRI after cervical epidural block. *Korean J Pain* 2010; 23: 202–6.
5. Singh H, Meyer SA, Hecht AC, Jenkins AL 3rd. Novel fluoroscopic technique for localization at cervicothoracic levels. *J Spinal Disord Tech* 2009; 22: 615–8.
6. Zhu J, Falco FJ, Onyewu CO, Vesga R, Josephson Y, Husain A, et al. Alternative approach to needle placement in cervical spinal cord stimulator insertion. *Pain Physician* 2011; 14: 195–210.
7. Kim SY, Hong JH. Epidural blood patches in a patient with multi-level cerebrospinal fluid leakage that was induced by spontaneous intracranial hypotension. *Korean J Pain* 2010; 23: 46–50.

8. Cho KI, Moon HS, Jeon HJ, Park K, Kong DS. Spontaneous intracranial hypotension: efficacy of radiologic targeting vs blind blood patch. *Neurology* 2011; 76: 1139–44.
9. Huston CW. Cervical epidural steroid injections in the management of cervical radiculitis: interlaminar versus transforaminal. A review. *Curr Rev Musculoskelet Med* 2009; 2: 30–42.
10. Han KR, Kim C, Park SK, Kim JS. Distance to the adult cervical epidural space. *Reg Anesth Pain Med* 2003; 28: 95–7.
11. Collier CB. Accidental subdural injection during attempted lumbar epidural block may present as a failed or inadequate block: radiographic evidence. *Reg Anesth Pain Med* 2004; 29: 45–51.
12. Abbasi A, Malhotra G. The "swimmer's view" as alternative when lateral view is inadequate during interlaminar cervical epidural steroid injections. *Pain Med* 2010; 11: 709–12.