

## Evaluation of the course of the inferior alveolar canal in the mandibular ramus using cone beam computed tomography

Kyung-Hwan Kwon, Kyu-Bong Sim, Jae-Min Lee

*Department of Oral and Maxillofacial Surgery, School of Dentistry, Wonkwang University,  
Wonkwang Dental Research Institute, Iksan, Korea*

**Abstract** (J Korean Assoc Oral Maxillofac Surg 2012;38:231-9)

**Objectives:** This study sought to provide guidelines in order to decrease the incidence of nerve injury during mandibular ramus bone harvesting, and to improve understanding of the anatomical structure of the inferior alveolar canal (IAC) to include its distance from the exterior buccal cortex.

**Materials and Methods:** In January and February 2009, 20 patients who visited the Wonkwang University Department of Oral and Maxillofacial Surgery reporting various conditions underwent cone beam computed tomography and were included in this study. Patients with missing left or right mandibular first molars or incisors, or who had jaw fracture or bone pathologies, were excluded. The reference point (R point) was defined as the point where the occlusal plane reached the anterior ramus of the mandible. The position of the IAC in relation to the R point, the buccal bone width (BW), the alveolar crest distance (ACD), the distance from the alveolar crest to the occlusal plane (COD), and the distance from the IAC to the sagittal plane (CS) were determined using proprietary image analysis software which produced cross-sectional coronal and axial images.

**Results:** The distance medially from the R point to the IAC along the axial plane was  $6.19 \pm 1.21$  mm. The HD from the R point, posteriorly to IAC, in the lateral view was  $13.07 \pm 2.45$  mm, the VD from the R point was  $14.24 \pm 2.41$  mm, and the ND from the R point was  $10.12 \pm 1.76$  mm. The pathway of the IAC was positioned almost in a straight line along a sagittal plane within  $0.56 \pm 0.70$  mm. The distance from the buccal bone surface to the IAC increased anteriorly from the R point.

**Conclusion:** Marking osteotomy lines in the retromolar area in procedures involving bone harvesting should be discouraged due to the risk of damage to IAC structures. Our measurements indicated that the area from the R point in the ramus of the mandible to 10 mm anterior can be safely harvested for bone grafting purposes.

**Key words:** Cone-beam computed tomography, Mandibular nerve

*[paper submitted 2012. 5. 12 / revised 1st 2012. 5. 24, 2nd 2012. 7. 25 / accepted 2012. 8. 2]*

### I. Introduction

To place implants in an atrophic posterior mandible, vertical and horizontal bone reconstruction using autogenous, allogeneic, or alloplastic grafting is necessary. In particular, autografting has been integral to osteogenesis, osteoinduction, and osteoconduction<sup>1-3</sup>.

Normally, donor sites for auto bone harvesting are the iliac

crest and tibia extraorally and mental symphysis, maxillary tuberosity, ramus, and extosis intraorally. Bone from the mandible is less resolvable than that from extraoral donor sites. Furthermore, due to the proximity between the donor and recipient sites during implant procedures, the time for operation and anesthesia can be shortened; thus minimizing post-operative discomfort and complications. Among the intraoral donor sites, the anterior ramus, which has been used for vertically and horizontally recessed ridge augmentation prior to implant placement, has generally been chosen since its introduction by Misch and Dietsch<sup>4</sup>. Bone grafting from the anterior ramus also allows harvesting of block bone and particle bone at the same time, again shortening the operation time, reducing the amount of anesthesia, and minimizing post-operative discomfort and complications thanks to the proximity between the sites. Disadvantages include the risk

#### *Kyung-Hwan Kwon*

*Department of Oral and Maxillofacial Surgery, School of Dentistry, Wonkwang University, 895, Muwang-ro, Iksan 570-711, Korea  
TEL: +82-63-859-2921 FAX: +82-63-857-4002  
E-mail: kkhoms@daum.net*

© This is an open-access article distributed under the terms of the Creative Commons Attribution Non-Commercial License (<http://creativecommons.org/licenses/by-nc/3.0/>), which permits unrestricted non-commercial use, distribution, and reproduction in any medium, provided the original work is properly cited.

\*This study was conducted in 2010 using the Wonkwang University research fund.

of bleeding, fracture, and sensory disturbances.

In particular, sensory disturbances of the inferior alveolar nerve occur in association with bilateral sagittal splint ramus osteotomy (BSSRO), intraoral vertical ramus osteotomy, ramus osteotomy, ramus angle reduction, mandible fracture, and mandibular third molar extraction. This is because of the anatomical position of the nerve in inferior alveolar canal (IAC). The rates of sensory disturbance of the inferior alveolar nerve have varied from 3.9% of third molar extractions to 39% of BSSROs. Silva et al.<sup>5</sup> reported a sensory disturbance rate of 8.3% when harvesting mandibular bone.

The position of the inferior alveolar nerve is determined using dried mandibular bone from cadavers. Gowgiel<sup>6</sup> studied the inferior alveolar nerve canal and blood vessels of 29 adults with natural dentition. They reported that the nerve runs near the lingual cortical side from its entrance in the ramus to the mental foramen, and that it is positioned about 1 cm above the inferior border of the mandible.

According to Li et al.<sup>7</sup>, the nerve was positioned along the lingual inferior portion of the canal, and blood vessels were found above the canal.

Cone beam computed tomography (CBCT) is reportedly useful in determining the position of IAC. Kamburoglu et al.<sup>8</sup> noted that CBCT boasts of much higher accuracy than that of calipers. In investigating the position of the canal around the mandibular first molars, they concluded—after evaluating 50 patients with intact dentition—that IAC is positioned about 4.9 mm from the buccal cortical bone and 17.4 mm from the upper cortical bone of the mandible.

Previous studies have focused on the general lingual-buccal course of the inferior alveolar nerve canal using cadavers, panorama radiographs, and computed tomography (CT) related to the mandibular third molar and BSSRO.

**Table 1.** Descriptive statistics of the study variables

Variable	Number
Age (years, range)	29.5 (19-52)
Sample (n)	40
Right	20
Left	20
Gender	
Male	9
Female	11
Existence of third molar	
Yes	26
No	14

Kyung-Hwan Kwon et al: Evaluation of the course of the inferior alveolar canal in the mandibular ramus using cone beam computed tomography. J Korean Assoc Oral Maxillofac Surg 2012

Nonetheless, not much has been reported on the course of the inferior alveolar nerve canal during ramus bone harvesting. Clear understanding of the anatomical position of IAC is essential in reducing the risk of nerve damage, which can be avoided by establishing a reference point (R point) prior to bone harvesting.

In this study, the R point for the mandibular ramus was established using CBCT, and the position and course of IAC were analyzed three-dimensionally. The results are expected to aid in preventing damage to the inferior alveolar nerve during mandibular ramus bone harvesting.

## II. Materials and Methods

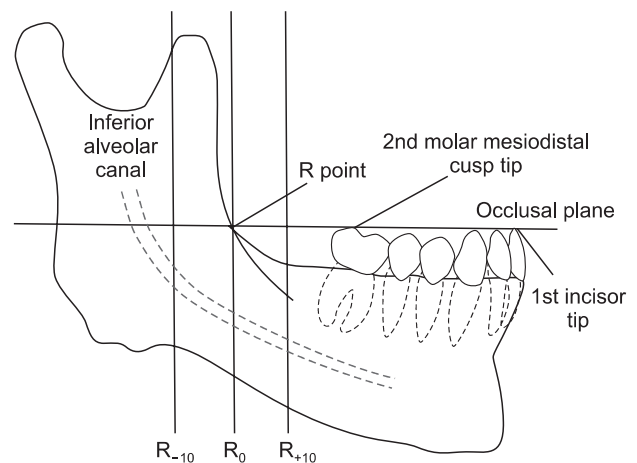
### 1. Study subjects

The study subjects were patients who underwent CBCT at the Wonkwang Dental Hospital in Korea from January to February 2009. A total of 20 patients (40 mandibular rami)—9 men and 11 women—all older than 19 years and with intact mandibular first molars and central incisors bilaterally were selected. Patients who had history of ramus surgery or disease and completely edentulous patients were excluded.(Table 1)

### 2. Methods

#### 1) Recomposition of information from CT

The CBCT images were saved in Digital Image Communication in Medicine (DICOM) file format from i-CAT



**Fig. 1.** Schematic of the mandible in lateral view. (R point: reference point)

Kyung-Hwan Kwon et al: Evaluation of the course of the inferior alveolar canal in the mandibular ramus using cone beam computed tomography. J Korean Assoc Oral Maxillofac Surg 2012

(Imaging Science International Inc., Hatfield, PA, USA). The occlusal plane connecting the disto-buccal cusp of the mandibular first molar and both incisal cusps of the central incisor were reconstructed using data produced through analysis by Simplant (Interactive Desktop Software [IDS]; Materialise Inc., Glen Burnie, MD, USA).

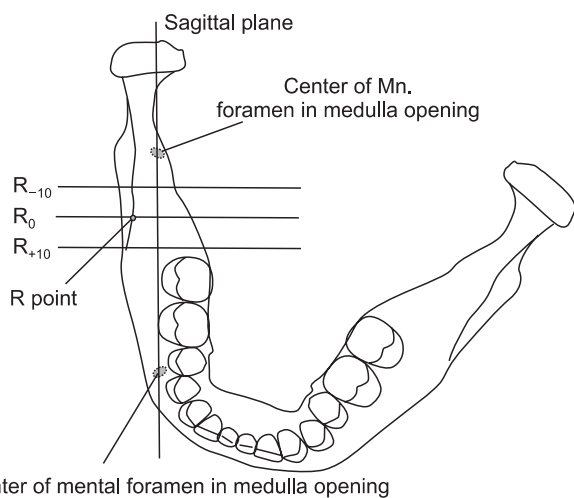
Using a panoramic curve, the plane of a line connecting the mandibular foramen and the mental foramen and the vertical to the occlusal plane was set as the sagittal plane. The openings of the mandibular foramen and mental foramen were then identified in the trabecular bone to measure the nearest distance from the outside of the cortical bone to IAC. (Fig. 1)

The contact point between the occlusal plane and the anterior border of the ramus was defined as the R point where the coronal plane was vertical to the occlusal and sagittal planes.

2) Anatomical analysis of the mandibular ramus

The coronal plane of the R point was labeled as the reference plane (R0 plane), and R points 10 mm posterior (R-10) to 10 mm anterior (R+10) were identified. Points on an RX plane were identified every 1 mm from the R0 plane, where X referred to the distance from R0.(Fig. 2)

Thus, 21 coronal planes from R-10 to R+10 were measured including the buccal bone width (BW), alveolar crest distance (ACD), crest to occlusal plane distance (COD), canal to sagittal plane distance (CS), and R point to sagittal plane

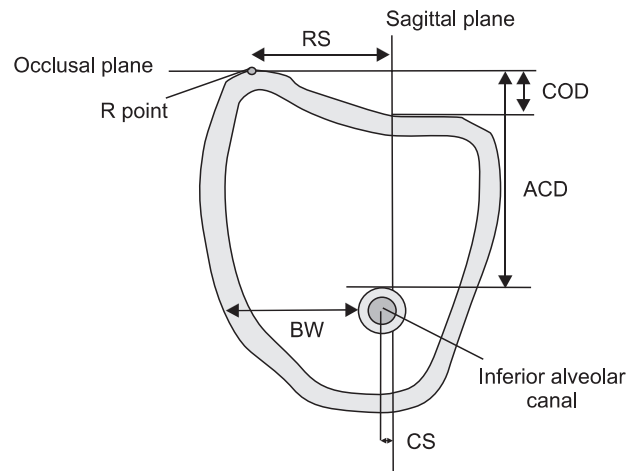


**Fig. 2.** Schematic of the mandible in superior view. (Mn.: mandible, R point: reference point)  
 Kyung-Hwan Kwon et al: Evaluation of the course of the inferior alveolar canal in the mandibular ramus using cone beam computed tomography. J Korean Assoc Oral Maxillofac Surg 2012

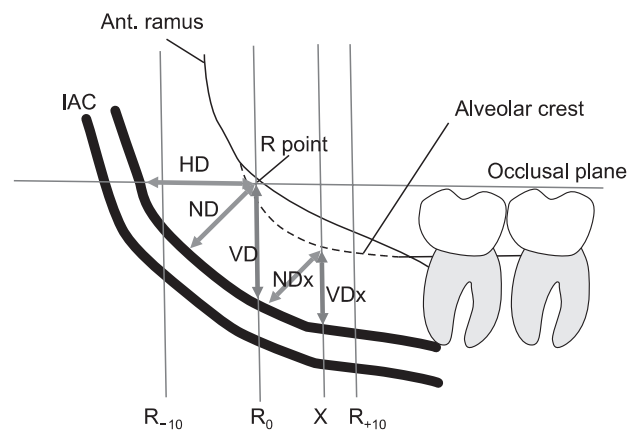
distance (RS).(Fig. 3)

(1) Distance between R point and center of the mandibular canal

We measured the distance from the R point to the center of the mandibular canal and analyzed the data by gender and side. Using the values of RS and CS on the R0 plane, the following formula was used (Fig. 3):



**Fig. 3.** Inferior alveolar canal, coronal cross-sectional. (R point: reference point, RS: R point to sagittal plane distance, COD: distance from the alveolar crest to the occlusal plane, ACD: alveolar crest distance, BW: buccal bone width, CS: distance from the inferior alveolar canal to the sagittal plane)  
 Kyung-Hwan Kwon et al: Evaluation of the course of the inferior alveolar canal in the mandibular ramus using cone beam computed tomography. J Korean Assoc Oral Maxillofac Surg 2012



**Fig. 4.** Schematic of lateral view of IAC position measurements. (Ant.: anterior, IAC: inferior alveolar canal, R point: reference point, HD: horizontal distance, ND: nearest distance, VD: vertical distance, NDx: nearest distance on x plane, VDx: vertical distance on x plane, X: distance from baseline)  
 Kyung-Hwan Kwon et al: Evaluation of the course of the inferior alveolar canal in the mandibular ramus using cone beam computed tomography. J Korean Assoc Oral Maxillofac Surg 2012

Distance from the R point to the center of IAC (mm)=RS-CS

(2) Distance from the R point to the center of the mandibular canal in lateral view

Horizontal distance (HD), vertical distance (VD), and nearest distance (ND) were measured between the occlusal plane and the anterior border of the ramus from the contact point (R0) and analyzed by gender and side.(Fig. 4)

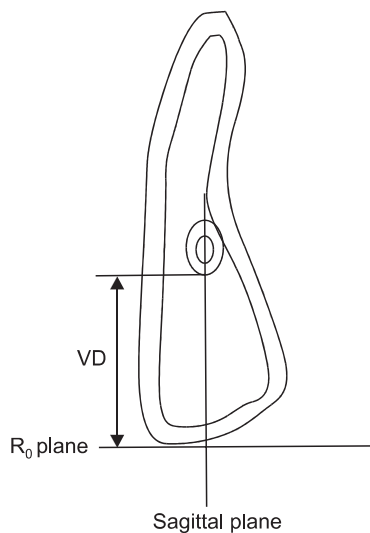
HD from the R point to IAC was measured from the R0 plane to IAC.(Fig. 5)

VD from the R point to IAC was measured using the ACD of the R0 plane. ND from the R point to IAC was determined by the square root of  $VD^2 + X^2$ .

$$\text{Nearest distance (mm)} = \sqrt{VD^2 + X^2} \text{ (X=distance from } R_0 \text{ plane)}$$

(3) Course of the inferior alveolar canal on a line connecting the mandibular foramen and the mental foramen

In the sagittal plane connecting the mandibular foramen



**Fig. 5.** IAC position measurements, cross-sectional occlusal plane. (IAC: inferior alveolar canal, VD: vertical distance, R: reference)

Kyung-Hwan Kwon et al: Evaluation of the course of the inferior alveolar canal in the mandibular ramus using cone beam computed tomography. J Korean Assoc Oral Maxillofac Surg 2012

and the mental foramen in the trabecular bone, to determine the course of IAC, the distance from the sagittal plane to the center of IAC was measured in the coronal plane from R-10 to R+10.(Fig. 3)

(4) Distance from the outside cortical bone to the inferior alveolar nerve canal

In the sagittal plane connecting the mandibular foramen and mental foramen in the trabecular bone, BW was measured with the coronal planes from R-10 to R+10.(Fig. 3)

(5) Distance of the inferior alveolar canal within 10 mm anterior to the R point

VD and ND were measured in the coronal plane from R-10 to R+10. The difference was measured on the upper crest of IAC.(Fig. 4)

### 3) Statistical analysis

For the analysis of the results, the independent t test was carried out to check for significant differences in length based on gender and both sides of the arch using SPSS. The results of the analyses were considered statistically significant when  $P < 0.05$ .

## III. Results

1. Distance from the R point to the center of the mandibular canal on the occlusal plane

The contact point between the occlusal plane and the ramus of the mandible at the center of the mandibular canal was  $6.19 \pm 1.21$  mm, showing no statistically significant variation by gender.(Table 2)

2. Analysis of the distance from the R point to the center of the mandibular canal in lateral view

At the contact point between the occlusal plane and the anterior border of the ramus, HD, VD, and ND were  $13.07 \pm$

**Table 2.** Distance from the R point medially to IAC (coronal view)

	Male	Female	Rt	Lt	Both
Distance (mm)	6.17±1.26	6.12±1.22	5.96±1.01	6.34±1.40	6.19±1.21

(R point: reference point, IAC: inferior alveolar canal, Rt: right, Lt: left)

Statistically significant difference,  $P < 0.05$ .

Values are presented as mean±standard deviation.

Kyung-Hwan Kwon et al: Evaluation of the course of the inferior alveolar canal in the mandibular ramus using cone beam computed tomography. J Korean Assoc Oral Maxillofac Surg 2012

**Table 3.** Distances between the canal and R point, lateral view (mm)

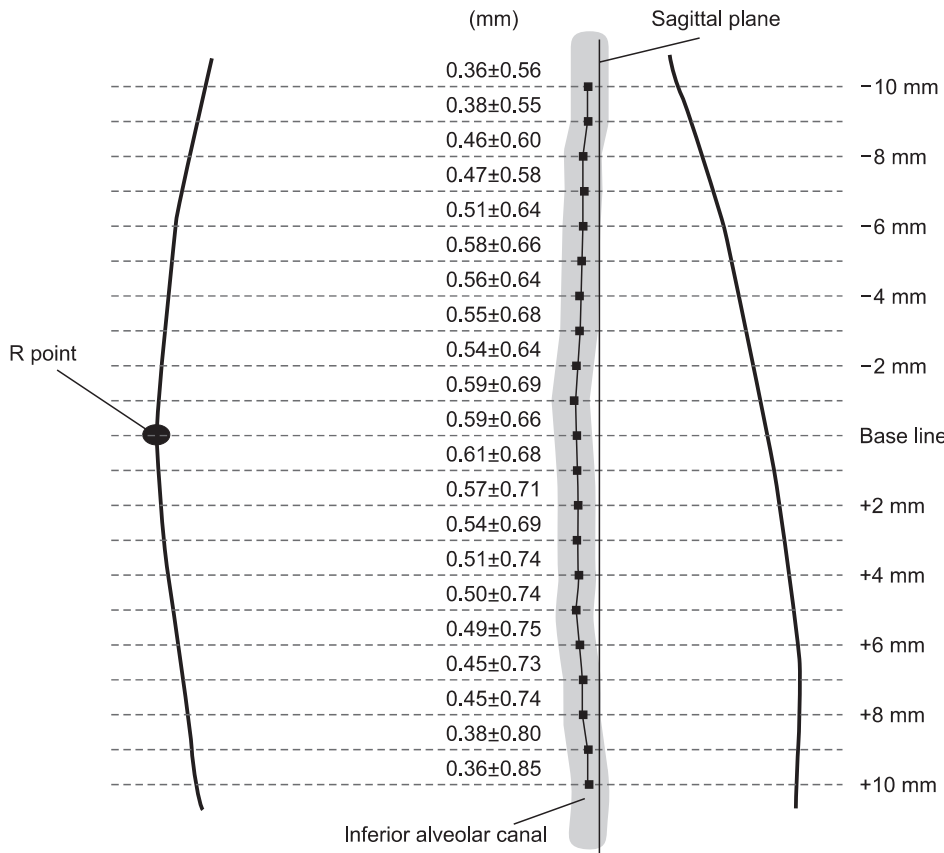
	Male	Female	Rt	Lt	Both
HD	14.00±1.59*	12.30±2.78*	13.13±2.31	13.01±2.64	13.07±2.45
ND	10.90±1.14*	9.48±1.94*	10.26±1.66	9.98±1.88	10.12±1.76
VD	15.80±1.45*	12.97±2.31*	14.36±2.36	14.13±2.51	14.24±2.41

(R point: reference point, Rt: right, Lt: left, HD: horizontal distance, ND: nearest distance, VD: vertical distance)

\*Statistically significant difference,  $P < 0.05$ .

Values are presented as mean±standard deviation.

Kyung-Hwan Kwon et al: Evaluation of the course of the inferior alveolar canal in the mandibular ramus using cone beam computed tomography. *J Korean Assoc Oral Maxillofac Surg* 2012



**Fig. 6.** Course of inferior alveolar canal along a sagittal plane (mean±standard deviation) (+10 mm=anterior, R point=buccal/lateral). (R point: reference point) Kyung-Hwan Kwon et al: Evaluation of the course of the inferior alveolar canal in the mandibular ramus using cone beam computed tomography. *J Korean Assoc Oral Maxillofac Surg* 2012

2.45 mm, 14.24±2.41 mm, and 10.12±1.76 mm, respectively, showing no statistically significant differences according to side. Statistically significant variance according to gender was noted, however.(Table 3)

3. Analysis of the course of the inferior alveolar canal on the line connecting the mandibular foramen and mental foramen

The mandibular canal was located along a sagittal plane connecting the mandibular foramen and the mental foramen in the trabecular bone and 0.36±0.56 mm buccally from a posterior R point of +10 mm, increasing to 0.61±0.68 mm at

the anterior R point of 1 mm and decreasing to 0.36±0.85 mm at the anterior R point of -10 mm. IAC ran a straight course of 0.61±0.68 mm along the plane connecting the mandibular canal and mental foramen in the trabecular bone.(Fig. 6)

4. Analysis of distance between the outside of the cortical bone and the inferior alveolar nerve canal

From the view of the sagittal plane connecting the mandibular foramen and the mental foramen, the distance between the outside of the buccal cortical bone and the inferior alveolar nerve canal was measured. The range was from the posterior 10 mm to the anterior 10 mm. In the

**Table 4.** Distance between the canal and the outer buccal cortex (mm)

	Male	Female	Rt	Lt	Both
BW <sub>-10</sub>	3.46±1.44	3.95±1.57	3.35±1.22	4.11±1.70	3.73±1.51
BW <sub>0</sub>	5.23±1.45	5.52±1.67	5.19±1.62	5.59±1.53	5.39±1.56
BW <sub>+10</sub>	6.53±1.62	6.03±1.43	6.09±1.41	6.43±1.64	6.26±1.52

(Rt: right, Lt: left)

Statistically significant difference, *P*<0.05; BW<sub>n</sub>=Buccal bone width at reference point (R), R-10 mm, R+10 mm.

Values are presented as mean±standard deviation.

Kyung-Hwan Kwon et al: Evaluation of the course of the inferior alveolar canal in the mandibular ramus using cone beam computed tomography. J Korean Assoc Oral Maxillofac Surg 2012

**Table 5.** Distances between the canal and the alveolar crest (mm)

	R <sub>0</sub>	R <sub>+1</sub>	R <sub>+2</sub>	R <sub>+3</sub>	R <sub>+4</sub>	R <sub>+5</sub>	R <sub>+6</sub>	R <sub>+7</sub>	R <sub>+8</sub>	R <sub>+9</sub>	R <sub>+10</sub>
ND	9.93±1.84	10.07±1.91	10.07±1.87	10.17±1.91	10.32±1.95	10.46±1.98	10.63±1.98	10.76±2.12	10.96±2.08	11.21±2.09	11.39±2.03
VD	13.96±2.45	13.76±2.58	13.56±2.65	13.55±2.67	13.38±2.63	13.49±2.45	13.46±2.50	13.50±2.65	13.81±2.62	13.81±2.80	13.90±2.74

(R: reference point, ND: nearest distance, VD: vertical distance)

Statistically significant difference, *P*<0.05.

Values are presented as mean±standard deviation.

Kyung-Hwan Kwon et al: Evaluation of the course of the inferior alveolar canal in the mandibular ramus using cone beam computed tomography. J Korean Assoc Oral Maxillofac Surg 2012

posterior, the distance was 3.7±1.51 mm; at the R point, it was 5.39±1.56 mm, increasing to 6.26±1.25 mm in the anterior. By gender, at the R point and at -10 mm, the female values of 3.95±1.57 mm and 5.52±1.67 mm exceeded those in males (3.46±1.44 mm and 5.23±1.45 mm). At the +10 mm R point, however, the female value of 6.03±1.43 mm was smaller than that of males (6.53±1.62 mm). These differences by gender were not statistically significant.(Table 4)

5. Analysis of the distances of the inferior alveolar nerve canal 10 mm anterior to the R point

In terms of ND and VD per 1 mm from the R0 plane to 10 mm anterior, ND was 9.93±1.84 mm at R0, increasing to 11.39±2.03 mm at R+10. In contrast, VD did not show any increase or decrease.(Table 5)

#### IV. Discussion

Although there are few reports on this issue, inferior alveolar nerve damage is one of the most important complications after mandibular ramus bone harvesting<sup>9</sup>. von Arx and Kurt<sup>10</sup> reported disturbances of the inferior alveolar nerve including bleeding, and Silva et al.<sup>5</sup> found complications due to sensory disturbances after mandibular ramus bone harvesting at a rate of 8.3%. These sensory disturbances occurred when the osteotomy was close to the inferior alveolar nerve canal. Yamamoto et al.<sup>11</sup> reported that the risk of nerve damage increased during BSSRO at distances less

than 0.8 mm between the internal side of the buccal cortical bone ramus and the inferior alveolar nerve canal. When harvesting bone from the mandibular ramus, the proximity to the inferior alveolar nerve canal was considered to increase the risk of nerve damage. Thus, understanding the anatomical course of the inferior alveolar nerve canal is important.

In the mandibular ramus, the position of the inferior alveolar nerve canal has been investigated according to the type of operation. Nerve damage was reported to occur at a rate of 3.9% in third molar extractions, suggesting the importance of the relationship between the third molar and the inferior alveolar nerve canal. In previous research on this relationship, the distance between the third molar and the inferior alveolar nerve canal has been measured by panorama radiographs and CT, and the risk of nerve damage has been evaluated as well. In ramus angle reduction, the risk and extent of operation were considered by measuring the distance between the angle and the nerve canal. In the ramus, findings of many previous operations have been used as preoperative evaluation indices to establish proper R points. Currently, however, there is a lack of research providing R points for bone harvesting from the mandibular ramus in terms of the anatomical position of the inferior alveolar nerve canal.

In this study, we defined the R point as the contact point between the occlusal plane and the anterior border of the mandible because this point can be found easily during bone harvesting. A plane crossing the mandibular foramen and mental foramen was set as the sagittal plane because this plane is very close to the actual course of the nerve canal that

the distance from the buccal cortical bone can be measured easily. With this reference, the anatomical course of the inferior alveolar nerve canal and the distance between the buccal cortical bone and the alveolar crest could be measured using CBCT to evaluate the course of the inferior alveolar nerve canal.

We used the panoramic curve function in the Simplant software to establish the sagittal plane connecting the mandibular foramen and the mental foramen in the trabecular bone. We then set the R point where the occlusal plane met the anterior border of the mandible and where the coronal plane—which was vertical to the occlusal and sagittal planes—met the R point.

We connected the openings in the trabecular bone because the openings in the cortical bone are in a region where the inferior alveolar nerve canal changed course. As such, there might be some error in describing the course in the trabecular bone.

The distance between the R point and the center of the inferior alveolar nerve canal was  $6.19 \pm 1.21$  mm, and that between the lower buccal cortical bone and the inferior alveolar nerve canal was  $5.39 \pm 1.56$  mm. These values suggest that the bone became thinner as it went from the upper side of the ramus to the lower buccal cortical bone. In other research, Reich<sup>12</sup> reported the distance between the buccal cortical bone and the inferior alveolar nerve canal in the retromolar area to be 2.835 mm. Levine et al.<sup>13</sup> measured 4.9 mm around the mandibular second molar area. According to Ha et al.<sup>14</sup>, the distance from the outside of the buccal cortical bone of the mandibular first molar bucco-mesial root to the inferior alveolar nerve canal was  $6.6 \pm 0.9$  mm. The more posterior the measurement was, the longer the distance; from these studies, there was no way of determining an absolutely safe position for the 4 mm-thick bone grafts suggested by Misch<sup>15</sup>. Thus, the thickness of the buccal side of the inferior alveolar nerve canal and the distance from the upper alveolar crest to the inferior alveolar nerve canal should also be considered.

Nkenke et al.<sup>16</sup> reported that the distance from the upper alveolar crest to the inferior alveolar nerve canal in the retromolar area was  $11.0 \pm 2.2$  mm. Levine et al.<sup>13</sup> measured 17.4 mm around the mandibular second molar area. In this study, we measured the distance between the R point and the inferior alveolar nerve canal in terms of ND, HD, and VD, and the values were  $13.07 \pm 2.45$  mm,  $14.24 \pm 2.41$  mm, and  $10.12 \pm 1.76$  mm, respectively. As for the measurements of ND and VD every 1 mm from the R0 plane to 10 mm anterior, we determined ND to be  $9.93 \pm 1.84$  mm at R0; this

distance increased to R+10, i.e.,  $11.39 \pm 2.03$  mm. VD was  $13.96 \pm 2.45$  mm at R0, increasing as well to R+10 where the value was  $13.90 \pm 2.74$  mm. Smith et al.<sup>17</sup> maintained that osteotomy with depth of 10 mm on the retromolar area should be safe from nerve damage. Our results confirmed that the R point was more than 10 mm away from IAC.

The course of the inferior alveolar nerve canal in the mandibular ramus is known to extend to the low anterior portion near the lingual cortical bone. Li et al.<sup>7</sup> researched on the buccal-lingual and upper-lower positions of IAC in the mandibular ramus and reported that the canal coursed to the lingual side and the lower border of ramus. In this research, using a reference line connecting the mandibular foramen with the mental foramen, the center of IAC was measured. In the posterior area with depth of 10 mm, the center was buccally  $0.36 \pm 0.56$  mm from the reference, increasing to  $0.61 \pm 0.68$  mm at 1 mm anterior. After that point, it decreased to  $0.36 \pm 0.85$  mm at 10 mm anterior. These results indicate that the course is straight in the range of  $0.61 \pm 0.68$  mm along the line connecting the mandibular foramen and the mental foramen to the center of the inferior alveolar nerve canal. With that, the distance from the outside of the buccal cortical bone to IAC was measured from the posterior 10 mm to the anterior 10 mm. In the posterior, the distance was  $3.7 \pm 1.51$  mm; at the R point, it was  $5.39 \pm 1.56$  mm, increasing to  $6.26 \pm 1.25$  mm in the anterior. These values indicate that the risk of nerve damage increases as bone is harvested from the points anterior to the R point to the posterior.

In this study, the position of the inferior alveolar nerve canal position at the R point and the distance from the outside of the buccal cortical bone to the inferior alveolar nerve canal showed no statistically significant difference by gender. In terms of the ND, HD, and VD of the canal in the sagittal plane, the values for men were significantly larger than those for women. There was 1 female patient who had a large volume of posterior bone loss, resulting in shortened distances that were thought to have affected these results.

The anatomical position of the inferior alveolar nerve canal appears to differ by age. According to Levine et al.<sup>13</sup>, in older patients, the distance from the outside of the buccal cortical bone to the inferior alveolar nerve canal was shorter. Lavelle<sup>18</sup> reported that alveolar bone around missing teeth had extensive bone loss, which was considered a normal physiological phenomenon. In our study, because 85% of the patients (17 out of 20) were below 30 years old, the data were not sufficient to evaluate the effects of age.

Recently, new methods and equipment have been developed

to avoid nerve damage during osteotomy. Piezoelectric equipment converts electric energy into mechanical energy and cuts bone using vibration. These instruments can cut hard tissue but not soft tissue. Piezoelectric equipment can be effective and useful for the prevention of intraoperative nerve damage, which is possible even after careful evaluation of IAC via panoramic radiographs or CT.

This study sought to contribute to decreased incidence rates of nerve injury during bone harvesting, to improve understanding of the anatomical structure of the inferior alveolar nerve, and to simplify measurement of the distance between the exterior buccal cortex and IAC.

For application to standard practice, it is important to note that this study targeted patients who had retained their mandibular first molars. Further investigation of the course of the inferior alveolar nerve in patients who are completely edentulous or who have lost all of their molars is required.

## V. Conclusion

This study sought to decrease the incidence of nerve injury during bone harvesting and to improve understanding of the anatomical structure of IAC and the distance between the exterior buccal cortex and IAC. Using CBCT for patients who had retained their mandibular first molars and central incisors on both sides, we measured the course of IAC, established a contact point between the occlusal plane and the anterior border of the mandible, and evaluated the distance between the buccal cortex, upper alveolar crest, and inferior alveolar nerve canal. The following results were obtained:

1. From the contact point between the occlusal plane and the anterior ramus of the mandible (R point), the center of the canal was located at  $6.19 \pm 1.21$  mm; this value did not show statistically significant difference by gender ( $P < 0.05$ ).
2. From the R point, HD, VD, and ND were  $13.07 \pm 2.45$  mm,  $14.24 \pm 2.41$  mm, and  $10.12 \pm 1.76$  mm, respectively. Statistically significant differences were noted according to gender ( $P < 0.05$ ).
3. From 10 mm posterior to 10 mm anterior to the R point, the course of the canal in the trabecular bone was nearly straight, with measurements in the range of  $0.61 \pm 0.68$  mm from the line connecting the mandibular foramen and the mental foramen to the center of IAC.
4. The distance between the outside of the buccal cortical

bone and the inferior alveolar nerve canal increased as the canal traveled from 10 mm posterior to the R point to 10 mm anterior.

5. The depth of the inferior alveolar nerve canal was consistent up to 10 mm anterior from the R point, but ND increased.

When the results above are compiled, it is apparently safe to harvest buccal cortical bone to a depth of 10 mm in the region 10 mm anterior to the R point between the occlusal plane and the anterior border of the ramus.

## References

1. Triplett RG, Schow SR. Autologous bone grafts and endosseous implants: complementary techniques. *J Oral Maxillofac Surg* 1996;54:486-94.
2. Jensen J, Sindet-Pedersen S, Oliver AJ. Varying treatment strategies for reconstruction of maxillary atrophy with implants: results in 98 patients. *J Oral Maxillofac Surg* 1994;52:210-6.
3. Habets LL, Bras J, Borgmeyer-Hoelen AM. Mandibular atrophy and metabolic bone loss. *Endocrinology, radiology and histomorphometry. Int J Oral Maxillofac Surg* 1988;17:208-11.
4. Misch CE, Dietsch F. Bone-grafting materials in implant dentistry. *Implant Dent* 1993;2:158-67.
5. Silva FM, Cortez AL, Moreira RW, Mazzonetto R. Complications of intraoral donor site for bone grafting prior to implant placement. *Implant Dent* 2006;15:420-6.
6. Gowgiel JM. The position and course of the mandibular canal. *J Oral Implantol* 1992;18:383-5.
7. Li N, Zhao B, Tan C. Intramandibular course and anatomic structure of the inferior alveolar nerve canal. *Zhonghua Kou Qiang Yi Xue Za Zhi* 2001;36:446-7.
8. Kamburoglu K, Kilic C, Ozen T, Yuksel SP. Measurements of mandibular canal region obtained by cone-beam computed tomography: a cadaveric study. *Oral Surg Oral Med Oral Pathol Oral Radiol Endod* 2009;107:e34-42.
9. Parikh SN. Bone graft substitutes: past, present, future. *J Postgrad Med* 2002;48:142-8.
10. von Arx T, Kurt B. Implant placement and simultaneous peri-implant bone grafting using a micro titanium mesh for graft stabilization. *Int J Periodontics Restorative Dent* 1998;18:117-27.
11. Yamamoto R, Nakamura A, Ohno K, Michi KI. Relationship of the mandibular canal to the lateral cortex of the mandibular ramus as a factor in the development of neurosensory disturbance after bilateral sagittal split osteotomy. *J Oral Maxillofac Surg* 2002;60:490-5.
12. Reich RH. Anatomical studies on the course of the mandibular canal. *Dtsch Zahnärztl Z* 1980;35:972-5.
13. Levine MH, Goddard AL, Dodson TB. Inferior alveolar nerve canal position: a clinical and radiographic study. *J Oral Maxillofac Surg* 2007;65:470-4.
14. Ha SY, Song NK, Koh KJ. A computerized tomographic study on the location of the mandibular canal and the cortical thickness of the mandible. *J Korean Acad Oral Maxillofac Radiol* 1997;27:217-30.
15. Misch CM. Comparison of intraoral donor sites for onlay grafting prior to implant placement. *Int J Oral Maxillofac Implants* 1997;12:767-76.
16. Nkenke E, Radespiel-Troger M, Wiltfang J, Schultze-Mosgau S, Winkler G, Neukam FW. Morbidity of harvesting of retromolar



- bone grafts: a prospective study. *Clin Oral Implants Res* 2002;13: 514-21.
17. Smith BR, Rajchel JL, Waite DE, Read L. Mandibular anatomy as it relates to rigid fixation of the sagittal ramus split osteotomy. *J Oral Maxillofac Surg* 1991;49:222-6.
18. Lavelle CL. Preliminary study of mandibular shape after tooth loss. *J Prosthet Dent* 1985;53:726-30.