

## Detection of Ocular *Toxoplasma gondii* Infection in Chronic Irregular Recurrent Uveitis by PCR

Sang-Eun Lee<sup>1</sup>, Sung-Hee Hong<sup>1</sup>, Seong-Ho Lee<sup>2</sup>, Young-Il Jeong<sup>1</sup>, Su Jin Lim<sup>3</sup>, Oh Woong Kwon<sup>3</sup>, Sun Hyun Kim<sup>3</sup>, Young Sung You<sup>3</sup>, Shin-Hyeong Cho<sup>1</sup> and Won-Ja Lee<sup>1,\*</sup>

<sup>1</sup>Division of Malaria and Parasitic Diseases, Korea National Institute of Health, Korea Centers for Disease Control and Prevention, Osong 363-951, Korea; <sup>2</sup>R & D Center, Lumieye Genetics Co. Ltd., Seoul 135-280, Korea; <sup>3</sup>The Retina Center, Nune Eye Hospital, Seoul 135-280, Korea

**Abstract:** *Toxoplasma gondii* is a zoonotic parasite resulting in human infections and one of the infectious pathogens leading to uveitis and retinochoroiditis. The present study was performed to assess *T. gondii* infection in 20 ocular patients with chronic irregular recurrent uveitis (20 aqueous humor and 20 peripheral blood samples) using PCR. All samples were analyzed by nested PCR targeting a specific B1 gene of *T. gondii*. The PCR-positive rate was 25% (5/20), including 5% (1) in blood samples, 25% (5) in aqueous humor samples, and 5% (1) in both sample types. A molecular screening test for *T. gondii* infection in ocular patients with common clinical findings of an unclear retinal margin and an inflammatory membrane over the retina, as seen by fundus examination, may be helpful for early diagnosis and treatment.

**Key words:** *Toxoplasma gondii*, toxoplasmosis, uveitis, nested PCR, B1 gene

*Toxoplasma gondii* is an important cause of zoonotic infection worldwide and may lead to uveitis, pneumonia, pericarditis, and neurologic disorders in immunocompetent hosts [1]. As ocular infection is one of the main manifestations of *T. gondii* infection, ocular toxoplasmosis is one of the most common types of infectious uveitis and a leading cause of posterior uveitis, also called retinochoroiditis [2-4], which may occur either immediately or long after initial infection. Recently, the importance of *T. gondii* infection in ocular patients has been recognized in view of etiologic and clinical findings. The global prevalence of ocular toxoplasmosis is variable, with 1.8% in Japan, 39.8% in Colombia, 22.2% in Thailand, and 8.4% in the U.S. [2,5-7]. Cases of ocular toxoplasmosis have been reported intermittently since the first case was described in Korea [8-11]. In 2003, *T. gondii* parasites were successfully isolated from a Korean ocular patient [12]. Recently, clinical features of ocular toxoplasmosis in Korean patients were described by Park et al. [13]. However, general information on ocular toxoplasmosis in Korea is insufficient because clinical reports of

ocular toxoplasmosis are rare and no epidemiologic survey has been conducted.

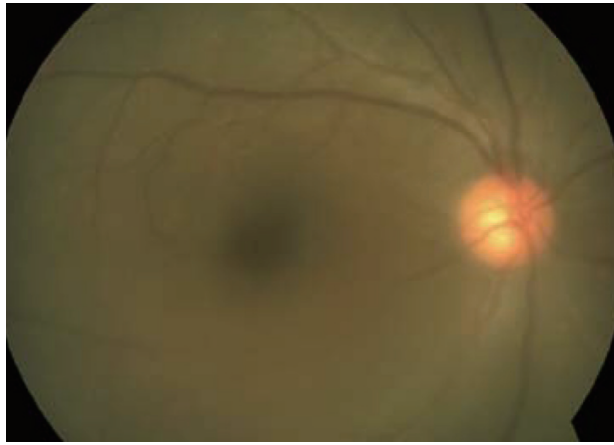
This study was carried out to assess *T. gondii* infection in 40 clinical samples (20 peripheral blood samples and 20 aqueous humor samples) from ocular patients with irregular recurrent uveitis by PCR. Most of the included patients did not show typical ocular toxoplasmic retinochoroidal lesions, but complained of blurry vision and floaters; common clinical findings included an unclear retinal margin and an inflammatory membrane over the retina, as shown by fundus photography (Figs. 1, 2). Samples were collected by an ophthalmologist from April to August 2009 and transferred from the Nune Eye Hospital to the Division of Malaria and Parasitic Disease at the Korea National Institute of Health for detection of *T. gondii*. Genomic DNA was extracted from aqueous humor and peripheral blood with the commercially available DNeasy Mini column kit (Qiagen, Hilden, Germany) according to the manufacturer's instructions. DNA concentrations were measured using the Quant-iT™ dsDNA HS Assay Kit (Invitrogen, Carlsbad, California, USA) and read on a Qubit™ Fluorometer (Invitrogen). The average DNA concentration was 8.05 ng/μL (3.3-16.9 ng/μL). The DNA samples were stored at -22°C until use. Two pairs of oligonucleotide primers, specific to the B1 gene of *T. gondii*, were used to perform nested PCR using purified blood cell DNA as a template. The published B1 gene se-

•Received 7 February 2012, revised 9 April 2012, accepted 14 April 2012.

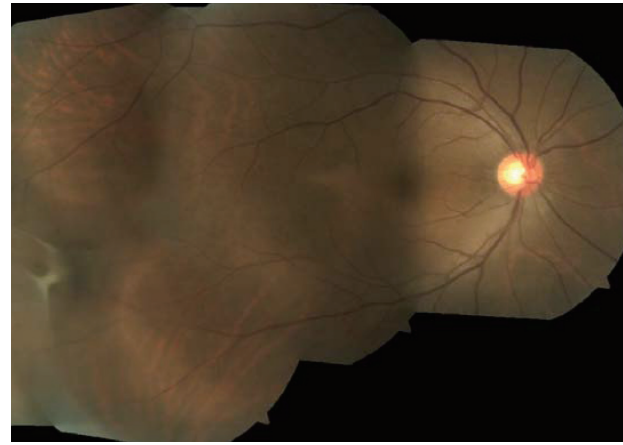\*Corresponding author (wonja@nih.go.kr)

© 2012, Korean Society for Parasitology

This is an Open Access article distributed under the terms of the Creative Commons Attribution Non-Commercial License (<http://creativecommons.org/licenses/by-nc/3.0>) which permits unrestricted non-commercial use, distribution, and reproduction in any medium, provided the original work is properly cited.



**Fig. 1.** The margin of the retinal vessels and disc was unclear due to the vitreous opacity in the patient.



**Fig. 2.** Inflammatory membrane over the retina as seen by fundus photography in the patient.

**Table 1.** PCR results for blood and aqueous humor samples from 20 patients with irregular recurrent uveitis

	Nested PCR		
	Blood	Aqueous humor	Both
No. of positive/Total	1/20	5/20	1/20
%	5	25	5

quence was amplified using the Maxime PCR premix Kit (Intron, Seongnam, Korea) according to the method described by Hurtado et al. [14]. The PCR program was modified as follows: 94°C for 3 min, 15 cycles of 94°C for 30 sec, 65°C for 45 sec, 72°C for 1 min, 35 cycles of 94°C for 20 sec, 53°C for 30 sec, 72°C for 30 sec and a final extension of 72°C for 5 min.

The overall positive rate for *T. gondii* detection was 5% (1/20) of blood samples and 25% (5/20) of aqueous humor samples by PCR and 5% (1/20) in both blood and aqueous humor samples (Table 1). This was a little lower than that of other countries [15-17]. It was reported that if aqueous humor samples are withdrawn too early after the onset of symptoms, false-negative by PCR results may be produced [17] or may be attributable to late sampling [18]. Therefore, PCR has previously been shown to be a useful tool for early diagnosis of *T. gondii* infection in patients who test negative by ELISA [19,20] and PCR detection of parasites within aqueous humor samples formally confirms the diagnosis of either primary or reactivated ocular toxoplasmosis [21].

*T. gondii* was found in the blood of acutely and chronically infected patients regardless of toxoplasmic retinochoroiditis [20]. Although the examination with light microscopy in peripheral blood samples was not carried out, the specific B1

gene of *T. gondii* in the blood was identified by nested PCR and confirmed by sequencing. The PCR-positive patients with chronic *T. gondii* infection in the present study had an irregular recurrence of symptoms, as previously stated, and the infection may thus be regarded as atypical chronic ocular toxoplasmosis. Additionally, the supplementary diagnostic tests for other infections, including syphilis (VDRL), HIV (ELISA), tuberculosis (chest X-ray), and autoimmune diseases, such as Vogt-Koyanagi-Harada disease and Behcet disease, were negative in all patients.

The population with ocular toxoplasmosis vary by geographic location [2,5-7,22]. Moreover, an atypical presentation of ocular toxoplasmosis has been reported [4]. Recently, there has been an increase in the reports of ocular toxoplasmosis, addressing the influence of patient age, frequency of inflammation, clinical features, diagnosis, and patterns of uveitis [7]. Therefore, it is necessary to further study the prevalence of ocular toxoplasmosis in a larger population of ocular patients with typical and atypical uveitis or retinochoroiditis in Korea.

In conclusion, we suggest that PCR analysis for diagnosis of ocular toxoplasmosis may be needed for the earlier diagnosis and treatment of ocular patients presenting with blurry vision and floaters caused by an unclear retinal margin and an inflammatory membrane over the retina.

## ACKNOWLEDGMENT

This work was supported by a grant (4847-302-210-13, 2009) from the Korea National Institute of Health, Republic of Korea.

## REFERENCES

1. Bossi P, Bricaire F. Severe acute disseminated toxoplasmosis. *Lancet* 2004; 364: 579.
2. Keino H, Nakashima C, Watanabe T, Taki W, Hayakawa R, Sugitani A, Okada AA. Frequency and clinical features of intraocular inflammation in Tokyo. *Clin Experiment Ophthalmol* 2009; 37: 595-601.
3. Rhthova A, de Boer JH, Ten Dam-van Loon NH, Postma G, de Visser L, Zuurveen SJ, Schuller M, Weersink AJ, van Loon AM, de Groot-Mijnes JD. Usefulness of aqueous humor analysis for the diagnosis of posterior uveitis. *Ophthalmology* 2008; 115: 306-311.
4. Smith JR, Cunningham ET Jr. Atypical presentations of ocular toxoplasmosis. *Curr Opin Ophthalmol* 2002; 13: 387-392.
5. De-la-Torre A, Lopez-Castillo CA, Rueda JC, Mantilla RD, Gomez-Marin JE, Anaya JM. Clinical patterns of uveitis in two ophthalmology centres in Bogota, Colombia. *Clin Exp Ophthalmol* 2009; 37: 458-466.
6. Sirirungsi W, Pathanapitoon K, Kongyai N, Weersink A, de Gero-Mijnes JD, Leechanachai P, Ausayakhun S, Rothova A. Infectious uveitis in Thailand: Serologic analyses and clinical features. *Ocul Immunol Inflamm* 2009; 17: 17-22.
7. London NJ, Hovakimyan A, Cubillan LD, Siverio CD Jr, Cunningham ET Jr. Prevalence, clinical characteristics, and causes of vision loss in patients with ocular toxoplasmosis. *Eur J Ophthalmol* 2011; 21: 811-819.
8. Kong SM, Lee TS, Kim CW. 3 Cases of ocular toxoplasmosis. *J Korean Ophthalmol Soc* 1975; 16: 141-145.
9. Yoo HY, Cho BC. 2 Cases of ocular toxoplasmosis. *J Korean Ophthalmol Soc* 1979; 20: 231-237.
10. Shyn KH, Kim KY, Park SC. A clinical experience of ocular toxoplasmosis, treated with acetyl spiramycin. *J Korean Ophthalmol Soc* 1979; 20: 427-431.
11. Kim MH, Choi YK, Park YK, Nam HW. A toxoplasmic uveitis case of a 60-year-old male in Korea. *Korean J Parasitol* 2000; 38: 29-31.
12. Chai JY, Lin A, Shin EH, Oh MD, Han ET, Nam HW, Lee SH. Laboratory passage and characterization of an isolate of *Toxoplasma gondii* from an ocular patient in Korea. *Korean J Parasitol* 2003; 41: 147-154.
13. Park YH, Han JH, Nam HW. Clinical features of ocular toxoplasmosis in Korean patients. *Korean J Parasitol* 2011; 49: 167-171.
14. Hurtado A, Aduriz G, Moreno B, Barandika J, García-Pérez AL. Single tube nested PCR for detection of *Toxoplasma gondii* in fetal tissues from naturally aborted ewes. *Vet Parasitol* 2001; 102: 17-27.
15. Fardeau C, Romand S, Rao NA, Cassoux N, Bettembourg O, Thulliez P, Lehoang P. Diagnosis of toxoplasmic retinochoroiditis with atypical clinical features. *Am J Ophthalmol* 2002; 134: 196-203.
16. Figueroa MS, Bou G, Marti-Belda P, Lopez-Velez R, Guerrero A. Diagnostic value of polymerase chain reaction in blood and aqueous humor in immunocompetent patients with ocular toxoplasmosis. *Retina* 2000; 20: 614-619.
17. Villard O, Filisetti D, Roch-Deries F, Garweg J, Flament J, Candolfi E. Comparison of enzyme-linked immunosorbent assay, Immunoblotting, and PCR for diagnosis of Toxoplasmic chorioretinitis. *J Clin Microbiol* 2003; 41: 3537-3541.
18. Payeur G, Bijon JC, Pagano N, Kien T, Candolfi E, Penner ME. Diagnosis of ocular toxoplasmosis by the ELISA method applied to the determination of immunoglobulins of the aqueous humor. *J Fr Ophtalmol* 1988; 11: 75-79.
19. Bidgoli S, Koch P, Caspers L. Toxoplasmic chorioretinitis: positive PCR on vitreous with negative serology for *Toxoplasma gondii*. *J Fr Ophtalmol* 2011; 34: 384.e1-e5.
20. Silveira C, Vallochi AL, Rodrigues da Silva UR, Muccioli C, Holland GN, Nussenblatt RB, Belfort R, Rizzo LV. *Toxoplasma gondii* in the peripheral blood of patients with acute and chronic toxoplasmosis. *Br J Ophthalmol* 2011; 95: 396-400.
21. Bastien P. Molecular diagnosis of toxoplasmosis. *Trans R Soc Trop Med Hyg* 2002; 96: S205-S215.
22. Accorinti M, Bruscolini A, Pirraglia MP, Liverani M, Caggiano C. Toxoplasmic retinochoroiditis in an Italian referral center. *Eur J Ophthalmol* 2009; 19: 824-830.