

Case Report

Calcific Tendinitis of the Hand and Foot: A Report of Four Cases

Hyung Ook Lee¹, Young Hwan Lee¹, Sung Hee Mun¹, Ung Rae Kang¹, Chae Kyung Lee²,
Kyung Jin Suh³

¹Department of Radiology, School of Medicine, Catholic University of Daegu

²Department of Radiology, Pohang St. Mary's Hospital

³Department of Radiology, School of Medicine, Dongguk University Gyeongju Hospital

Calcific tendinitis of hand and foot is rare and frequently misdiagnosed because of its rare incidence and its similar clinical presentation to other conditions such as infection. Awareness of the typical location as well as familiarity with the imaging findings is essential for making a correct diagnosis of this rare condition. We report four cases of calcific tendinitis of hand and foot, occurring in the flexor hallucis brevis, abductor digiti minimi, and abductor pollicis brevis.

Index words : Tendon · Tendon, Magnetic resonance · Tendinitis

INTRODUCTION

Calcific tendinitis most commonly occurs in the shoulder and less common locations include the hip, elbow, wrist, and knee (1–3). Its occurrence in the hand and foot has been sporadically reported in the literature (4–9). Clinically, calcific tendinitis of hand and foot is presented by severe pain, swelling, and erythema, and is frequently misdiagnosed because of its rare incidence and its similar clinical presentation to other conditions such as infection, gout, or fracture (4–6).

The ultrasonography (US) and MR findings of calcific tendinitis of the hand and foot have been rarely reported in the literature (7, 8). Awareness of the typical location as well as familiarity with the imaging findings is essential for making a correct diagnosis of

this condition. We describe the radiography, US, CT, and MR imaging findings of four cases of calcific tendinitis occurring in the hand and foot.

CASE REPORT

Patient 1

A 32-year-old woman presented with a 2-day history of pain on the plantar aspect of the right forefoot in the area of first metatarsal head. She had no history of trauma or previous foot pain. Physical examination showed tenderness with swelling at the painful area. Laboratory findings were all normal. Radiographs and CT showed a 0.6 cm-sized amorphous calcification adjacent to the medial sesamoid bone (Fig. 1a, b). US demonstrated its location within the medial head of flexor hallucis brevis tendon (Fig. 1c). MR imaging showed an ovoid low signal intensity nodule in the tendon (Fig. 1d–f), corresponding seen on the CT and US. Diffuse inflammatory soft tissue edema was seen around the calcification and bone marrow edema was also seen in the medial sesamoid bone. Conservative therapy was instituted with anti-inflammatory medications and splinting, and the patient's symptom

• Received; July 13, 2012 • Revised; July 29, 2012

• Accepted; July 31, 2012

Corresponding author : Young Hwan Lee, M.D., Department of Radiology, School of Medicine, Catholic University of Daegu, #3056-6, Daemyung-4 dong, Nam-gu, Daegu 705-718, Korea.

Tel. 82-53-650-4329, Fax. 82-53-650-4339

E-mail : yhlee@cu.ac.kr

resolved after two weeks.

Patient 2

A 42-year-old woman presented with a one-month history of left forefoot pain without history of significant trauma. Physical examination revealed tenderness and redness on the plantar surface of the foot near the head of the first metatarsal. Laboratory findings were all normal. Radiographs demonstrated

irregular, stippled and ovoid calcific deposits around the lateral sesamoid bone (Fig. 2a, b). MR imaging showed multiple low signal intensity foci, corresponding to calcifications, in the lateral head of flexor hallucis brevis muscle and tendon (Fig. 2c, d). Soft tissue edema was seen around the calcifications. A presumptive diagnosis of calcific tendinitis was made and the patient received conservative treatment with anti-inflammatory medications and splinting. After

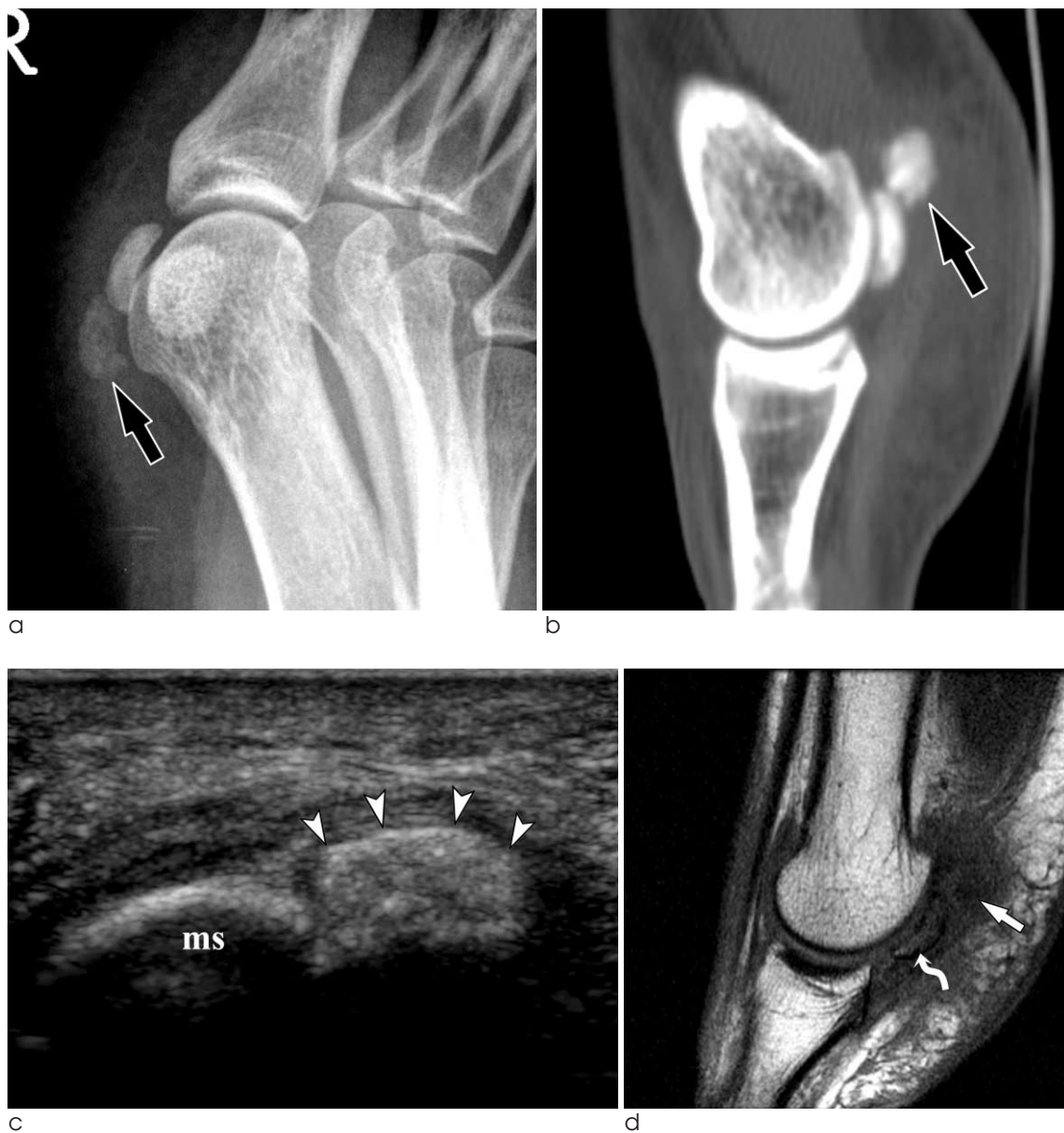

Fig. 1. A 32-year-old woman with calcific tendinitis of the medial head of flexor hallucis brevis. Oblique radiograph (a) and CT with sagittal reconstruction (b) of the right first metatarsophalangeal joint show an amorphous calcification (arrow) adjacent to the medial sesamoid bone. c. US reveals an ovoid hyperechoic calcification (arrowheads) within the medial head of flexor hallucis brevis tendon. d. On sagittal T1-weighted MR image, calcification is seen as a faint low signal intensity nodule. Soft tissue edema is seen around the calcification and bone marrow edema is also seen in the medial sesamoid bone (curved arrow).

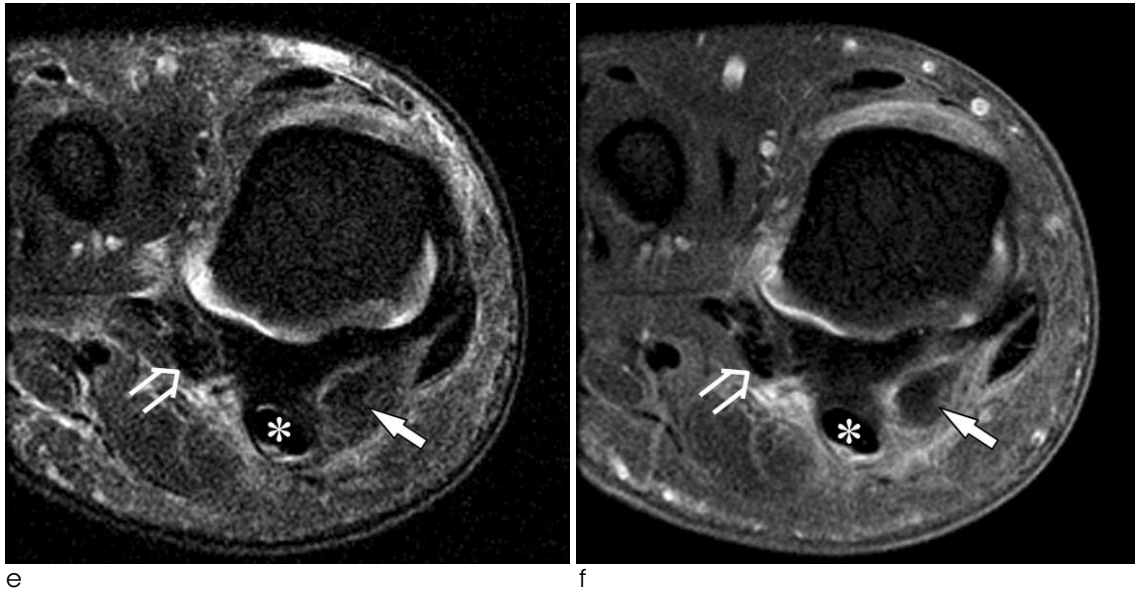


Fig. 1. Coronal fat-suppressed T2-weighted (e) and contrast-enhanced fat-suppressed T1-weighted (f) images show diffuse soft tissue edema and enhancement around the calcification (arrow) in the medial head of flexor hallucis brevis tendon. The flexor hallucis longus (asterisk) and lateral head of flexor hallucis brevis (open arrow) tendons are indicated. ms = medial sesamoid.

two weeks, all of her symptoms completely resolved.

Patient 3

A 61-year-old man presented with a 7-day history of right wrist pain. He had no history of trauma or previous similar episodes. Physical examination showed slight swelling and tenderness on the ulnar side of the wrist. Laboratory findings are unremarkable. Radiograph and CT revealed a small calcification medial to the pisiform (Fig. 3a, b). US confirmed the location of the calcification in the origin of abductor digiti minimi muscle (Fig. 3c). Color Doppler US showed increased vascularity around the calcification (Fig. 3d). MR imaging showed faint low signal intensity in the abductor digiti minimi muscle (Fig. 3e, f), consistent with the calcification seen on the CT and US. Mild soft tissue edema was seen around the calcification, without marrow edema in the pisiform. With the presumptive diagnosis of calcific tendinitis, he received conservative treatment with anti-inflammatory medications. At review three weeks later, he was asymptomatic.

Patient 4

A 34-year-old man was presented to our hospital with acute pain and swelling around the left first metacarpophalangeal joint. His pain started two weeks prior to presentation without a recent history of

trauma. On physical examination, the patient had focal tenderness and mild swelling along the radial aspect of the thumb around the metacarpophalangeal joint. Laboratory findings are unremarkable. Radiographs revealed an ovoid calcification lateral to the metacarpal head (Fig. 4a). MR imaging showed a calcification with comet-tail appearance within the abductor pollicis brevis tendon (Fig. 4b, c). Mild edema was seen around the calcification. With the diagnosis of calcific tendinitis, the patient was conservatively treated with anti-inflammatory medication. After two weeks, all of her symptoms completely resolved.

DISCUSSION

Calcific tendinitis is a common disorder caused by calcium hydroxyapatite deposition in a tendon. This condition has been described in nearly every tendon in the body, but occurs predominantly in the shoulder (1, 2). Less common locations include the hip, elbow, wrist, and knee (3). Calcific tendinitis of the hand and foot is an uncommon condition and is often misdiagnosed. In the hand, calcific tendinitis most commonly involves the flexor carpi ulnaris tendon near the pisiform bone and has been reported involving both the flexor and extensor tendons of the hand (4–8).

Reports of cases in the foot are scarce, including peroneus longus tendon, flexor hallucis tendon, and lumbrical and interosseous tendons (9).

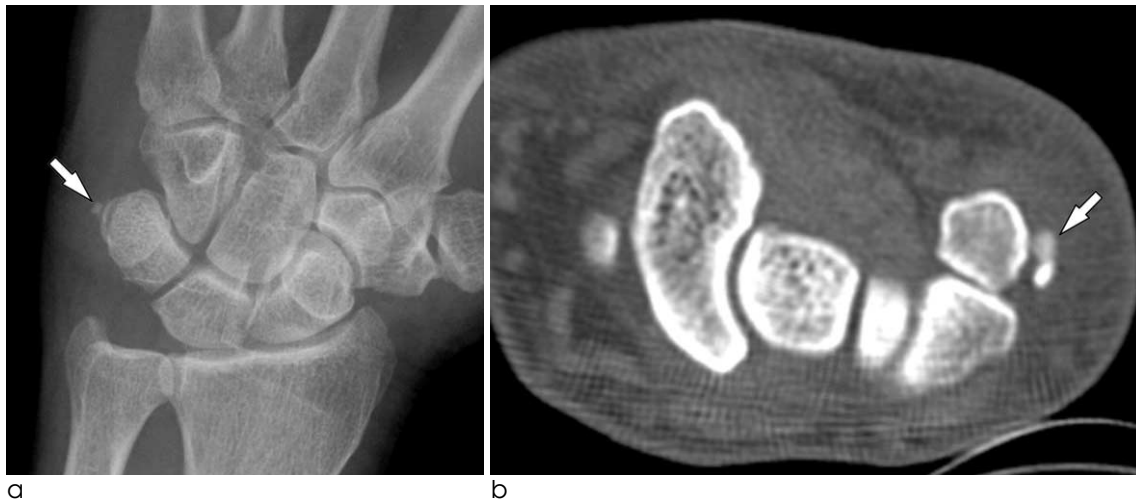
Clinically calcific tendinitis of the hand and foot is characterized by pain, tenderness, swelling, erythema, and restriction of motion secondary to pain. These acute presentations are usually self-limited within 3–4 weeks with conservative treatment. Calcific tendinitis of the hand and foot is frequently misdiagnosed because of its rare occurrence and its clinical resemblance to other entities (4–7). Clinical presenta-

tion may simulate acute infection, avulsion fracture, gout, or pseudogout. Many of the cases reported in the literature were often inappropriately treated with antibiotics or even surgery (6).

Radiographically, amorphous calcifications are found adjacent the cortex of the bone, and radiographs will often allow the correct diagnosis to be made. Additional oblique radiographs may be necessary because small calcifications can be missed easily. Rarely, calcifications may not be visible on radiographs. The initial radiographic diagnosis may be

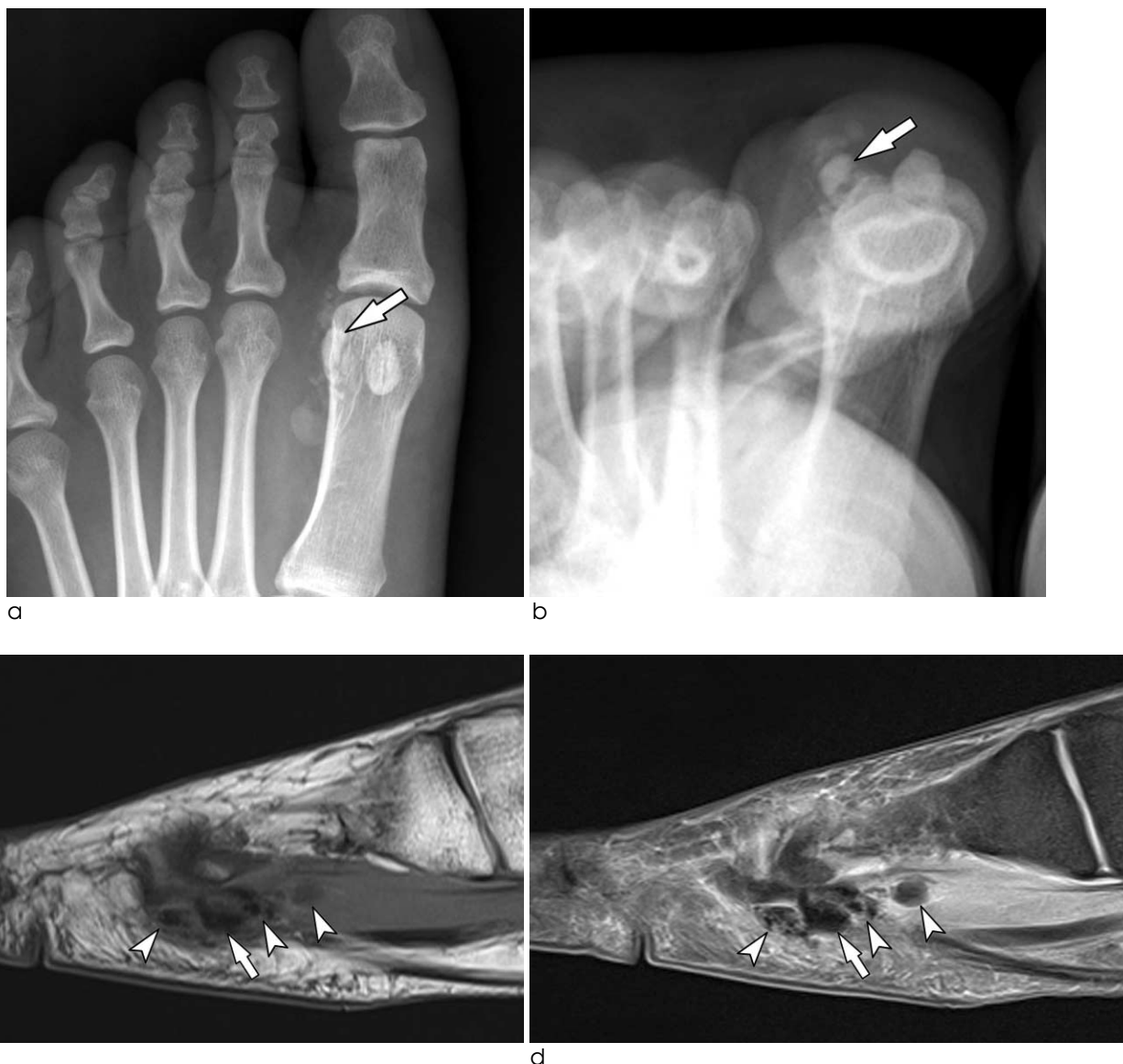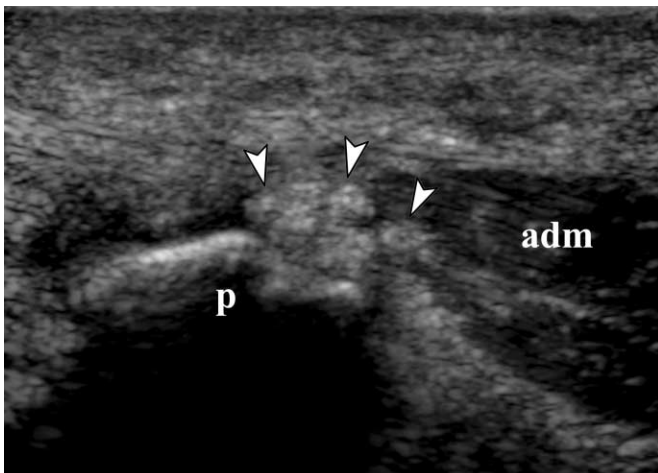


Fig. 2. A 42-year-old woman with calcific tendinitis of the lateral head of flexor hallucis brevis. a, b. Anteroposterior and tangential radiographs of the left first metatarsophalangeal joint show stippled and ovoid calcifications around the lateral sesamoid bone (arrow). Sagittal T1-weighted (c) and fat-suppressed proton density-weighted (d) images show irregular calcifications (arrowheads) in the lateral head of the flexor hallucis brevis tendon and muscle and soft tissue edema around the calcifications. The lateral sesamoid bone is indicated (arrow).

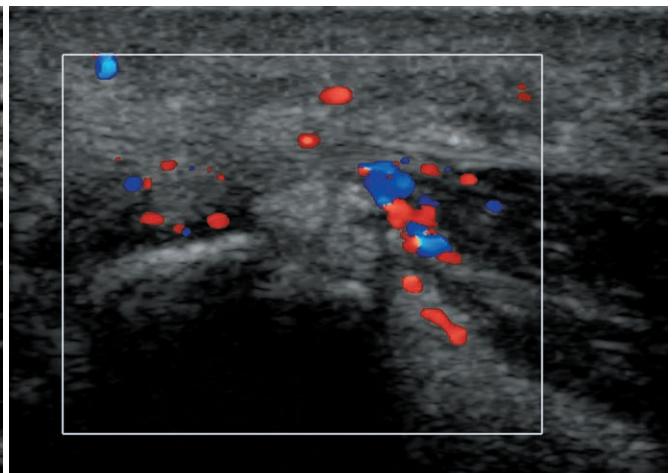


a

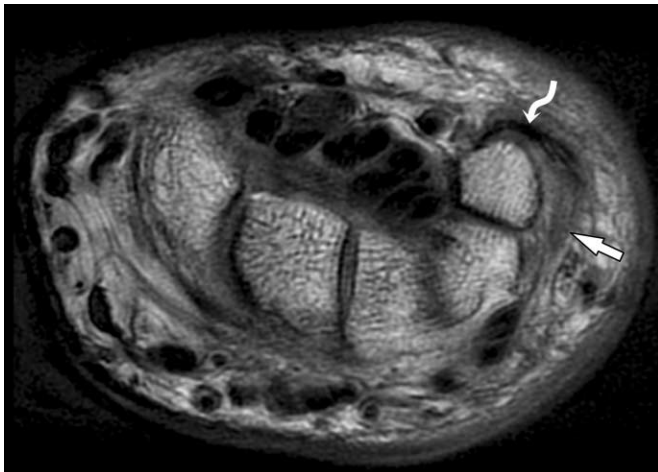
b



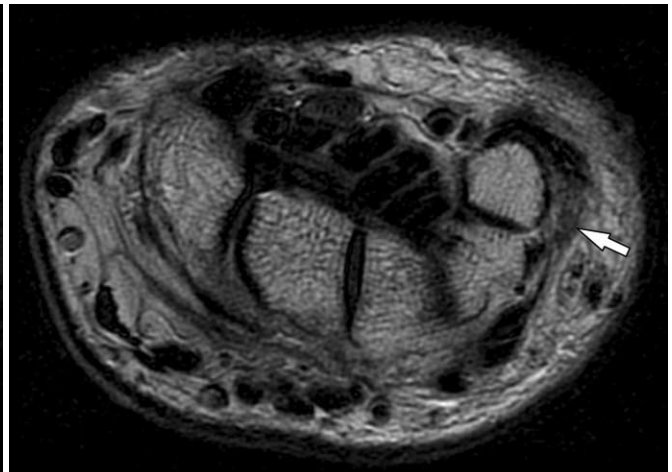
c



d



e



f

Fig. 3. A 61-year-old man with calcific tendinitis of the abductor digiti minimi. Posteroanterior radiograph (a) and CT (b) of the left wrist show a small calcification (arrow) medial to the pisiform. c. Longitudinal US shows lobulated calcific deposits (arrowheads) in the origin of abductor digiti minimi, adjacent to the pisiform. d. Color Doppler US reveals increased vascularity around the calcific deposits. On axial T1-weighted (e) and T2-weighted (f) images, the calcification is seen as an ill-defined low signal intensity lesion (arrow) in the abductor digiti minimi muscle. Mild soft tissue edema is seen around the calcification. Flexor carpi ulnaris tendon (curved arrow) is indicated. p = pisiform, adm = abductor digiti minimi muscle.

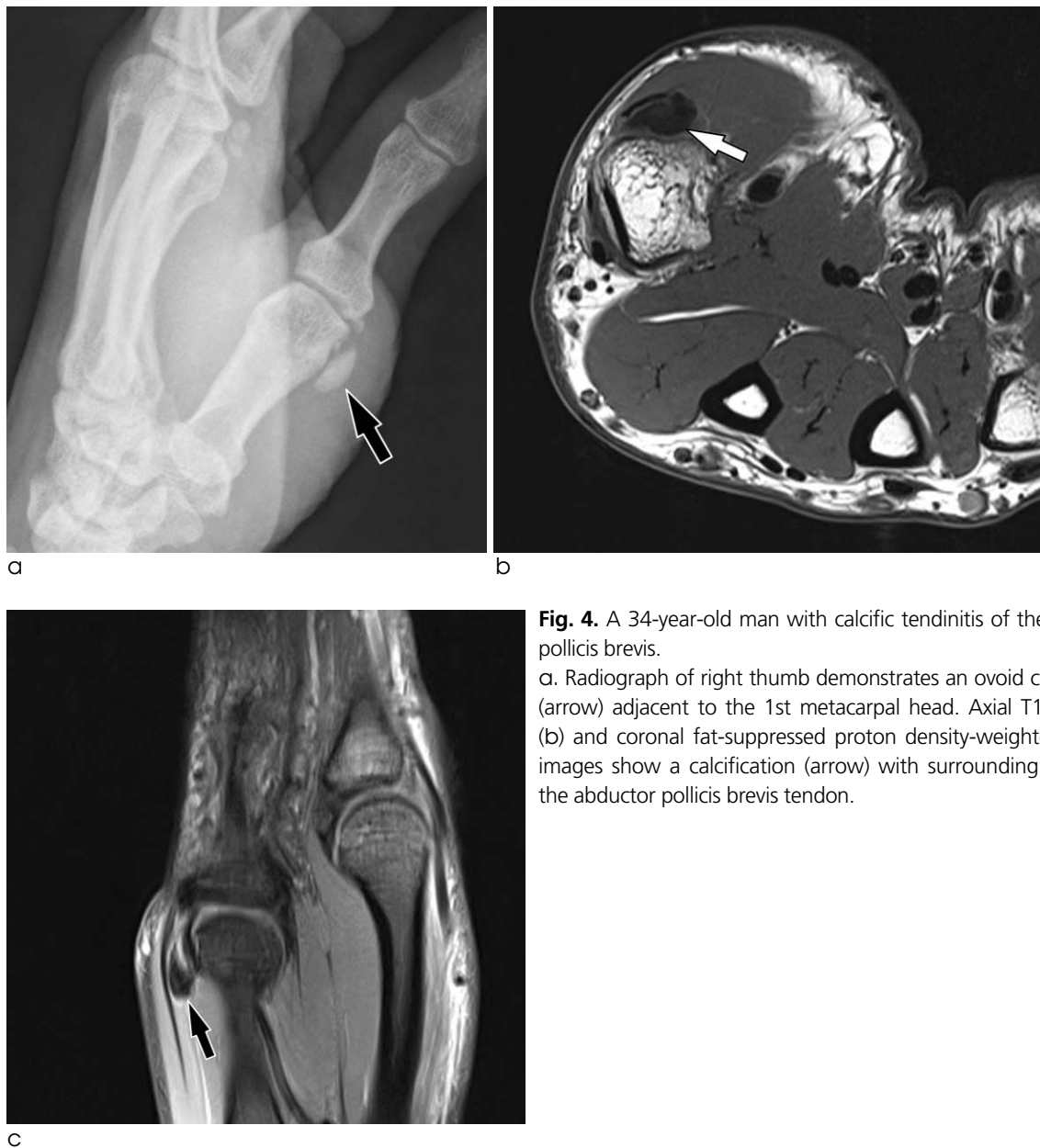

Fig. 4. A 34-year-old man with calcific tendinitis of the abductor pollicis brevis.

a. Radiograph of right thumb demonstrates an ovoid calcification (arrow) adjacent to the 1st metacarpal head. Axial T1-weighted (b) and coronal fat-suppressed proton density-weighted (c) MR images show a calcification (arrow) with surrounding edema in the abductor pollicis brevis tendon.

delayed due to unusual location of calcification. Often calcific tendinitis of hand and feet will be evaluated with CT, US, or MR imaging first because of a initial presumptive diagnosis of infection rather than calcific tendinitis.

CT is superior to radiography for the detection and delineation of the intratendinous calcification than conventional radiography. CT is recommended when radiography fails to detect calcifications. US is useful in determining the precise status of the tendon and has already been suggested to be a diagnostic tool for patients with calcific tendinitis of the rotator cuff (2). US diagnosis of calcific tendinitis of the hand and foot

have been rarely reported in the literature (8). US findings include hyperechoic calcific foci, a thickening of tendon, and increased vascularity on color Doppler US (3). Calcific foci show ovoid, mottled, or amorphous hyperechoic shadow with or without posterior acoustic shadowing. US allows confirmation of their intratendinous location.

MR findings of calcific tendinitis of the hand and foot have been reported sporadically (7). MR imaging is suboptimal for detecting soft tissue calcification. Calcification is seen as focus of low signal intensity on all imaging sequences, but is frequently quite inconspicuous. In addition to calcification, other MR

findings of calcific tendinitis include inflammatory edematous soft tissue change surrounding the calcification and adjacent bone marrow edema (3). Bone marrow edema is common in the hip and shoulder, but has not been reported in the patients with calcific tendinitis of hand and foot. In our cases, medial sesamoid marrow edema was encountered in patients with calcific tendinitis of flexor hallucis brevis. MR imaging offers superior in detection of soft tissue and bone marrow edema, but may lead to false presumption of infection or other disease entities (3).

Calcific tendinitis of hand and foot is a self-limiting process and treatment is conservative. The traditional treatment includes oral nonsteroidal anti-inflammatory drugs, resting splint, local anesthetic/steroid injections, and puncture for aspirating the calcium deposit (4-7). Surgical evacuation is no longer advocated. Patient's symptom is usually reduced within 4-7 days after the acute onset of pain. On radiographs, calcific deposits disappear or markedly decrease within several weeks (5, 7).

Calcific tendinitis of hand and foot is a rare condition. It is often unrecognized because of its rarity and nonspecific clinical presentation and also because of unfamiliar MR findings and misinterpretation of initial radiographs. Here, four cases of calcific tendini-

tis of hand and foot were reported and may increase awareness of imaging findings of this rare condition.

References

1. Siegal DS, Wu JS, Newman JS, Del Cura JL, Hochman MG. Calcific tendinitis: a pictorial review. *Can Assoc Radiol J* 2009;60:263-272
2. Farin PU, Jaroma Heikki. Sonographic findings of rotator cuff calcifications. *J Ultrasound Med* 1995;14:7-14
3. Lee HS, Lee YH, Sung NK, et al. Sonographic Findings of Calcific Tendinitis around the Hip. *J Korean Soc Ultrasound Med* 2005;24:139-144
4. Shields JS, Chhabra AB, Pannunzio ME. Acute calcific tendinitis of the hand: 2 case reports involving the abductor pollicis brevis. *Am J Orthop* 2007;36:605-607
5. Dumas C, Vazirani RM, Clifford PD, Owens P. Acute calcific periartthritis of the hand and wrist: a series and review of the literature. *Emerg Radiol* 2007;14:199-203
6. Harris AR, McNamara TR, Brault JS, Rizzo M. An unusual presentation of acute calcific tendinitis in the hand. *Hand* 2009;4:81-83
7. Hakozaki M, Iwabuchi M, Konno S, Kikuchi S. Acute calcific tendinitis of the thumb in a child: a case report. *Clin Rheumatol* 2007;26:841-844
8. Woo JH, Lee S, Hong SJ, Song GG. Calcific tendinitis of flexor carpi ulnaris insertion site. *J Korean Rheum Assoc* 2010;17:98-99
9. Klammer G, Iselin LD, Bonel HM, Weber M. Calcific tendinitis of the peroneus longus: case report. *Foot Ankle Int* 2011;32:638-640

대한자기공명영상의학학회지 16:177-183(2012)

손과 발에 생긴 석회화 건염: 4예 보고

¹대구가톨릭대학교 의과대학 영상의학교실

²포항성모병원 영상의학과

³동국대학교 의과대학 경주병원 영상의학교실

이형욱¹ · 이영환¹ · 문성희¹ · 강웅래¹ · 이채경² · 서경진³

손과 발의 석회화 건염은 드문 질환으로, 임상 양상이 감염 등의 다른 질환과 유사하기 때문에 흔히 오진할 수 있다. 병변의 특징적 위치와 영상 소견을 잘 이해하는 것이 병의 정확한 진단에 중요하다. 저자들은 단족무지굴근, 소지외전근, 그리고 단무지외전근에 생긴 4예의 석회화 건염을 보고한다.

통신저자 : 이영환, (705-718) 대구시 남구 대명4동 3056-6, 대구가톨릭대학교 의과대학 영상의학교실
Tel. (053) 650-4329 Fax. (053) 650-4339 E-mail: yhlee@cu.ac.kr