

# Cone-beam computed tomographic evaluation of the condylar remodeling occurring after mandibular set-back by bilateral sagittal split ramus osteotomy and rigid fixation

Man-Hee Ha<sup>a</sup>  
Yong-Il Kim<sup>a,b,c</sup>  
Soo-Byung Park<sup>a</sup>  
Seong-Sik Kim<sup>a</sup>  
Woo-Sung Son<sup>a</sup>

<sup>a</sup>Department of Orthodontics, School of Dentistry, Pusan National University, Yangsan, Korea

<sup>b</sup>Biomedical Research Institute, Pusan National University Hospital, Busan, Korea

<sup>c</sup>Dental Research Institute, Pusan National University Dental Hospital, Yangsan, Korea

**Objective:** To evaluate condylar head remodeling after mandibular set-back sagittal split ramus osteotomy (SSRO) with rigid fixation in skeletal class III deformities. The correlation between condylar head remodeling and condylar axis changes was determined using cone-beam computed tomography (CBCT) superimposition. **Methods:** The CBCT data of 22 subjects (9 men and 13 women) who had undergone mandibular set-back SSRO with rigid fixation were analyzed. Changes in the condylar head measurements and the distribution of the signs of condylar head remodeling were evaluated by CBCT superimposition. **Results:** The subjects showed inward rotation of the axial condylar angle; reduced condylar heights on the sagittal and coronal planes; and resorptive remodeling in the anterior and superior areas on the sagittal plane, superior and lateral areas on the coronal plane, and anterior-middle and anterior-lateral areas on the axial plane ( $p < 0.05$ ). **Conclusions:** The CBCT superimposition method showed condylar head remodeling after mandibular set-back SSRO with rigid fixation. In skeletal class III patients, SSRO with rigid fixation resulted in rotation, diminution, and remodeling of the condylar head. However, these changes did not produce clinical signs or symptoms of temporomandibular disorders.

[Korean J Orthod 2013;43(6):263-270]

**Key words:** Cone-beam computed tomography, Class III orthognathic surgery, Surgery

Received April 25, 2013; Revised July 3, 2013; Accepted July 4, 2013.

**Corresponding author:** Yong-Il Kim.

Assistant Professor, Department of Orthodontics, School of Dentistry, Pusan National University, Biomedical Research Institute of Pusan National University Hospital, 179 Gudeok-ro, Seo-gu, Busan 602-739, Korea.

Tel +82-51-240-7432 e-mail kimyongil@pusan.ac.kr

\*This work was supported by a 2-year research grant from Pusan National University.

The authors report no commercial, proprietary, or financial interest in the products or companies described in this article.

© 2013 The Korean Association of Orthodontists.

This is an Open Access article distributed under the terms of the Creative Commons Attribution Non-Commercial License (<http://creativecommons.org/licenses/by-nc/3.0>) which permits unrestricted non-commercial use, distribution, and reproduction in any medium, provided the original work is properly cited.

## INTRODUCTION

Among orthognathic surgery procedures that can induce condylar position changes, sagittal split ramus osteotomy (SSRO) is one of the most frequently performed. This procedure offers several advantages, including an improved bony interface between the segments, rigid fixation, and rapid recovery of oral function. However, rigid fixation by SSRO, in comparison with non-rigid fixation, can induce greater changes in the condylar position and the axis of the condyle as well as higher incidences of temporomandibular disorder (TMD).<sup>1,2</sup> Several studies have shown condylar displacement after mandibular set-back SSRO and elucidated the influence of mandibular set-back or lengthening osteotomy on the post-treatment osseous morphology of the temporomandibular joint (TMJ).<sup>3-5</sup> However, these displacements and their accompanying morphologic changes did not lead to TMJ dysfunction because they occurred within the range of the natural adaptive mechanisms actuating after orthognathic surgery, such as glenoid fossa remodeling, condylar remodeling, and condylar repositioning within the fossa, which can attenuate the incidence of TMJ dysfunction.<sup>6,7</sup> A double contour of the condylar head and/or the mandibular fossa has been reported to be a specific radiographic indication of remodeling activity, and this distinct double contour, specifically in the posterior area of the condylar head, was found in most of the joints studied in that report.<sup>8</sup> Condylar remodeling has also been reported in other long-term post-operative radiographic examinations.<sup>9</sup> However, only a few studies have utilized cone-beam computed tomography (CBCT) to investigate physiologic condylar head remodeling after orthognathic surgery in cases involving skeletal class III deformity.<sup>5</sup>

For accurate and effective CBCT-based comparison of remodeled areas, precise superimposition of CBCT images is essential, because the sliced multiplanar reformation (MPR) images vary according to the reference plane. For successful CBCT volume superimposition under these conditions, 3-dimensional (3D) medical imaging software programs using mutual information registration can be employed.<sup>10</sup> The aim of this study was to evaluate condylar head remodeling after mandibular set-back by bilateral SSRO with rigid fixation in skeletal class III deformities by using CBCT superimposition and to determine the correlation between the condylar head remodeling and changes in the condylar axis.

## MATERIALS AND METHODS

### Subjects and data acquisition

The study protocol was reviewed and approved by the

ethics committee at Pusan National University Hospital (#2009062). The subjects were 22 adults (9 men and 13 women; mean age,  $22.8 \pm 2.9$  years) diagnosed with skeletal class III malocclusion. These subjects underwent modified Hunsuck SSRO with rigid fixation, which was performed by 2 oral surgeons in the Department of Oral and Maxillofacial Surgery, Pusan National University Dental Hospital. The inclusion criteria were as follows: healthy physical condition; no severe facial asymmetry; no TMD symptoms and degenerative joint disease on examination; and skeletal angle class III. In SSRO, rigid intermaxillary fixation was carried out with bicortical screws. The skeletal fixation was followed by release of maxillo-mandibular fixation (MMF), after which the condylar and occlusal positions were checked. One week after MMF, patients received physiotherapy.

CBCT (Pax-Zenith3D; Vatech Co., Seoul, Korea) was used to evaluate the condylar remodeling and skeletal changes before and after surgery (average interval between examinations,  $15.8 \pm 3.7$  months). The maxillofacial regions were scanned using a CBCT machine with a field of view of  $20 \times 19$  cm, a tube voltage of 110 kVp, a tube current of 4.0 mA, voxel size of 0.3 mm, and a scan time of 24 seconds. The CBCT data were reformatted into Digital Imaging and Communications in Medicine (DICOM) format and reconstructed with 3D image software.

### Superimposition method for skeletal and condylar axis changes and head remodeling

The anterior cranial base was used as the registration area for skeletal and condylar axis changes. The condylar neck and the posterior ramal area above the lingula of the mandible were registered for condylar head remodeling using OnDemand3D™ software (Cybermed Technology Co., Seoul, Korea). In this study, the superimposition method allows accurate, rapid, and automatic superimposition without segmentation or landmark definition. To superimpose the CBCT data, the investigator designated the registration areas, such as anterior cranial base and ramus region, on the MPR images. The software automatically calculated the best registration areas using the mutual information algorithm. After superimposition, data analysis was performed.<sup>10</sup> The reference planes and axes for skeletal and condylar axis changes were defined in a previous study.<sup>11</sup> The measurements were obtained under the same scanning conditions (grayscale: bit depth 14 bit, window width: 4,000, window level: 1,000).

### Measurements of the condylar head

For analysis of the condylar head remodeling, the superimposed condylar head images were compared with regard to their width and depth on the axial plane,

width and height on the coronal plane, and height and depth on the sagittal plane; the measurements were obtained according to the method reported by Hoppenreijts et al.<sup>3</sup> (Figure 1).

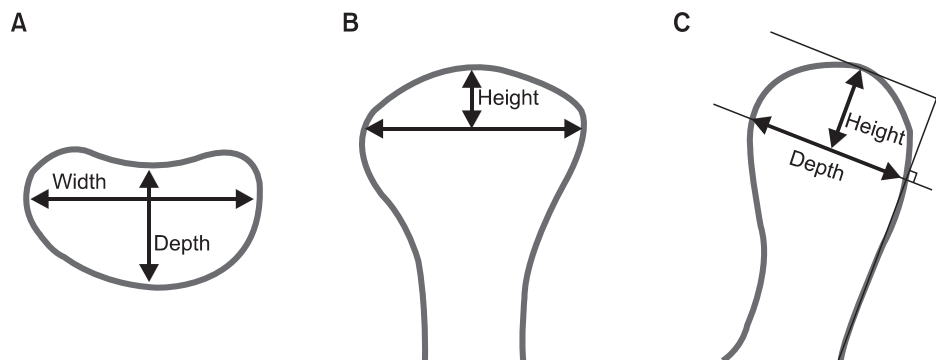
**Assessment of remodeling areas**

On the basis of the signs of condylar head remodeling, the superimposed axial, coronal, and sagittal pre- and postoperative images were classified as “bone resorption; loss or reduction of the shape and size of the bone,” “bone formation; increase of the shape and size of the bone,” or “unchanged; no significant change in the shape and size of the bone.” Three areas (medial, superior, lateral) on the coronal plane, 3 (anterior, superior, posterior) on the sagittal plane, and 6 (anteromedial, anterior-middle, anterolateral, postero-medial, posterior-middle, posterolateral) on the axial plane were examined for each condyle (Figure 2).

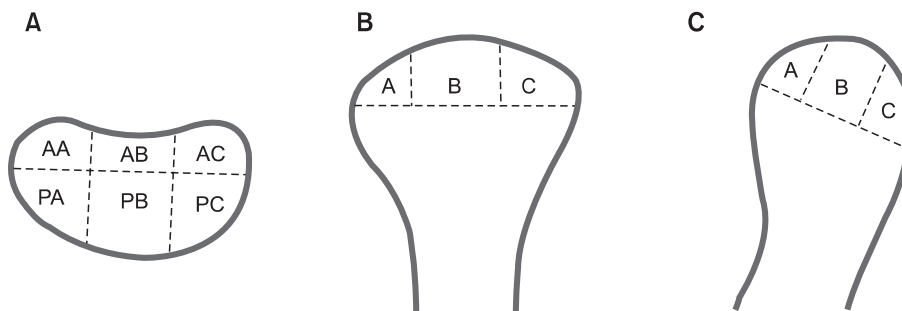
**Statistical analysis**

The data were statistically analyzed using PASW

Statistics version 18.0 for Windows (IBM Co., Armonk, NY, USA). Pre- and postoperative comparisons of the changes in the condylar axis and the measurements of the condylar heads were made using a paired t-test. Pearson correlation coefficients were calculated to analyze the correlation between the magnitude of mandibular set-back and condylar axis changes. The condylar remodeling sign distribution data for the right and left sides were compared using the Wilcoxon signed rank test ( $p < 0.05$ ). To isolate the distribution of the condylar head remodeling signs, chi-square tests were performed in each predefined area between the pre- and postoperative stages. The Shapiro-Wilks normality test was applied to the data, which were found to be normally distributed. The reproducibility for the superimposition of the condylar remodeling signs was assessed using Cohen’s kappa index ( $\kappa$ ). In this study, the reproducibility for the superimposition of the condylar remodeling signs showed substantial agreement: Cohen’s kappa index for intra-investigator agreement was 0.72, and that for inter-investigator agreement was 0.67.



**Figure 1.** Two-dimensional metric analysis of the condylar head before and after surgery: condylar width and depth on the axial plane (A), condylar width and height on the coronal plane (B), and condylar depth and height on the sagittal plane (C).



**Figure 2.** Image interpretation for the assessment of remodeling signs: the areas for the classification of the remodeling signs. A, Anterior-medial (AA), anterior-middle (AB), anterior-lateral (AC), posterior-medial (PA), posterior-middle (PB), and posterior-lateral (PC) in the axial plane. B, Medial (A), superior (B), and lateral (C) in the coronal plane. C, Anterior (A), superior (B), and posterior (C) in the sagittal plane.

**RESULTS**

The mean amount of mandibular set-back was 6.8 ± 2.2 mm. The mean vertical change of the mandible (FH plane to Me) was 1.7 ± 6.6 mm, which was not significant (*p* > 0.05).

The pre- and postoperative right and left condylar axis angles (°) on the axial planes were significantly different (*p* < 0.05; Table 1). There was no significant correlation between the amount of mandibular set-back and condylar axis changes (*p* > 0.05). Measurements of the condylar head showed no changes on the axial plane.

**Table 1.** Differences of condylar axis angle on the axial, coronal, and sagittal planes

	Condylar axis angle (°)		<i>p</i> -value
	Pre-operative	Post-operative	
On Axial plane			
Right	75.05 ± 5.96	69.31 ± 6.62	< 0.001*
Left	75.59 ± 6.11	70.26 ± 5.86	< 0.001*
On Coronal plane			
Right	80.22 ± 3.63	80.68 ± 4.31	0.423
Left	81.37 ± 3.05	81.82 ± 2.99	0.495
On Sagittal plane			
Right	81.41 ± 4.05	80.01 ± 5.49	0.130
Left	80.78 ± 4.97	79.52 ± 4.83	0.074

Values are presented as mean ± standard deviation. Paired t-test was done; \**p* < 0.05.

However, the values obtained on the sagittal and coronal planes indicated a statistically significant postoperative diminution in the condylar height (*p* < 0.05; Table 2 and Figure 3).

The distribution of condylar remodeling signs showed no significant difference between the right and left condyles (*p* > 0.05). However, a chi-square test comparison of the distribution showed that bone resorption predominantly occurred on the anterior and superior areas on the sagittal planes (*p* < 0.05; Table 3). On the coronal planes, resorption was predominantly observed on the superior and lateral areas, as in the case of the anterior-middle and anterior-lateral areas on the axial planes (*p* < 0.05).

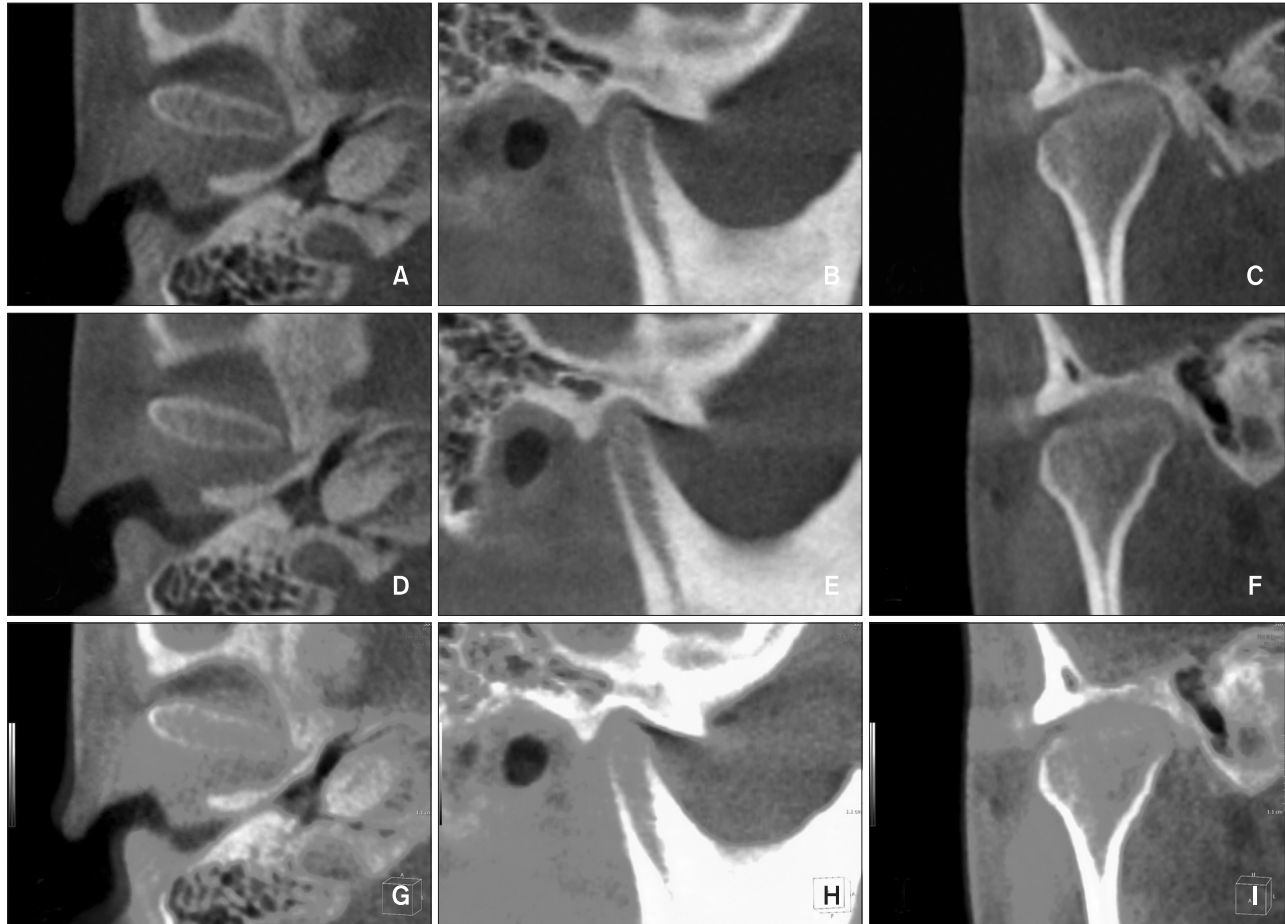
**DISCUSSION**

In a radiographic study on condylar remodeling, Hollender and Ridell<sup>8</sup> found a distinct double contour in the posterior area of the condylar head. They insisted that such a manifestation, whether of the condylar head or the glenoid fossa, indicates remodeling activity.<sup>8</sup> Similar findings were reported in other studies.<sup>6,12,13</sup> However, direct evidence of postoperative TMJ remodeling is difficult to obtain in 2-dimensional radiographic analysis. To resolve this limitation, a fully automated system with mutual information registration was used in this study. Structures that remain stable after orthognathic surgery, i.e., the cranial bases, the condylar neck, and the posterior ramal area above the lingula of the mandible, were referenced to compare the skeletal and condylar axis changes and remodeling.<sup>10,11</sup>

**Table 2.** Pre-operative and post-operative measurements of the condylar heads

			Metric analysis (mm)		<i>p</i> -value
			Pre-operative	Post-operative	
Right	Sagittal	Width	7.18 ± 1.19	7.10 ± 1.21	0.350
		Height	3.13 ± 0.89	2.93 ± 0.85	0.013*
	Axial	Width	17.38 ± 2.55	17.03 ± 2.77	0.077
		Depth	7.47 ± 1.19	7.21 ± 1.12	0.115
	Coronal	Width	19.91 ± 2.33	19.76 ± 2.30	0.106
		Height	7.14 ± 1.65	6.78 ± 1.71	0.030*
Left	Sagittal	Width	7.98 ± 1.23	7.45 ± 1.84	0.135
		Height	3.24 ± 0.70	3.00 ± 0.66	0.035*
	Axial	Width	17.58 ± 2.27	17.28 ± 2.37	0.220
		Depth	7.91 ± 1.13	7.82 ± 1.06	0.499
	Coronal	Width	20.01 ± 2.25	19.94 ± 2.21	0.599
		Height	6.77 ± 1.52	6.55 ± 1.43	0.045*

Values are presented as mean ± standard deviation. Paired t-test was done; \**p* < 0.05.



**Figure 3.** Superimposition for condylar head remodeling: axial (A), sagittal (B), and coronal (C) in preoperative images; axial (D), sagittal (E), and coronal (F) in postoperative images; and axial (G), sagittal (H), and coronal (I) in superimposed images.

Several lateral cephalography studies have reported condylar remodeling and resorption in the antero-superior aspects of the condyles after orthognathic surgery.<sup>3,14-16</sup> The results of the present study were consistent with those findings: the condylar heights on the sagittal and coronal planes reduced after surgery ( $p < 0.05$ ; Table 2) and the anterior and superior areas on the sagittal plane showed prominent bone resorption ( $p < 0.05$ ; Table 3). Park et al.<sup>11</sup> also reported the same results in two-jaw surgery cases. The extent of increase in the condylar height was not significant with reference to the voxel size of CBCT machine. These clinically insignificant changes could not produce clinical signs and symptoms of TMD.

Condylar remodeling during repositioning of the mandible may be attributed to mechanical force, specifically overloading.<sup>7</sup> Hoppenreijts et al.<sup>3</sup> reported that rigid fixation is also an important factor influencing condylar morphologic changes and that a rigid-fixation group showed condylar remodeling. Other studies suggested

that inward rotation of the condylar head on the axial plane following mandibular set-back surgery could be an important factor inducing remodeling ( $p < 0.005$ ; Table 1).<sup>17,18</sup> The present study evaluated the effect of the amount of mandibular set-back on the condylar axis changes and remodeling and their correlation; however, no statistically significant correlation was noted ( $p > 0.05$ ).

In the present study, most areas of the condylar heads showed various degrees of change. The anterior and superior areas on the sagittal plane, the superior and lateral areas on the coronal plane, and the anterior-middle and anterior-lateral areas on the axial plane predominantly showed signs of resorption ( $p < 0.05$ ; Table 3). However, on the axial plane, these signs were predominantly observed in the anterior-middle and anterolateral areas. Park et al.<sup>11</sup> showed similar results in cases involving 2-jaw surgery, although in their study, these signs were predominantly observed in the anteromedial, anterolateral, and posterolateral areas on the axial plane.

**Table 3.** Distribution of the condylar remodeling signs on the sagittal, coronal, and axial planes according to condylar area

		Remodeling sign (n = 44)			p-value
		Bone resorption	Unchanged	Bone formation	
Sagittal	Anterior	27 (61.4)	8 (18.2)	9 (20.5)	< 0.001*
	Superior	31 (70.5)	4 (9.1)	9 (20.5)	< 0.001*
	Posterior	18 (40.9)	9 (20.5)	17 (38.6)	0.190
Coronal	Medial	15 (34.1)	8 (18.2)	21 (47.7)	0.056
	Superior	26 (59.1)	10 (22.7)	8 (18.2)	0.001*
	Lateral	29 (65.9)	4 (9.1)	11 (25.0)	< 0.001*
Axial	Anteromedial	15 (34.1)	10 (22.7)	19 (43.2)	0.250
	Anterior-middle	25 (56.8)	10 (22.7)	9 (20.5)	0.004*
	Anterolateral	26 (59.1)	7 (15.9)	11 (25.0)	0.001*
	Posteromedial	15 (34.1)	9 (20.5)	20 (45.5)	0.126
	Posterior-middle	9 (20.5)	16 (36.4)	19 (43.2)	0.166
	Posterolateral	19 (43.2)	11 (25.0)	14 (31.8)	0.328

Values are presented as number (%).  
Chi-square test was done; \* $p < 0.05$ .

These differences in the distribution of the regions showing prominent changes may have resulted from differences in the sample size rather than differences in the type of orthognathic surgery. The anterolateral area on the axial plane was a common resorption area in both studies. Resorption in this area might be influenced by the inward rotation of the axial condylar axis (Table 3). Further studies with larger sample sizes and control subjects should be performed to elucidate these findings. Several computed tomography studies suggested that the degree of postoperative condylar long-axis alteration might be a predictive factor of condylar remodeling.<sup>5,8,9,19,20</sup> The movement associated with this alteration imparts compressive loading to the condyle and glenoid fossa, which could be one of factors related to condylar remodeling. However, in the present study, remodeling occurred in most areas of the condylar head. Among the different signs of remodeling, resorptive remodeling was predominant only in limited areas: the anterior and superior areas on the sagittal plane; the superior and lateral areas on the coronal plane; and the anterior-middle and anterior-lateral areas on the axial plane. These results differed from those of the previous study, which reported bone formation in the posterior region of condylar head.<sup>21</sup> However, our results were consistent with those obtained in studies involving mandibular advancement surgery, which showed that condylar resorption usually occurred on the anterior-superior surface of the condyle, and not

the posterior surface.<sup>3,14,16</sup> The posteriorly directed force after mandibular advancement does not appear to have a direct influence on the development of condylar resorption. In our study, condylar resorption was predominantly observed on the anterosuperior surface of the condyle, and not the posterior surface as observed in the previous reports with mandibular set-back movement. The condylar remodeling in the sagittal and coronal aspects might be related to the complex mechanical vector mechanisms between the musculature and proximal segment rotation and the less dense surface of the condyle.<sup>22</sup> As mentioned previously, a double contour of the condylar head and/or mandibular fossa is noted as the specific radiographic indication of remodeling activity.<sup>8</sup> Moreover, Liu et al.<sup>23</sup> also reported that this distinct double contour in the posterior area of the condylar head. However in this study, we did not find a double contour of the condylar head. Further studies would be needed with a large sample size and long-term data to clarify this discrepancy.

Several studies have found that individual adaptive capacity is related to systemic factors such as age, auto-immune system function, endocrine system, and metabolic disorders. These factors might influence fibrocartilage metabolism and blood supply, thereby contributing to resorptive changes.<sup>24</sup> O’Ryan and Epker<sup>22</sup> found a difference in the trabecular pattern of condyles between high- and low-angle patients. Condyles in patients with anterior open bite appear to be very sensitive to

functional loading and their adaptive capacity probably is smaller than in patients with deep bites.<sup>21,22</sup> Patients presenting with predispositional factors relating to condylar adaptive capacities, therefore, should be informed about the possibility of condylar resorption and its possible effects on stability.

## CONCLUSION

Even though many patients can adapt to occlusion or condylar positions that are not considered ideal, in orthognathic surgery patients, the range of the physiologic adaptation should be studied further because the surgery changes the stomatognathic environment. It should also be considered that patients with risk factors for imbalance of the adaptive ability and masticatory system would experience difficulty in physiologic adaptation.

## REFERENCES

- Paulus GW, Steinhauser EW. A comparative study of wire osteosynthesis versus bone screws in the treatment of mandibular prognathism. *Oral Surg Oral Med Oral Pathol* 1982;54:2-6.
- Timmis DP, Aragon SB, Van Sickels JE. Masticatory dysfunction with rigid and nonrigid osteosynthesis of sagittal split osteotomies. *Oral Surg Oral Med Oral Pathol* 1986;62:119-23.
- Hoppenreijts TJ, Freihofer HP, Stoelinga PJ, Tuinzing DB, van't Hof MA. Condylar remodeling and resorption after Le Fort I and bimaxillary osteotomies in patients with anterior open bite. A clinical and radiological study. *Int J Oral Maxillofac Surg* 1998;27:81-91.
- Huang CS, de Villa GH, Liou EJ, Chen YR. Mandibular remodeling after bilateral sagittal split osteotomy for prognathism of the mandible. *J Oral Maxillofac Surg* 2006;64:167-72.
- Katsumata A, Nojiri M, Fujishita M, Arijii Y, Arijii E, Langlais RP. Condylar head remodeling following mandibular setback osteotomy for prognathism: a comparative study of different imaging modalities. *Oral Surg Oral Med Oral Pathol Oral Radiol Endod* 2006;101:505-14.
- Voudouris JC, Woodside DG, Altuna G, Angelopoulos G, Bourque PJ, Lacouture CY, et al. Condyle-fossa modifications and muscle interactions during Herbst treatment, Part 2. Results and conclusions. *Am J Orthod Dentofacial Orthop* 2003;124:13-29.
- Papachristou DJ, Papachroni KK, Papavassiliou GA, Pirttiniemi P, Gorgoulis VG, Piperi C, et al. Functional alterations in mechanical loading of condylar cartilage induces changes in the bony subcondylar region. *Arch Oral Biol* 2009;54:1035-45.
- Hollender L, Ridell A. Radiography of the temporomandibular joint after oblique sliding osteotomy of the mandibular rami. *Scand J Dent Res* 1974;82:466-9.
- Eckerdal O, Sund G, Astrand P. Skeletal remodelling in the temporomandibular joint after oblique sliding osteotomy of the mandibular rami. *Int J Oral Maxillofac Surg* 1986;15:233-9.
- Choi JH, Mah J. A new method for superimposition of CBCT volumes. *J Clin Orthod* 2010;44:303-12.
- Park SB, Yang YM, Kim YI, Cho BH, Jung YH, Hwang DS. Effect of bimaxillary surgery on adaptive condylar head remodeling: metric analysis and image interpretation using cone-beam computed tomography volume superimposition. *J Oral Maxillofac Surg* 2012;70:1951-9.
- Hackney FL, Van Sickels JE, Nummikoski PV. Condylar displacement and temporomandibular joint dysfunction following bilateral sagittal split osteotomy and rigid fixation. *J Oral Maxillofac Surg* 1989;47:223-7.
- Rotskoff KS, Herbosa EG, Nickels B. Correction of condylar displacement following intraoral vertical ramus osteotomy. *J Oral Maxillofac Surg* 1991;49:366-72.
- Kerstens HC, Tuinzing DB, Golding RP, van der Kwast WA. Condylar atrophy and osteoarthritis after bimaxillary surgery. *Oral Surg Oral Med Oral Pathol* 1990;69:274-80.
- Mongini F. Condylar remodeling after occlusal therapy. *J Prosthet Dent* 1980;43:568-77.
- Moore KE, Gooris PJ, Stoelinga PJ. The contributing role of condylar resorption to skeletal relapse following mandibular advancement surgery: report of five cases. *J Oral Maxillofac Surg* 1991;49:448-60.
- Kim YI, Jung YH, Cho BH, Kim JR, Kim SS, Son WS, et al. The assessment of the short- and long-term changes in the condylar position following sagittal split ramus osteotomy (SSRO) with rigid fixation. *J Oral Rehabil* 2010;37:262-70.
- Ueki K, Marukawa K, Nakagawa K, Yamamoto E. Condylar and temporomandibular joint disc positions after mandibular osteotomy for prognathism. *J Oral Maxillofac Surg* 2002;60:1424-32.
- Ruf S, Pancherz H. Temporomandibular joint remodeling in adolescents and young adults during Herbst treatment: A prospective longitudinal magnetic resonance imaging and cephalometric radiographic investigation. *Am J Orthod Dentofacial Orthop* 1999;115:607-18.
- Kinzinger G, Kober C, Diedrich P. Topography and morphology of the mandibular condyle during fixed functional orthopedic treatment—a magnetic

- resonance imaging study. *J Orofac Orthop* 2007; 68:124-47.
21. Kawamata A, Fujishita M, Nagahara K, Kanematu N, Niwa K, Langlais RP. Three-dimensional computed tomography evaluation of postsurgical condylar displacement after mandibular osteotomy. *Oral Surg Oral Med Oral Pathol Oral Radiol Endod* 1998;85: 371-6.
  22. O’Ryan F, Epker BN. Temporomandibular joint function and morphology: observations on the spectra of normalcy. *Oral Surg Oral Med Oral Pathol* 1984;58:272-9.
  23. Liu MQ, Chen HM, Yap AU, Fu KY. Condylar remodeling accompanying splint therapy: a cone-beam computerized tomography study of patients with temporomandibular joint disk displacement. *Oral Surg Oral Med Oral Pathol Oral Radiol* 2012; 114:259-65.
  24. Papadaki ME, Tayebaty F, Kaban LB, Troulis MJ. Condylar resorption. *Oral Maxillofac Surg Clin North Am* 2007;19:223-34.