

Floating Thrombus in Aortic Arch

Tae Ook Noh, M.D., Pil Won Seo, M.D.

Floating thrombi in the aortic arch are very rare and an unusual source of systemic embolism. Herein, a case of a 3-cm thrombus in the aortic arch is reported. It was a floating, highly mobile thrombus attached to the lesser curvature of the aortic arch. The patients had a hypercoagulable disorder induced by protein C and S deficiency. The thrombus was operatively removed with a favorable outcome.

Key words: 1. Thrombosis
2. Aorta
3. Embolism

CASE REPORT

A 56-year-old man was hospitalized because of pain and numbness in his left hand since he slipped a week earlier. He had no medical history of diabetes or hypertension. He had a thirty pack-year smoking history. In the physical examination, we found that the motor and sensory functions of his left hand were normal. However, his radial artery had no pulsation. His laboratory data, including anti nuclear antibody, anti-neutrophil cytoplasmic antibody, and rheumatoid arthritis factor, were within normal limits. However, the laboratory analysis showed decreased protein C and S concentrations (protein C antigen, 57%; protein S antigen, 19%). The diagnostic work-up to determine the degree of lesion included a computed tomography (CT) angiography, which showed an intraluminal lesion of the left upper extremities vessel. In the CT scan, the deep brachial and radial artery of the left hand was occluded (Fig. 1). Coincidentally, we stumbled across a mass lesion on the aortic arch. For the evaluation of the incidental mass lesion, we performed a chest CT scan and

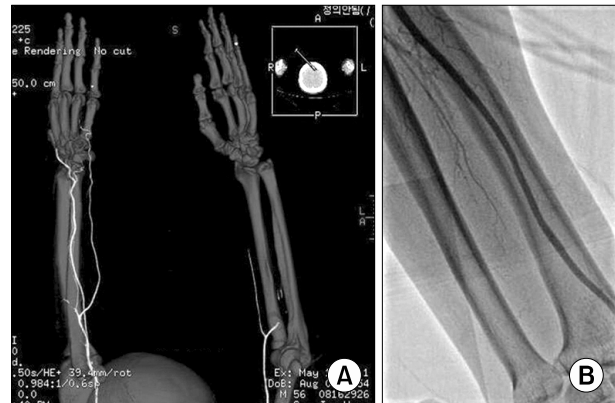

Fig. 1. A computed tomography scan (A) shows an obstruction of the brachial artery. After thrombectomy, the brachial artery shows good blood flow in peripheral angiography (B).

transthoracic echocardiography. The ascending aorta and the aortic arch had intact intima and a normal size (Fig. 2). In transthoracic echocardiography, we found a floating mass in the lesser curvature of the aortic arch (Fig. 3). We decided to surgically remove this floating mass because of the risk of

Department of Thoracic and Cardiovascular Surgery, Dankook University College of Medicine

Received: June 24, 2013, Revised: August 20, 2013, Accepted: August 21, 2013

Corresponding author: Pil Won Seo, Department of Thoracic and Cardiovascular Surgery, Dankook University College of Medicine, 119 Dandae-ro, Dongnam-gu, Cheonan 330-997, Korea
(Tel) 82-41-550-6269 (Fax) 82-41-550-6269 (E-mail) pwseo@dankook.ac.kr

© The Korean Society for Thoracic and Cardiovascular Surgery. 2013. All right reserved.

© This is an open access article distributed under the terms of the Creative Commons Attribution Non-Commercial License (<http://creativecommons.org/licenses/by-nc/3.0>) which permits unrestricted non-commercial use, distribution, and reproduction in any medium, provided the original work is properly cited.

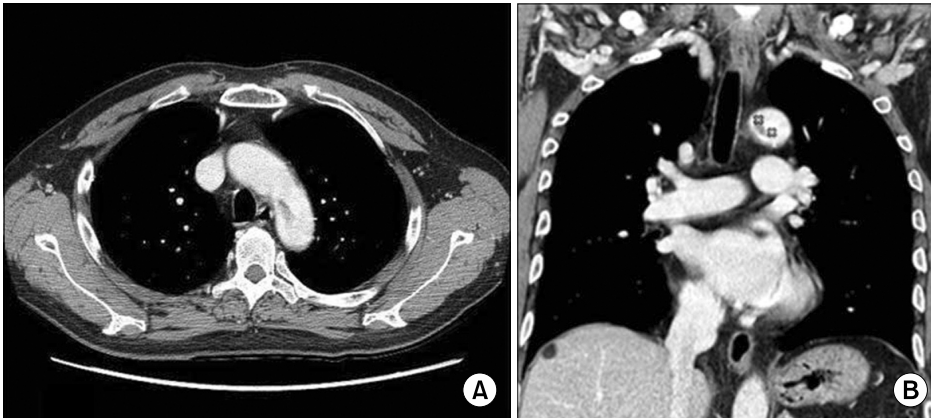


Fig. 2. A computed tomography scan ([A] transverse section, [B] coronal section) shows a mass lesion (3.0×1.5 cm) in the aortic arch. The aortic arch and the descending aorta are normal.

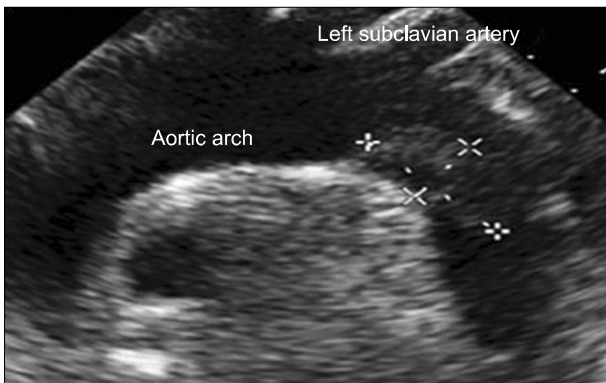


Fig. 3. An echocardiography shows a floating lesion (3.0×1.5 cm) in the aortic arch.

peripheral embolization, including thrombectomy for the brachial and radial artery occlusion of the left arm. We inserted arterial cannulation in the left femoral artery. A median sternotomy was performed, a venous cannula was inserted in the RA auricle, extracorporeal circulation was begun, and the central temperature was decreased to 25°C. The patient was then in total circulatory arrest. An incision was made in the aortic arch, and the 3.0-cm intraaortic mass was completely removed (Fig. 4). The mass had no definite stalk, and its attachment site in the aorta was relatively normal. A histopathologic examination revealed the mass to be a fibrin thrombus. We also removed the thrombus of the left upper extremities through the brachial artery. In the postoperative peripheral angiography, the brachial artery and the radial artery showed good blood flow (Fig. 1). One week later, the patient recovered without complications and was discharged

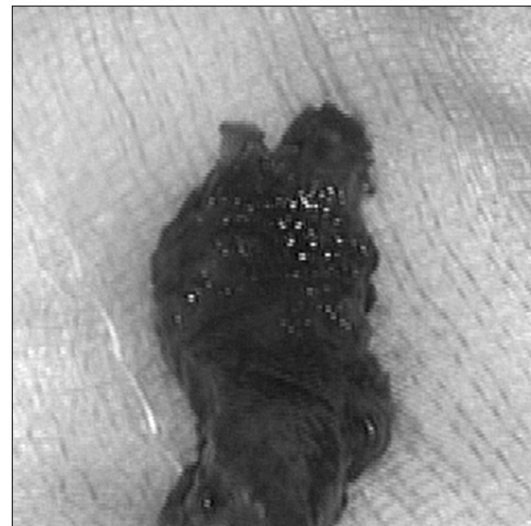

Fig. 4. A floating lesion in the aortic arch in the operating room. A fibrin thrombus was reported from the biopsy.

on the regimen of warfarin.

DISCUSSION

Most systemic embolisms are caused by thrombi in the left side of the heart. Aortic thrombi, however, are another important cause of arterial thromboembolism. Factors related to an arterial thrombus are arteriosclerosis, arterial dissection, trauma, malignant tumor, and hemostatic disorder [1]. In this case, the patient had protein C and S deficiency, which induced a hypercoagulable disorder.

The presence of pedunculated thrombi in the aortic arch as

in this case is rare. The incidence of embolic events from mobile aortic thrombi is 73% [2]. In this case, the patient had a thrombus in his left arm. We believe that it originated in the aortic arch. Sometimes, aortic thrombi could be asymptomatic, and their natural course is unknown [3]. The pathophysiology of aortic thrombi is not well defined. They occur more commonly in patients of advanced age and those with several cardiovascular risk factors. In our case, the patients had no risk factors except cigarette smoking. The most frequent location of thoracic aorta thrombi is the region of the aortic isthmus and the portion distal to the aortic arch, at the side opposite to the origin of the subclavian artery. Our patient had a thrombus in this region.

CT and echocardiography can be used for the diagnosis of aortic thrombi. In particular, transthoracic and transesophageal echocardiography have high diagnostic accuracy and allow the assessment of the size, morphology, and anchoring site of the thrombus, as well as the characteristics of the aortic wall [4]. Further, to determine the cause of the thrombus, we should consider a survey for hypercoagulable disorder. A definite diagnosis requires histological and immunohistochemical studies. In a differential diagnosis with other mass lesions, such as tumors, it is useful to consider magnetic resonance images.

The treatment of aortic thrombi is considered necessary because of the risk of a massive systemic embolization. The optimal treatment of aortic thrombi remains undefined. Thrombolysis can be a possible treatment, but there is a risk of

thrombolytic agents selectively lysing the stalk of the lesion, releasing the bulk of the lesion into the systemic blood stream [5]. We believe that in selective patients with acceptable surgery for cardiopulmonary bypass and definite systemic embolic events due to highly mobile aortic thrombi, surgical treatment has been successful. This case is reported in order to inform the readers of a rare case where floating thrombi in the aortic arch of patients with embolization were successfully treated surgically.

CONFLICT OF INTEREST

No potential conflict of interest relevant to this article was reported.

REFERENCES

1. Lee S, Cho JW, Kwon OC. *Floating thrombus in the ascending aorta of the patient with systemic sclerosis: a case report.* Korean J Thorac Cardiovasc Surg 2011;44:72-5.
2. Karalis DG, Chandrasekaran K, Victor MF, Ross JJ Jr, Mintz GS. *Recognition and embolic potential of intraaortic atherosclerotic debris.* J Am Coll Cardiol 1991;17:73-8.
3. Hassan I, Zehr KJ, Freeman WK. *A case of asymptomatic thoracic aorta mural thrombi.* Ann Thorac Surg 2001;72:1735-7.
4. Canadas V, Vilacosta I, Luaces M, et al. *Thrombosis of an apparently normal thoracic aorta and arterial embolism.* Rev Esp Cardiol 2008;61:196-200.
5. Choi JB, Choi SH, Kim NH, Jeong JW. *Floating thrombus in the proximal aortic arch.* Tex Heart Inst J 2004;31:432-4.