

# A Case of Pyogenic Liver Abscess Caused by *Staphylococcus epidermidis* in a Healthy Child

Ji Hye Gwak, M.D., Yeun Joo Eem, M.D., Ui Yoon Choi, M.D., and Jin Han Kang, M.D.

Department of Pediatrics, College of Medicine, The Catholic University of Korea, Seoul, Korea

*Staphylococcus epidermidis* is a normal inhabitant of skin, throat, mouth, vagina, and urethra. It is not usually pathogenic, particularly in immunocompetent hosts. This report describes a case of a pyogenic liver abscess caused by *Staphylococcus epidermidis* in a healthy 12-year-old boy. He was admitted to Seoul St. Mary's Hospital with intermittent fever for 6 days. Findings on abdominal computed tomography (CT) showed a mass measuring 7.0×6.5 cm in the right hepatic lobe. Culture of the abscess resulted in growth of *Staphylococcus epidermidis* as a causative organism. The patient was successfully treated with intravenous administration of antibiotics and percutaneous drainage of the abscess. (Korean J Pediatr Infect Dis 2013;20:36–40)

**Key Words :** Liver abscess, *Staphylococcus epidermidis*, Child

## Introduction

The incidence of pyogenic liver abscess in children varies according to geographical region. A few reports on pyogenic liver abscess have been published in Korea<sup>1, 2)</sup>. Predisposing conditions include a compromised immune system, congenital anomalies in the biliary tract, perforated appendicitis, trauma, and protein calorie malnutrition. Fever, abdominal pain with right upper quadrant tenderness, nausea, and jaundice are usual clinical manifestations. The most common pathogens include *Escherichia coli*, *Klebsiella pneumoniae*, *Staphylococcus aureus*, *Enterococcus*, *Bacteroides*, and *Entamoeba histolytica*, but rarely *Staphylococcus epidermidis*<sup>3–8)</sup>. Here we report on a healthy 12-year-old boy who presented

with fever and was diagnosed with a pyogenic liver abscess caused by *Staphylococcus epidermidis*.

## Case Report

A 12-year-old boy was admitted to Seoul St. Mary's Hospital with a high fever and abdominal discomfort for 6 days. He had no family history of inherited diseases or immunological disorders. Although he had been healthy, 10 days previously, he had suffered a right ankle sprain during a soccer game at school and had undergone acupuncture therapy on the right ankle once. On admission, he had a fever (39.5°C), pulse rate of 80 beats/min, blood pressure of 110/60 mmHg, and respiration 20 breaths/min. Findings on physical examination showed right upper quadrant tenderness, but no rebound tenderness, jaundice, or hepatomegaly. Laboratory studies showed the following results: white blood cell 24,000/mm<sup>3</sup> (neutrophil 74.8%, lymphocyte 5.2%, monocyte 19.91%), hemoglobin 13.1 g/dL, aspartate aminotransferase 124 IU/L, alanine aminotransferase 182

Received : 9 September 2012, Revised : 17 October 2012

Accepted : 18 October 2012

Correspondence : Jin Han Kang, M.D.

Department of Pediatrics, College of Medicine, The Catholic University of Korea

Tel : +82-2-2258-6183, Fax : +82-2-537-4544

E-mail : kjhan@catholic.ac.kr

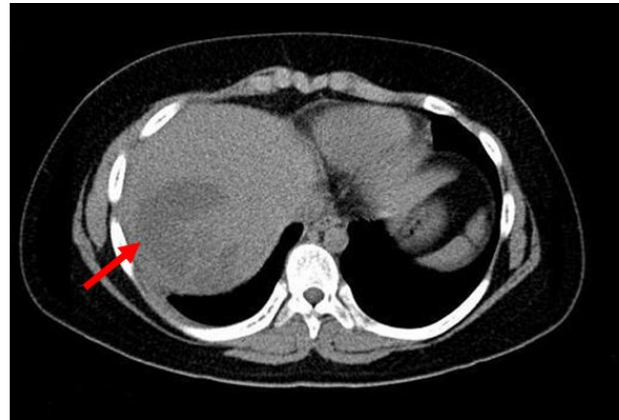
IU/L, albumin 3.7 g/dL, total bilirubin 0.79 mg/dL, gamma-glutamyl transpeptidase 139 IU/L, and C-reactive protein 34 mg/dL. The culture of blood was negative, and the chest radiograph was unremarkable.

Due to right upper quadrant tenderness and elevation of liver enzymes, abdominal computed tomography (CT) was performed. Findings on abdominal CT showed a pyogenic liver abscess measuring 7.0×6.5 cm in the right hepatic lobe with central low density (Fig. 1). The patient was given intravenous cefotaxime and metronidazole empirically. Percutaneous drainage with replacement of the catheter was performed; 80 mL of pus was drained. The result of the serum antiamebic antibody test performed for differentiation with amoebic liver abscess was negative.

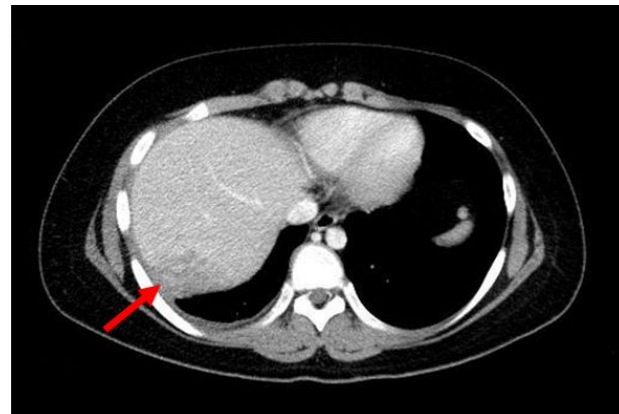
On the 7th hospital day, the patient still had fever up to 38.5°C once a day. Results from culture of pus indicated the presence of *Staphylococcus epidermidis*, which was susceptible to teicoplanin, vancomycin, linezolid, and trimethoprim/sulfamethoxazole, however, it was resistant to erythromycin, oxacillin, ampicillin, and amoxicillin/clavulanic acid. Treatment with cefotaxime and metronidazole was stopped and teicoplanin and meropenem were started on the 7th hospital day. The fever was resolved from the 9th hospital day.

Findings on follow-up abdominal CT, which was performed on the 14th hospital day, indicated that the pyogenic liver abscess had decreased in size to 6.0×4.5 cm. Drainage had ceased; therefore, the percutaneous catheter was removed. The patient continued antibiotic treatment. Findings on a subsequent follow-up abdominal CT performed on hospital day 26 indicated that the pyogenic liver abscess had decreased in size to 4.3×3.0 cm (Fig.

2). Laboratory studies on the same day showed improvement, as follows: white blood cell 4,030/mm<sup>3</sup> (neutrophil 43%), aspartate aminotransferase 20 IU/L, alanine aminotransferase 31 IU/L, gamma-glutamyl transpeptidase 98 IU/L, and C-reactive protein 1.73 mg/dL. On hospital day 40, the patient was discharged. Approximately 2 months after discharge, findings on abdominal CT performed in the outpatient department showed that the abscess was completely resolved.



**Fig. 1.** Abdominal CT showed a pyogenic liver abscess measuring 7.0×6.5 cm in the right hepatic lobe with central low density.



**Fig. 2.** On hospital day 26, findings on a follow up CT showed a decrease in the size of the liver abscess.

## Discussion

Pyogenic liver abscess is rare in children living in developed countries, but relatively common in developing countries, especially in tropical climates<sup>9, 10</sup>. The incidence varies from 25 per 100,000 admissions in the USA<sup>6</sup>, and 11 per 100,000 admissions in Denmark<sup>7</sup>, to 1 per 140 admissions in Brazil<sup>8</sup>, and more than 79 per 100,000 admissions in India<sup>9</sup>. In Korea, reports on children with pyogenic liver abscess due to *Staphylococcus aureus*<sup>1</sup> and *Streptococcus*<sup>2</sup> have been published.

The common causative organisms include *Escherichia coli*, *Klebsiella pneumoniae*, *Staphylococcus aureus*, *Enterococcus*, *Bacteroides*, and *Entamoeba histolytica*, which invade to liver through various routes, including the biliary tract, portal vein, hepatic artery, direct extension from focus of infection, and penetrating trauma<sup>5</sup>. The pyogenic liver abscess is usually formed as a solitary mass in the right hepatic lobe<sup>3, 4, 8</sup>.

*Staphylococcus epidermidis* is an aerobic gram positive bacteria found as normal flora of human skin, throat, mouth, vagina, and urethra. Immune compromised patients, especially those with indwelling foreign devices, are at risk of developing infection<sup>14</sup>. In the present case, a healthy 12-year-old boy presented with a solitary liver abscess in the right hepatic lobe caused by *Staphylococcus epidermidis*. We cannot clarify the pathogenesis of the patient's infection. He had once undergone acupuncture therapy on his right ankle due to a sprain, however, no bacteremia, scar, or soft tissue infection was observed in his ankle; therefore, it is less likely the bacteria entered the liver through acupuncture

therapy.

Diagnosis of pyogenic liver abscess by history and physical examination is difficult. Only one of ten patients exhibits classic features, including fever, jaundice, and right upper quadrant tenderness. Non-specific symptoms, including fever, fatigue, abdominal pain, nausea, and weight loss, are common. Laboratory studies may indicate leukocytosis, as well as elevation of liver enzymes and bilirubin, however, these findings are not specific for pyogenic liver abscess. Radiologic studies, including ultrasonography and CT, are essential in diagnosis of liver abscess. They are useful in visual identification, anatomical localization, and sizing<sup>3-8, 15</sup>. In the present case, the boy was admitted to the hospital with a high fever and abdominal discomfort. Due to right upper quadrant tenderness on physical examinations, as well as leukocytosis and elevation of liver enzymes in laboratory studies, abdominal CT was performed, which played a key role in diagnosis and follow up for evaluation of the size of the pyogenic liver abscess during therapy.

The traditional treatment for a pyogenic liver abscess includes antibiotic administration and drainage of the abscess. Percutaneous drainage is the primary therapy; however, open surgical drainage is considered in cases of failure of percutaneous drainage, multiple abscesses, left lobe abscess, and rupture of abscess<sup>5, 16, 17</sup>. Treatment starts as soon as the pyogenic liver abscess is recognized. Selection of the initial empirical antibiotics should be based on the suspected organism. For organisms originating from biliary diseases, including *Enterococcus* and enteric gram negative bacilli, the recommended antibiotics are ampicillin+gentamicin+/-metronidazole. For organisms originating from diseases of the colon,

including *Bacteroides*, the recommended antibiotics are third generation cephalosporin+metronidazole<sup>3-5, 7, 15)</sup>. In the present case, the patient was given cefotaxime and metronidazole empirically and the antibiotics were changed to teicoplanin and meropenem on the 7th hospital day. Selection of teicoplanin was based on culture results, while meropenem was broad spectrum. The fever subsided two days after change of antibiotics. The size of the abscess was markedly decreased by treatment with appropriate parenteral antibiotics and percutaneous drainage. Open surgical drainage was not necessary.

Occurrence of pyogenic liver abscess in a child is rare in Korea. The healthy boy described in this report presented with a solitary pyogenic liver abscess in the right hepatic lobe. *Staphylococcus epidermidis* was isolated as a causative organism. He was successfully treated with intravenous administration of antibiotics and percutaneous drainage of the abscess.

## 한 글 요약

### 건강한 소아에서 발생한 *Staphylococcus epidermidis*에 의한 화농성 간농양 1례

가톨릭대학교 의과대학 소아과학교실

곽지혜 · 임연주 · 최익윤 · 강진한

간농양은 선진국과 개발도상국에서 발생빈도에 차이가 있는 질환으로 국내에서는 드물다. 면역결핍, 간, 담도계 기형, 천공성 충수염, 외상, 단백질 결핍 등의 선행요인이 있을 때 발생하기 쉬우며 *Escherichia coli*, *Klebsiella pneumoniae*, *Staphylococcus aureus*, *Enterococcus*, *Bacteroides*와 *Entamoeba histolytica* 등에 의해 유발된다. 저자들은 발열을 주소로 내원한 건강한 12세 남아

에서 컴퓨터 단층촬영을 시행하여 간농양을 발견하였으며 경피배액술 흡인물 배양 검사에서 *Staphylococcus epidermidis*가 검출되어 항생제를 투여하여 합병증 없이 치료하였기에 보고한다.

## References

- 1) Lee SB, Hwang KS, Cho KS, Moon DS. A case of pyogenic abscess with fever of unknown origin. J Korean Pediatr Soc 1983;26:1145-8.
- 2) Byun JL, Bae SH, Park SW. A case of liver abscess in a 10-year-old girl. Korean J Pediatr 2010;53:666-8.
- 3) Mishra K, Basu S, Roychoudhury S, Kumar P. Liver abscess in children: an overview. World J Pediatr 2010;6:210-6.
- 4) Sharma MP, Kumar A. Liver abscess in children. Indian J Pediatr 2006;73:813-7.
- 5) Johannsen EC, Sifri CD, Madoff LC. Pyogenic liver abscesses. Infect Dis Clin North Am 2000;14:547-63.
- 6) Salahi R, Dehghani SM, Salahi H, Bahador A, Abbasy HR, Salahi F. Liver abscess in children: a 10-year single centre experience. Saudi J Gastroenterol 2011;17:199-202.
- 7) Hansen PS, Schonheyder HC. Pyogenic hepatic abscess. A 10-year population-based retrospective study. APMIS 1998;106:396-402.
- 8) Kliegman RM. Liver abscess. In: Kliegman RM, Stanton BF, Schor NF, Behrman RE, St. Geme III JW, editors. Nelson textbook of pediatrics. 19th ed. Philadelphia: Elsevier Saunders, 2011:1404-5.
- 9) Muorah M, Hinds R, Verma A, Yu D, Samyn M, Mieli-Vergani G, et al. Liver abscesses in children: a single center experience in the developed world. J Pediatr Gastroenterol Nutr 2006;42:201-6.
- 10) Hendricks MK, Moore SW, Millar AJ. Epidemiological aspects of liver abscess in children in the Western Cape Province of South Africa. J Trop Pediatr 1997;43:103-5.
- 11) Pineiro-Carrero VM, Andres JM. Morbidity and mortality in children with pyogenic liver abscess. Am J Dis Child 1989;143:1424-7.
- 12) Ferreira MA, Pereira FE, Musso C, Dettogni RV. Pyogenic liver abscess in children: some observations in the Espirito Santo State, Brazil. Arq Gastroenterol 1997;34:49-54.
- 13) Kumar A, Srinivasan S, Sharma AK. Pyogenic liver abscess in children-South Indian experiences. J Pediatr Surg

- 1998;33:417-21.
- 14) Todd JK. Coagulase-negative staphylococci. In: Kliegman RM, Stanton BF, Schor NF, Behrman RE, St. Geme III JW, editors. Nelson textbook of pediatrics. 19th ed. Philadelphia: Elsevier Saunders, 2011:909-10.
  - 15) Israeli R, Jule JE, Hom J. Pediatric pyogenic liver abscess. *Pediatr Emerg Care* 2009;25:107-8.
  - 16) Donovan AJ, Yellin AE, Ralls PW. Hepatic abscess. *World J Surg* 1991;15:162-9.
  - 17) Barakate MS, Stephen MS, Waugh RC, Gallagher PJ, Solomon MJ, Storey DW, et al. Pyogenic liver abscess: a review of 10 year's experience in management. *Aust N Z J Surg* 1999;69:205-9.