

RESEARCH ARTICLE

Pulmonary Lobectomy Combined with Pulmonary Arterioplasty by Complete Video-assisted Thoracic Surgery in Patients with Lung Cancer

Da-Ping Yu[&], Yi Han[&], Qiu-Yue Zhao, Zhi-Dong Liu*

Abstract

Objective: To explore the feasibility of pulmonary lobectomy combined with pulmonary arterioplasty by complete video-assisted thoracic surgery (VATS) in patients with lung cancer, and summarize its surgical methods. **Materials and Methods:** Twenty-one patients with lung cancer in Beijing Chest Hospital Affiliated to Capital Medical University from Feb., 2010 to Jun., 2013 were selected, males and females accounting for 15 and 6 cases, respectively. Ten underwent right upper lobectomy, 5 right lower lobectomy, 4 left upper lobectomy (in which left upper sleeve lobectomy was conducted for 2) and 2 left lower lobectomy. At the same time, local resection of pulmonary arterioplasty was performed for 12 patients, and sleeve resection of pulmonary arterioplasty for 9. **Results:** Twenty-one patients recovered well after surgery. Thoracic drainage tube was maintained for 3-8 days, with an average of 4.9 days, and hospital stays were 8-15 days, with an average of 11 days. There were no deaths in the perioperative period, and the complications like pulmonary embolism, bronchopleural fistula, chest infection and pulmonary atelectasis did not occur after surgery. **Conclusions:** Performance of pulmonary lobectomy and pulmonary arterioplasty together by complete VATS is a safe and effective surgical method, which can expand the indications of patients with lung cancer undergoing thoracoscopic pulmonary lobectomy, and make more patients profit from such minimally invasive treatment.

Keywords: Thoracoscopy - pulmonary arterioplasty - sleeve bronchoplasty - lung cancer

Asian Pac J Cancer Prev, 14 (10), 6061-6064

Introduction

At present, the video-assisted thoracoscopic technology has been widely applied in various operations of thoracic surgery (Yang et al., 2012; Han et al., 2013), and its clinical application in operation changes the therapeutic concept of lung cancer. With technologies developing, it has broken new ground in indications of some diseases (especially the lung cancer). Besides, its application in Phase I peripheral lung cancer has been extensively received nowadays (McKenna et al., 2006). For the invasion of non-small cell lung cancer (NSCLC) into the main pulmonary artery or vascular walls at the root of branches, routine methods cannot be used to deal with the branches of pulmonary artery. Because of normal proximal and distal blood vessels in the segment of pulmonary artery across the tumor, the partial resection and arterioplasty of the lateral pulmonary artery wall or partial resection and sleeve arterioplasty of pulmonary artery needs to be done, but the method of routine thoracotomy is usually adopted due to complex operation and high difficulty in operation. In the study, pulmonary lobectomy combined with pulmonary arterioplasty by completed video-assisted

thoracic surgery (VATS) was applied, which broadened the operation method in the treatment of lung cancer by the domestic VATS and made the surgical treatment of more tumors in the lung achieve the maximum mini-invasion.

Materials and Methods

General data

Twenty-one patients diagnosed as lung cancer in Beijing Chest Hospital from Feb., 2010 to Jun., 2013 were selected, in which the males and females were 15 and 6 cases, respectively. They were 46-72 years old, averagely (56.4±3.6) years old. Sixteen out of 21 patients were squamous carcinoma, and 5 were adenocarcinoma. In addition, 3 cases were complicated by chronic bronchitis, 3 by emphysema, 1 by hypertension and 1 by complete right bundle branch block of electrocardiogram.

Operation methods

Ten out of 21 patients was conducted right upper lobectomy, 5 right lower lobectomy, 4 left upper lobectomy (in which 2 was conducted left upper sleeve lobectomy) and 2 left lower lobectomy. Meanwhile, 12

Second Department of Thoracic Surgery, Beijing Chest Hospital, Capital Medical University, Beijing, China [&]Equal contributors
*For correspondence: lzdzrd@sina.com

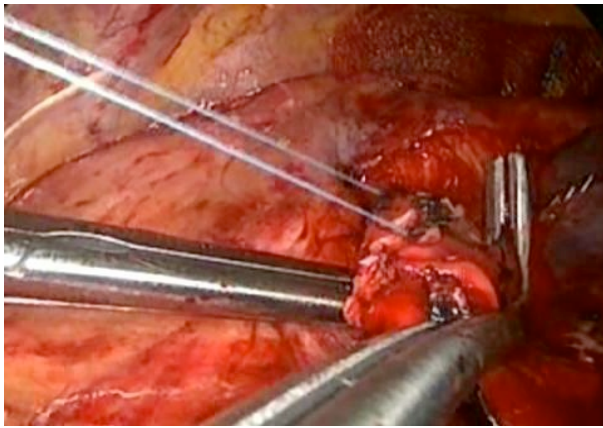


Figure 1. Pulmonary Arterioplasty During Operation

patients were performed local resection of pulmonary arterioplasty, and 9 performed sleeve resection of pulmonary arterioplasty. The venous compound general anesthesia, double-cavity tracheal intubation, one-lung ventilation and 90°lateral decubitus position were applied in operation. The thoracoscopic observation pole was between the 8th intercostal space approximately with the length of 1.5 cm in the posterior axillary line, and meanwhile, the 4th intercostal space about with the length of 2 cm (main operating pole) and 6th intercostal space approximately with 1.5 cm in the anterior axillary line and 8th intercostal space approximately with 1.5 cm (assistant operating pole) in the scapular angle line were respectively selected, and the smart cover of incision was placed in the main operating pole. During operation, the operator stood in the abdominal side of patients to operate. The first assistant first drew the affected lung to the dorsal side, then the operator cooperatively used the ultrasound knife and aspirator. The lower pulmonary ligament was first dissociated, then hilum of the lung was dissected. The pulmonary veins were separated by angioscopic cut staplers for free pulmonary veins. As for the patients with invasion of pulmonary arterial branches who were going to receive pulmonary lobectomy, the angioscopic cut staplers were applied to suture and cut along the initial part of pulmonary arterial branches after the main pulmonary artery was dissociated. This operation method was simpler. However, as for the patients with invasion of the main pulmonary artery, the thoracoscopic blocking clamp was respectively used to block their proximal and distal parts to make them excised after two ends of the affected pulmonary artery were completely dissociated, then the pulmonary artery was continuously sutured with 3-0 Prolene suture (double needles) (Figure 1). For 2 patients simultaneously conducted sleeve bronchoplasty, the absorbable suture was adopted to make the broken ends of left principal bronchus and left lower lobe bronchus anastomosis by continuous and intermittently reinforced suture after cancer cells at the broken end of bronchus transformed into negative (Figure 2). After anastomosis, mediastinal lymph node dissection was performed.

Results

Twenty-one patients completed the operation

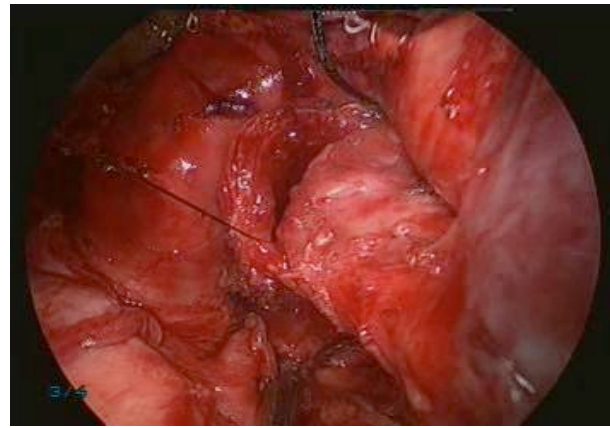


Figure 2. Sleeve Bronchoplasty During Operation

successfully. About 11-23 lymph nodes were dissected, 16.5 on average. The amount of bleeding during operation was 100-480 mL, 288 mL on average. Twenty-one patients recovered well after surgery. Thoracic drainage tube was maintained 3-8 days, averagely 4.9 days, and hospital stays were 8-15 days, averagely 11 days. There were no deaths in perioperative period, and the complications like pulmonary embolism, bronchopleural fistula, chest infection and pulmonary atelectasis didn't occur after surgery. One patient suffered from atrial fibrillation on day 2 after operation, and got better after oral administration of 200 mg propafenone three times a day.

Postoperative pathology: 16 out of 21 patients were squamous carcinoma, and 5 were adenocarcinoma. Postoperative staging: pT2aNOM0 9 and pT2aN1M0 12 were respectively 9 and 12 cases. There was no cancer residues at the broken end of bronchus. Fiberoptic bronchoscopy results demonstrated no anastomotic stoma stenosis, anastomotic stoma fistula and nub fistula, and there was no pulmonary thrombogenesis in preoperative period.

Discussion

As a mature technology, VATS has been an indispensable commonly-encountered diagnosis and treatment method in thoracic surgery at present. The pulmonary lobectomy by total thoracoscopy is still in research and exploration in the treatment of lung cancer. Pulmonary arterioplasty combined with pulmonary lobectomy can maximally maintain the postoperative lung function, improve the quality of life and prolong the survival time, and meanwhile, it can also make the patients with worse cardio-pulmonary function and unable to make an operation achieve an operation opportunity. The standard thoracotomy cannot be completely replaced by thoracoscopy, hence, thoracoscopic pulmonary arterioplasty combined with pulmonary lobectomy can make vascular surgical techniques applied in minimally invasive surgical category, which is a more recent exploratory research. Presently, there is only single case report at home and abroad (Nakanishi et al., 2008; Li et al., 2011).

In the study, there are two points which need to be attracted more attention regarding the pulmonary

arterioplasty combined with pulmonary lobectomy by VATS. One is operation experience and techniques, the other is operation indications (Chen et al., 2013). In general, the basic requirements for operation doctors are to have a good command of two operation methods, namely totally thoracoscopic pulmonary lobectomy and pulmonary arterioplasty in the open operation. If necessary, pulmonary arterioplasty combined with pulmonary lobectomy by thoracoscopy-assisted incision can be considered to perform first to accumulate experience, and then gradually to the operation of total thoracoscopy. According to the experience accumulated by previous operations, it is known that upper lobe central-type lung cancer or metastatic lymph nodes are susceptible to invade the pulmonary artery. The left superior lobar bronchus is surrounded by left pulmonary artery trunk and each branch artery in the left upper lobe, hence, the tumor in the superior lobe of left lung is easy to invade the pulmonary artery. Due to invasion of the tumor into pulmonary artery, the artery is easily damaged to result in massive hemorrhage, even threatening to life when separation. Under this circumstance, the tumor cannot be resected, or can only be given palliative resection, and sometimes the patient is forced to conduct the total pneumonectomy (Kent et al., 2013; Lu et al., 2013; Zhang et al., 2013). Hence, hilar lymph nodes adhere to pulmonary arteries tightly, or when the tumor invades the pulmonary artery, the proximal and distal ends of pulmonary artery should be dissected first, and then the blocking band or non-traumatic clamp is used to block respectively under no condition of blood. According to the condition of the tumor invading the pulmonary artery, wedge, partial or sleeve resection is conducted. When the tumor only invades the pulmonary arterial branch, the pulmonary artery should be fully free before the bronchus is cut off. The lateral-wall clamp is used to clamp the lateral wall of pulmonary artery, and the vascular closer to cut and suture at the root of invaded pulmonary arterial branch (Fan et al., 2013; Han et al., 2013). Local resection of the tumor and pulmonary artery is performed when the invaded pulmonary artery is less than its 1/3 perimeter. The normal tissue at both ends of pulmonary artery trunk is disassociated first, and then a non-traumatic clamp is used to block the proximal and distal parts of pulmonary artery to remove the affected lung, finally the pulmonary arterial defect is sutured with non-traumatic suture. If the invaded pulmonary artery is more than 1/3 perimeter, this pulmonary artery should be blocked, and meanwhile, the tumor and its invaded pulmonary artery are resected. The pulmonary artery is anastomosed at opposite ends with non-traumatic suture, and artificial angioplasty is given after resection when end-to-end anastomotic tension is large (Zhang et al., 2013).

In consideration of the conditions above, the authors in the study think that for NSCLC, routine method cannot be used to deal with pulmonary arterial branches whether the tumor or lymph node invades the pulmonary artery or vascular wall at the root of branches. When the proximal and distal blood vessels are normal in the segment of pulmonary artery across the tumor, thoracoscopic pulmonary arterioplasty can be applied according to

tumor operation principles, and meanwhile the operations like partial resection and arterioplasty of the lateral pulmonary arterial wall or partial resection and sleeve arterioplasty of the pulmonary artery. In the study, the pulmonary arteries in 17 out of 21 patients were directly invaded, and the lymph nodes around the pulmonary artery adhered to tightly in 4 patients. Pulmonary arterioplasty was given to guarantee that there was no tumor at the incisional edge. When the lung cancer invades the lobar bronchus or the bronchus in pulmonary artery trunk, sleeve resection and arterioplasty of the pulmonary artery can maximally preserve the healthy lung tissue at the same of guaranteeing the radical resection of lung tumor. In the study, 2 patients were simultaneously given sleeve arterioplasty of pulmonary artery and bronchus under total thoracoscope to make the tumor resection within maximum range at the time of maximally preserving the healthy lung and peripheral tissue, conducive to the patients with lung cancer to receive the comprehensive treatment further. This kind of operation has a certain advantages in the treatment of central lung cancer.

Anastomotic methods of pulmonary arteries and bronchus: Compared with routine thoracotomy, the management of thoracoscopic pulmonary artery is changed from initial three-dimensional vision to local two-dimensional vision, from multi-dimension operation to single-dimension operation (Wang et al., 2013). As the difficulty of operation becomes larger, the cognition on the overall development of pulmonary artery should be more distinct. In terms of pulmonary artery, 3-0 Prolene suture is conventionally adopted to make continuous suture. Their incisional edge to tumor edge was 0.5-1.0 cm when the pulmonary arteries of 21 patients were resected. There were no vascular distortion, anastomotic stoma tension and thrombogenesis. At the time of anastomosis, it should be noted to empty the vascular air and pour into 0.1% heparin saline to avoid the occurrence of embolism. At the time of suture, it should be avoided distortion to affect blood supply. It is reported that the pulmonary circulation is blocked 30 min under no conditions of pulmonary ventilation and anti-coagulation, there is no pulmonary thrombogenesis (Shao et al., 2007). After pulmonary arterioplasty, 5 000 IU of low-molecular-weight heparins calcium can be subcutaneously injected every day, totally 7 days, to prevent the occurrence of blood clot blockage at anastomotic stoma.

Bronchial anastomotic methods: Sleeve bronchoplasty by total thoracoscope is still short of mature experience. The first thoracoscope-assisted small incision sleeve bronchoplasty was reported by Santambrogio in 2002. At present, the method of thoracoscopic sleeve bronchoplasty completed by some scholars at home and broad can be intermittently sutured by the main operation pole with absorbable suture (McKenna et al., 2006; Liu et al., 2011). Although the anastomosis of this method is relatively reliable, but the operation is hard, and anastomosis is time-consuming due to the smaller thoracoscopic operation pole and limited space. Liu, et al applied 3-0 Prolene suture to make the continuous suture, added a small pole and assisted to receive the needle with thoracoscopic separating forceps, consequently reduced the intertwined

condition of suture at the time of intermittent suture and saved the operation time. The authors in the study adopted continuous intermittently-reinforced suture method, namely intermittent suture was applied for each 120 degree in the complete cycle of 360 degree, and then continuous suture was used between each intermittent suture. The authors thought that application of absorbable suture in the suture can decrease postoperative sputum retention and foreign-body stimulation at anastomotic stoma (Kang et al., 2013).

With the application of thoracoscopic pulmonary lobectomy in the treatment of lung cancer, the early minimally invasive treatment for lung cancer has achieved dramatic progress, and more and more complicated techniques has become to be applied in thoracoscopic pulmonary lobectomy. The results in this study preliminarily reveal that pulmonary lobectomy combined with pulmonary arterioplasty by VATS is a safe and effective operation method, which can expand the indications of patients with lung cancer conducted thoracoscopic pulmonary lobectomy, and make more patients get profits from its minimally invasive treatment. With further development of techniques and increase of clinical application, the application of combining thoracoscopic sleeve bronchoplasty makes the patients with central lung cancer obtain an opportunity of minimally invasive operation (Han et al., 2013).

Acknowledgements

The authors thank the hospital motto of Great Virtues, Dedication, Sincerity and Benefiting Mankind from Beijing Chest Hospital of Capital Medical University, which brings them the initial motivation to study and work industriously, and also thank the leaders and doctors in the Sixth Inpatient Area of Thoracic Surgery who provide a strong support in the new project of thoracoscopic pulmonary arterioplasty, help us query for data, solve the difficult problems and propose a lot of pertinent revision suggestions.

At the time of the paper to be published, we express our deep gratitude for our leaders and colleges. Thanks!

References

- Chen QK, Chen C, Chen XF, et al (2013). Video-assisted thoracic surgery for pulmonary aspergilloma: a safe and effective procedure. *Ann Thorac Surg*, Epub ahead of print.
- Fan J, Chang Z, Ye C, et al (2013). Video-assisted thoracoscopic superior segmentectomy of the right lower lobe. *J Thorac Dis*, **5**, S287-8.
- Han Y, Xiao N, Liu ZD (2013). Video-assisted thoracic surgery lobectomy on benign pulmonary diseases. *Chin J Med*, **48**, 55-7.
- Han Y, Zhou S, Yu D, et al (2013). Video-assisted thoracic surgery (VATS) left upper sleeve lobectomy with partial pulmonary artery resection. *J Thorac Dis*, **5**, S301-3.
- Han Y, Zhou S, Yu D, et al (2013). Video-assisted left upper bronchial sleeve lobectomy. *J Thorac Dis*, **5**, S304-6.
- Kang do K, Min HK, Jun HJ, et al (2013). Single-port video-assisted thoracic surgery for lung cancer. *Korean J Thorac Cardiovasc Surg*, **46**, 299-301.
- Kent M, Wang T, Whyte R, et al (2013). Open, video-assisted thoracic surgery, and robotic lobectomy: review of a national database. *Ann Thorac Surg*, Epub ahead of print.
- Lu H, Zhang Z, Li W, et al (2013). Video-assisted thoracic surgery right sleeve lobectomy. *J Thorac Dis*, **5**, S323-4.
- Li CY, Wang Y, Gao YS, et al (2011). The effect and conversive thoracoscopic indications of Video-assisted thoracic surgery lobectomy on elderly patients with non-small cell lung cancer. *Chin J Gerontol*, **31**, 947-9.
- Liu HC, Zhu YM (2011). Video-assisted right upper bronchial sleeve lobectomy: a report of 2 cases. *Chin J Thorac Cardiovasc Surg*, **27**, 618.
- Liu LX, Mei JD, Pu Q, et al (2011). Preliminary study of bronchial sleeve lobectomy by video-assisted thoracic surgery with removal of pulmonary cancer. *Chin J Thorac Cardiovasc Surg*, **18**, 387-9.
- McKenna RJ Jr, Houck W, Fuller CB (2006). Video-assisted thoracic surgery lobectomy: experience with 1, 100 cases. *Ann Thorac Surg*, **81**, 421-5.
- Nakanishi R, Yamashita T, Oka S (2008). Initial experience of video-assisted thoracic surgery lobectomy with partial removal of the pulmonary artery. *Interact Cardiovasc Thorac Surg*, **7**, 996-1000.
- Shao WL, Liu LX, He JH, et al (2007). Bronchial sleeve resection and reconstruction of pulmonary artery by video-assisted thoracic small incision for central lung cancer: a report of 139 cases. *Chi J Surg*, **45**, 1530-2.
- Wang W, Xu Z, Xiong X, et al (2013). Video-assisted thoracoscopic lobectomy for non-small cell lung cancer in patients with severe chronic obstructive pulmonary disease. *J Thorac Dis*, **5**, S253-9.
- Yang F, Li X, Ren BH, et al (2010). Video-assisted thoracoscopic lobectomy: series of consecutive 600 patients in multi-center. *Chin J Thorac Cardiovasc Surg*, **26**, 307-9.
- Zhang GJ, Zhang Y, Wen XP, et al (2013). Video-assisted thoracic surgery right upper lobectomy and lymph node dissection. *J Thorac Dis*, **5**, S328-30.
- Zhang X, Peng GL, Liang LX, et al (2013). Right, middle, and lower bronchial sleeve lobectomy by video-assisted thoracic surgery. *J Thorac Dis*, **5**, S277-9.