

RESEARCH ARTICLE

Clinical Outcomes of Cases with Absent Cervical Dysplasia in Cold Knife Conization Specimens

Eralp Baser^{1*}, Emre Ozgu¹, Selcuk Erkilinc², Hakan Yalcin¹, Nilufer Cetinkaya¹, Levent Sirvan³, Salim Erkaya², Tayfun Gungor¹

Abstract

Background: Cold knife conization is a surgical procedure that allows both diagnosis and treatment of cervical lesions at the same time. It is mainly performed for indications of high-grade cervical intraepithelial neoplasia (CIN). In this study, we aimed to investigate the clinical outcome of cases without CIN in cold knife conization specimen, following a high-grade lesion (CIN2/3) in cervical biopsy. **Materials and Methods:** We performed a retrospective cohort study at a tertiary referral hospital between January 1st 2008 and August 1st 2012. Cases that underwent cold knife conization for CIN2/3 within the study period were included. Cone-negative (Group 1) and cone-positive (Group 2) cases were analyzed for various clinical parameters, and were compared in the 1-year post-conization period for histological recurrence and human papillomavirus (HPV) DNA status. **Results:** A total of 173 women underwent cold knife conization for CIN2/3 within the study period. Twenty-two cases (12.7%) were included in Group 1 and 151 cases (87.3%) in Group 2. There were no significant differences between the two groups in terms of age, gravidity, parity, menopausal status and HPV-DNA status (pre-conization and 1 year post-conization) ($p>0.05$). Recurrence rates were also similar between the groups (9.1% vs 9.9%, $p>0.05$). **Conclusions:** Clinical outcomes were similar in terms of histological recurrence and HPV persistence after 1 year of follow-up between cone-negative and cone-positive cases. Clinical follow-up of cone-negative cases should therefore be performed similar to cone-positive cases.

Keywords: Cold knife conization - human papillomavirus - cervical intraepithelial neoplasia

Asian Pac J Cancer Prev, 14 (11), 6693-6696

Introduction

Cold knife conization is a surgical procedure that provides both diagnosis and treatment of cervical lesions at the same session. It is mainly performed for an indication of high-grade cervical intraepithelial neoplasia (CIN) (i.e. CIN2/3) or in case of suspicion for an occult endocervical lesion. It is also used to diagnose an occult invasive cancer at a very early stage (Apgar et al., 2013). Although today it is largely replaced by loop electrosurgical excision procedure (LEEP), cold knife conization is still considered by many gynecologists as a gold standard for treating premalignant conditions of the cervix.

Some women who undergo conization for CIN2/3 show no dysplastic lesions in the surgical cone specimen (Koc et al., 2013). This situation not only raises concern for a possible misdiagnosis, but also creates uncertainty for the appropriate steps to take during follow-up. In this study, clinical outcome of women undergoing conization for CIN2/3 that subsequently receive a negative pathological result for cervical dysplasia were investigated at a tertiary referral center.

Materials and Methods

This retrospective cohort study was performed at a tertiary referral hospital in Ankara, Turkey after obtaining approval from the institutional review board. Gynecologic oncology department surgical database was retrospectively reviewed between January 1st 2008 and August 1st 2012 for CIN2/3 cases that underwent cold knife conization. All of the conization procedures were performed by experienced gynecologic oncologists. Final pathological examination reports were obtained from the pathology department database. Group 1 consisted of cases in which no dysplastic changes had been reported in conization specimens (cone-negative), and Group 2 comprised cases that had received a diagnosis of CIN or invasive cancer (cone-positive). All cases were retrospectively evaluated for during their 1-year post-conization follow-up.

Study data included patient age, gravidity, parity, menopausal status, preoperative pap-smear result and preoperative high-risk Human papillomavirus (HPV) DNA status. For cases in Group 1, non-dysplastic conditions present in the specimen were also recorded.

¹Department of Gynecologic Oncology, ²Department of Obstetrics and Gynecology, ³Department of Pathology, Zekai Tahir Burak Women's Health Education and Research Hospital, Ankara, Turkey *For correspondence: eralpbaser@gmail.com

Using the outpatient database, 1-year follow-up for each case was evaluated, which included visits every 3 months. During each of these visits, a pelvic examination and a pap smear was performed. An HPV-DNA test was also performed at the 4th visit (1 year post-conization). Conventional Pap test was used for assessing cervical cytology. Polymerase chain reaction (PCR) method was used to identify high-risk HPV-DNA (Type-16, 18, 31, 33, 35, 39, 45, 51, 52, 56, 58, 59, 66, 68, and 82).

Statistical analyzes were performed using IBM SPSS 20.0 software (IBM, Armonk, NY, USA). Categorical variables were expressed as number and percentage, continuous numeric variables as mean±standard deviation (SD), and discrete variables as median and range. Taking into consideration the sample sizes in each group and data distribution, Student's t, Mann-Whitney U, Chi-square or Fisher's exact tests were performed to compare groups for the aforementioned variables. P values less than 0.05 were considered statistically significant.

Results

A total of 173 women underwent cold knife conization for CIN2/3 within the study period. Mean patient age was 38.8±9.6. Median gravidity and parity were 2. Regarding menopausal status, 147 cases (85%) were premenopausal, and 26 cases (15%) were postmenopausal.

According to pathological reports of the cone specimens, 22 cases (12.7%) were included in Group 1 and 151 cases (87.3%) in Group 2. Pathological diagnoses in Group 1 consisted of cervicitis (n: 11, 50%), metaplasia (n: 7, 31.8%) and HPV related cytological changes (n: 3, 13.6%). No pathological changes were reported in one case (4.5%). In Group 2, the final diagnoses were reported as CIN2/3 (n: 115, 76.2%), CIN1 (n: 30, 19.9%) and invasive cancer (n:6, %3.9). Appropriate surgical treatment was conducted by means of radical hysterectomy and pelvic/paraortic lymph node dissection in cases with a malignancy.

There were no significant differences between the two groups in terms of age, gravidity, parity, menopausal status and HPV-DNA status (pre-conization and 1 year post-conization) (p>0.05) (Table 1). Cytological results preceding CIN2/3 in according to groups are presented in Table 2. In total, high-risk HPV-DNA was preoperatively detected in 111 cases (64.2%). The rate of HPV-DNA positivity in Group 1 and Group 2 were (7/22, 68.2%) and (102/151, 67.5%) respectively. Most frequently detected high-risk HPV-DNA types are presented in Table 3.

One year follow-up data were analyzed for all study cases. A scheme of cytological results obtained during this period is presented in Figure 1. Considering both groups, there were a total of 17 histological recurrences. Recurrence rates in Group 1 and Group 2 were 9.1% (2/22) and 9.9% (15/151), respectively (p>0.05). In Group 1 follow-up, one case was diagnosed with CIN1 and case with HSIL was consequently diagnosed with CIN2. In Group 2 follow-up, 12 cases were diagnosed with CIN1, 2 cases with CIN2 and 1 case with CIN3. A total of 35 cases (20.2%) required hysterectomy within one year after conization. Hysterectomy rates were 3/22 (13.6%)

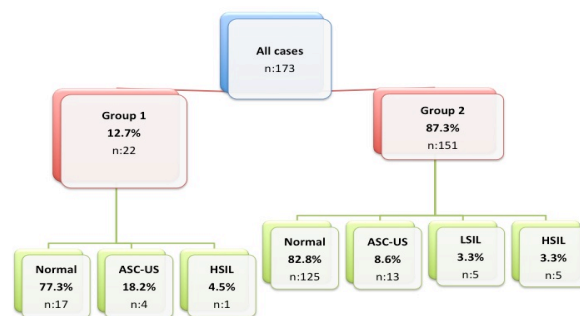


Figure 1. Cytological Results of the Study Groups during Follow-up

Table 1. Comparison of Demographic and Clinical Data between Study Groups

Parameter	Group 1	Group 2	p
Age	39.4±10.8	38.7±9.4	0.74
mean±SD* (range)	(23-59)	(20-71)	
Gravidity Median (range)	2 (0-7)	3 (0-6)	0.47
Parity Median (range)	2 (0-5)	2 (0-5)	0.43
Postmenopause rate (%)	6/22 (27.3)	20/151 (13.2)	0.08
Pre-conization HPV** DNA positivity (rate, %)	15/22 (68.2)	102/151 (67.5)	0.95
Post-conization (1 year) HPV** DNA positivity (rate, %)	5/22 (22.7)	15/151 (9.9)	0.14

*SD: standard deviation, **HPV: Human papillomavirus

Table 2. Cytological Results Preceding Colposcopy Directed Biopsies

Cytology	Group 1 n (%*)	Group 2 n (%*)	Total n (%*)
HSIL ^a	15 (68.2)	116 (76.8)	131 (75.7)
ASC-US ^b	6 (27.3)	25 (16.6)	31 (17.9)
LSIL ^c	1 (4.5)	8 (5.3)	9 (5.2)
ASC-H ^d	0 (0)	1 (0.7)	1 (0.6)
AGC-NOS ^e	0 (0)	1 (0.7)	1 (0.6)
Total	22	151	173 (100)

*Column percentage; ^aHSIL: High-grade squamous intraepithelial lesion; ^bASC-US: Atypical squamous cells of undetermined significance; ^cLSIL: Low-grade squamous intraepithelial lesion; ^dASC-H: Atypical squamous cells- not exclude HSIL; ^eAGC-NOS: Atypical glandular cells-not otherwise specified

Table 3. Most Frequently Detected Human Papillomavirus (HPV) DNA Types

Type	Group 1 n (%*)	Group 2 n (%*)	Total n (%*)
HPV-16	9 (40.9)	54 (35.8)	63 (36.4)
HPV-18	1 (4.5)	13 (8.6)	14 (8.1)
HPV-31	1 (4.5)	9 (6.0)	10 (5.8)
HPV-33	2 (9.1)	3 (2.0)	5 (2.9)
HPV-45	-	4 (2.6)	4 (2.3)
HPV-51	-	4 (2.6)	4 (2.3)
HPV-52	2 (9.1)	-	4 (2.3)
Not Detected	7 (31.8)	55 (36.4)	62 (35.8)

*Column percentage

in Group 1 and 32/151 (21.2%) in Group 2, and did not differ statistically (p>0.05).

Discussion

Uterine cervical cancer is a malignancy that most frequently effects underdeveloped and developing countries with poor resources for providing adequate

screening opportunities for their citizens (Jemal et al., 2011). Unlike many other organ sites with premalignant conditions, it takes a significant time for a premalignant lesion of the cervix to progress into invasive cancer (Vink et al., 2013). Histological diagnoses of CIN 2 and CIN 3 are generally considered to have increased risk for progression to cancer (Montz, 2000). For this reason, especially in women with no fertility concerns, gynecologists generally prefer to excise the transformation zone either by cold knife conization or LEEP (Jancar et al., 2006). Failure to find a dysplastic lesion in the cone specimen may infrequently occur. We aimed to outline the clinical outcome of such cases in this study.

After analyzing final pathological reports of the surgical specimens, we found that 22 of 173 cases (12.7%) that underwent conization for CIN2/3 was reported as not having any cervical dysplasia (cone-negative). This rate is in compliance with the previously published papers, in which approximately 8-25% of cases that had conization for abnormal cytology or histology were consequently reported as cone-negative (Golbang et al., 1997; Diakomanolis et al., 2003; Murta et al., 2006; Koc et al., 2013). In a study by Koc et al. (2013), among 202 conizations, the authors reanalyzed 25 cone specimens that were previously reported as negative (Koc et al., 2013). They reevaluated preceding punch biopsies that were reported as low-grade and high-grade CIN. After reexamination of the specimens, the authors confirmed that all conization slides were negative for a dysplastic lesion. However, upon reexamining the punch biopsy materials, they found that there were 13 false positive diagnoses in cases reported both as low-grade (n: 9) and high-grade (n: 4) CIN. This study showed that a negative cone biopsy could be a result of a false-positive punch biopsy.

In previous reports, it was reported that conditions such as cervicitis, tubal metaplasia, atrophy, immature squamous metaplasia, and basal cell hyperplasia were most frequently associated with a false-positive punch biopsy report that could eventually lead to negative findings on the cone specimen (Golbang et al., 1997; Weigl et al., 2006). In our study, most common non-dysplastic diagnoses in cone specimens were also cervicitis (n: 11, 50%), metaplasia (n: 7, 31.8%) and HPV related changes (n: 3, 13.6%). In some cases, these non-dysplastic lesions might be misdiagnosed as CIN. However, diagnostic accuracy is generally high in CIN2/3, and false-positive results are much less frequent when compared to CIN1 (Koc et al., 2013). In another study by Weigl et al. (2006), 208 consecutive cone specimens were retrospectively evaluated, and 22 cases (10.6%) with benign cervical lesions following a diagnosis of CIN in punch biopsy were identified (Weigl et al., 2006). The lesions and their frequencies were reported to be very similar to our study findings: cervicitis in 12 (54%), metaplasia in 4 (18.1%), and HPV infection in 1 (4.5%) and combined lesions in 5 cases (22.7%). Weigl et al. also emphasized that another cause of negative conization findings could be long lasting HPV infections that might result in mild to moderate dysplasia (Weigl et al., 2006). This claim was repeated in a very recent study that investigated factors predicting absence of CIN in the cone specimens

(Rodriguez-Manfredi et al., 2013). The authors stated that cases with negative pre-conization HPV test or a low viral load had a high probability of having a negative cone result. In contrast with these reports, we found in our study that cone-negative cases (Group1) had similar high-risk HPV infection rates with cone-positive cases (Group 2).

With regards to outcome of these cases, a study by Murta et al. investigated the clinical significance of a negative conization (Murta et al., 2006). All patients in this study had undergone conization (cold knife or LEEP) or hysterectomy for a diagnosis of CIN. The frequency of negative conizations in their study was 15.5%. They reported that recurrences were observed less frequently and later cone-negative cases (7.1% vs 11.2%). In our study, we also analyzed 1-year follow-up of all cases, and histological recurrence rates were similar between cone-negative and cone-positive cases (9.1% vs 9.9%) ($p>0.05$). Therefore, we could not demonstrate an outcome advantage for cone-negative cases in our study.

A question still remains to be answered: Could we reduce the discordance rates between punch biopsies and conization specimens? As an answer, the authors of a previously published paper recommended that taking pap-smears after treating atrophy and inflammation, performance of colposcopy by an expert in a cautious manner, and finally reconfirming the results in case of a cytology-biopsy discordance could reduce the number of negative cone biopsies (Golbang et al., 1997).

In summary, our study suggested that outcomes were similar in terms of histological recurrence and HPV persistence after 1 year of follow-up between cone-negative and cone-positive cases. Therefore, we recommend no additional interventions in cone-negative women. These cases should have follow-up visits similar to cone-positive cases. Treatment of any infectious or atrophic conditions prior to performing a cervical biopsy or conization procedure should be practiced in order to achieve accurate results.

References

- Apgar BS, Kaufman AJ, Bettcher C, Parker-Featherstone E (2013). Gynecologic procedures: colposcopy, treatments for cervical intraepithelial neoplasia and endometrial assessment. *Am Fam Physician*, **87**, 836-43.
- Diakomanolis E, Haidopoulos D, Chatzipapas I, et al (2003). Negative cone biopsies. A reappraisal. *J Reprod Med*, **48**, 617-21.
- Golbang P, Scurry J, De Jong S, et al (1997). Investigation of 100 consecutive negative cone biopsies. *Br J Obstet Gynaecol*, **104**, 100-4.
- Jancar N, Rakar S, Poljak M, et al (2006). Efficiency of three surgical procedures in eliminating high-risk human papillomavirus infection in women with precancerous cervical lesions. *Eur J Gynaecol Oncol*, **27**, 239-42.
- Jemal A, Bray F, Center MM, et al (2011). Global cancer statistics. *CA Cancer J Clin*, **61**, 69-90.
- Koc N, Sahin D, Ayas S (2013). Reevaluation of negative cone biopsy results after a positive cervical biopsy finding. *J Low Genit Tract Dis*, **17**, 154-9.
- Montz FJ (2000). Management of high-grade cervical intraepithelial neoplasia and low-grade squamous intraepithelial lesion and potential complications. *Clin*

Eralp Baser et al

Obstet Gynecol, **43**, 394-409.

Murta EF, Silva AO, Silva EA (2006). Clinical significance of a negative loop electrosurgical excision procedure, conization and hysterectomy for cervical intraepithelial neoplasia. *Eur J Gynaecol Oncol*, **27**, 50-2.

Rodriguez-Manfredi A, Alonso I, Del Pino M, et al (2013). Predictors of absence of cervical intraepithelial neoplasia in the conization specimen. *Gynecol Oncol*, **128**, 271-6.

Vink MA, Bogaards JA, Van Kemenade FJ, et al (2013). Clinical progression of high-grade cervical intraepithelial neoplasia: estimating the time to preclinical cervical cancer from doubly censored national registry data. *Am J Epidemiol*, [Epub ahead of print].

Weigl G, Pokieser W, Schuller B, et al (2006). Investigation of 208 consecutive cases of cervical cone biopsies with regard to indication, negative samples and quality control. *Acta Cytol*, **50**, 185-90.