

## Effect of simultaneous therapy of arthrocentesis and occlusal splints on temporomandibular disorders: anterior disc displacement without reduction

Hye-Sung Lee<sup>1</sup>, Hyun-Su Baek<sup>1</sup>, Dong-Suk Song<sup>1</sup>, Hee-Chul Kim<sup>1</sup>, Hyo-Geun Kim<sup>1</sup>, Bok-Joo Kim<sup>1</sup>,  
Myung-Soo Kim<sup>2</sup>, Sang-Hoon Shin<sup>3</sup>, Sung-Hee Jung<sup>4</sup>, Chul-Hoon Kim<sup>1</sup>

<sup>1</sup>Department of Oral and Maxillofacial Surgery, School of Medicine, Dong-A University,

<sup>2</sup>Department of Nursing, School of Natural Sciences, Pukyong National University, Busan,

<sup>3</sup>Department of Oral and Maxillofacial Surgery, School of Dentistry, Pusan National University,

<sup>4</sup>Department of Oro-facial Pain and Oral Medicine, School of Dentistry, Pusan National University, Yangsan, Korea

**Abstract** (J Korean Assoc Oral Maxillofac Surg 2013;39:14-20)

**Objectives:** This study sought to evaluate the effect of simultaneous application of arthrocentesis and occlusal splint.

**Materials and Methods:** A retrospective study of 43 patients (3 males, 40 females) whose symptoms had improved was conducted at the Department of Oral and Maxillofacial Surgery, Dong-A University Hospital between 2008 and 2010. Subjects were divided into three groups: Group A (17 patients with arthrocentesis and occlusal splints simultaneously applied), Group B (13 patients whose symptoms did not improve with occlusal splints, undergoing arthrocentesis after occlusal splint use for 8 weeks), and Group C (13 patients that only used occlusal splints). We compared these groups in maximum comfortable opening (MCO) and the visual analogue scale of pain and noise. Follow-up was performed at 1 week, 1 month, 3 months, and 6 months.

**Results:** The improvement of symptoms was noted in all three groups, but Group A had a quicker improvement than the other groups, in terms of pain reduction and MCO increases.

**Conclusion:** The simultaneous application of arthrocentesis and occlusal splints can reduce patient discomfort more quickly.

**Key words:** Temporomandibular joint disorders, Arthrocentesis, Occlusal splint

[paper submitted 2012. 6. 12 / revised 2012. 12. 21 / accepted 2013. 1. 7]

### I. Introduction

The primary goal in the treatment of temporomandibular joint disorder (TMD) is to ease pain or mandibular dysfunction<sup>1</sup>. TMD treatment can be divided into two categories: conservative method and surgical method. Conservative treatments include medication, habit modification, counseling, physical therapy, splint therapy, and manipulation<sup>2</sup>. Surgical treatments include arthrocentesis, arthroscope,

arthroplasty, discectomy, and temporomandibular joint (TMJ) reconstruction<sup>3</sup>. A conservative, reversible method is widely accepted to be the first choice for TMJ treatment<sup>4</sup>. As one of the conservative treatments, occlusal splint has been frequently used for internal derangement and myofascial pain treatment. As for the mechanisms of occlusal splint therapy, wearing an occlusal splint is considered to cause alterations in mechanical sensitive input arising from periodontal tissue and spindle afferents in the jaw closing muscle<sup>5</sup> and decrease in intra-articular pressure in TMJ<sup>6</sup>.

Occlusal splint is often successful, but the length of time required to reach a pain-free normal range of motion is sub-optimum<sup>7</sup>.

Among the surgical interventions, arthrocentesis is generally suggested for patients who are not responsive to conservative therapy<sup>8</sup>. Arthrocentesis is an easy, minimally invasive, highly efficient procedure designed to decrease joint pain and increase the range of mouth opening in patients with

#### **Chul-Hoon Kim**

Department of Oral and Maxillofacial Surgery, School of Medicine, Dong-A University, 26 Daesingongwon-ro, Seo-gu, Busan 602-715, Korea

TEL: +82-51-240-5475 FAX: +82-51-241-5475

E-mail: bbp2000@hanmail.net

© This is an open-access article distributed under the terms of the Creative Commons Attribution Non-Commercial License (<http://creativecommons.org/licenses/by-nc/3.0/>), which permits unrestricted non-commercial use, distribution, and reproduction in any medium, provided the original work is properly cited.

Copyright © 2013 The Korean Association of Oral and Maxillofacial Surgeons. All rights reserved.

closed lock of TMJ<sup>9</sup>. In fact, it has recently been proposed as a first-line treatment in disc displacement without reduction<sup>10</sup>.

To date, studies on occlusal splint only, arthrocentesis only, and combined treatment of occlusal splint and arthrocentesis have been conducted. Studies comparing those treatments are rare, however.

This study sought to test the hypothesis that the simultaneous use of occlusal splint and arthrocentesis is an effective method for anterior disc displacement without reduction. A retrospective comparative study was conducted to investigate the therapeutic effect of the simultaneous application of arthrocentesis and occlusal splint, arthrocentesis after occlusal splint use, and use of occlusal splint only.

## II. Materials and Methods

### 1. Patient collection and definitions

A retrospective study targeting 43 patients (3 males, 40 females) whose records were completely preserved and whose symptoms had improved was conducted at the Department of Oral and Maxillofacial Surgery, Dong-A University Hospital between 2008 and 2010. All patients were diagnosed with anterior disc displacement without reduction based on MRI. The inclusion and exclusion criteria are shown in Table 1.

The study was conducted after obtaining approval from the Institutional Review Board of Dong-A University Hospital (12-060).

### 2. Treatment groups

A total of 43 patients were divided into 3 groups: 17 in

group A, 13 in group B, and 13 in group C.

Group A: Patients who underwent the simultaneous application of arthrocentesis and occlusal splint.

Group B: Patients whose symptoms did not improve with the use of occlusal splint, so they underwent arthrocentesis after occlusal splint use for 8 weeks.

Group C: Patients who only used occlusal splint.

### 3. Outcome measures

Visual analog scale (VAS) (0-10) was used for pain and noise assessment. VAS is considered to be a reliable, effective method for evaluating TMJ pain<sup>11</sup>. Zero indicates no pain, whereas ten means severe pain. Maximum comfortable opening (MCO) was measured between the edges of the upper and lower central incisors by a millimeter ruler. The success criteria for surgery for TMJ internal derangement have been proposed by American Association of Oral and Maxillofacial Surgeons (AAOMS)<sup>12</sup>: absence of or mild pain, range of motion of more than 35 mm for vertical.

We evaluated the period of achieving normal states among the groups. Normal state is said to have been achieved if the following requirements are satisfied: (1) VAS score for pain was less than 3 (pain<3); (2) MCO was more than 38 mm or MCO increase was more than 10 mm (MCO $\geq$ 38 [or 10]); (3) Pain<3 and MCO $\geq$ 38 (or 10). For Group A, follow-up check was performed at 1 week, 1 month, 3 months, and 6 months after arthrocentesis. In groups B and C, however, follow-up check was performed at 1 week, 1 month, 3 months, and 6 months after occlusal splint installation.

### 4. Arthrocentesis and splint therapy

Impression taking for occlusal splint was performed on the day of diagnosis in group A. One week later, group A wore full-coverage, hard acrylic stabilizing splint on the maxilla, and arthrocentesis was performed on symptomatic TMJ. On the other hand, impression taking for occlusal splint was performed on the day of diagnosis in group B. One week later, group B wore full-coverage, hard acrylic stabilizing splint on the maxilla. The occlusal splint was used for a mean of 8 weeks prior to arthrocentesis. Finally, impression taking for occlusal splint was performed on the day of diagnosis in group C. For all the groups, appropriate doses of diazepam and non-steroidal anti-inflammatory drugs (NSAIDs) were administered for pain control for one week. If patients complained of pain during treatment, they were prescribed an

**Table 1.** Inclusion and exclusion criteria of the study

Inclusion criteria	
A. Clinical diagnosis of anterior disc displacement	
1. Limitation of mouth opening	
2. Pre-auricular pain, temporal and occipital tenderness, headache	
3. Persistence of symptoms at least for 3 months	
4. No symptoms for at least 1 year after treatment	
5. Disc-displaced state on one side, normal state on the other side	
B. Magnetic resonance imaging (MRI) diagnosis of anterior disc displacement without reduction	
Exclusion criteria	
A. Systemic disease	
B. Arthritis or history of condylar trauma	
C. Degenerative change of condylar head	
D. Facial asymmetry, retrognathism, prognathism	

Hye-Sung Lee et al: Effect of simultaneous therapy of arthrocentesis and occlusal splints on temporomandibular disorders: anterior disc displacement without reduction. *J Korean Assoc Oral Maxillofac Surg* 2013

additional medication for one week. Patients were instructed to wear their splint the whole day except mealtimes.

Arthrocentesis was performed on all patients in groups A and B using the technique described by Nitzan et al.<sup>13</sup> Two points were marked over the skin of the affected joint indicating the articular eminence and articular fossa. This was followed by the injection of a local anesthetic to block the auriculotemporal nerve<sup>14,15</sup>. A 23-gauge needle was inserted into the superior compartment at the articular fossa (posterior mark), followed by the injection of 2-3 mL of lactated Ringer's solution to distend the joint space. An 18-gauge needle was then inserted into the distended compartment in the area of articular eminence to enable free flow of the solution through the superior compartment. The lactated Ringer's solution was connected to one of the needles. Sufficient pressure was secured by placing the infusion bag at an elevation of 1 meter above the level of the joint. During the procedure, the patient repeated maximum mouth opening, protrusion, and lateral movement. Upon the termination of the procedure, 2 mL (20 mg) hyaluronic acid (Hyruan plus; LG Life Sciences, Seoul, Korea) was injected into the joint space followed by the removal of the needles. Postoperative medication consisted of antibiotics thrice daily for 3 days and NSAIDs thrice daily for 7 days.

### 5. Statistical analysis

Data were analyzed using the PASW ver. 18.0 for Win (IBM Co., Armonk, NY, USA). Descriptive analyses were used to

illustrate the characteristics of the participants. We assessed the assumption of sampling distribution such as normality before statistical analysis, but the hypothesis for normality was not met. Therefore, we conducted variables log transformation. In evaluating the statistical significance of pain, MCO, and noise changes within group, repeated measure of ANOVA and ANOVA test with Bonferroni's post hoc test were conducted. A *P*-value of  $\alpha < 0.05$  was considered to be statistically significant.

## III. Results

### 1. Demographic data

Patients numbered 43 (males: 3; females: 40). The mean

**Table 2.** Demographics and baseline data of participants (n=43)

	Group A (n=17)	Group B (n=13)	Group C (n=13)	F (P)
Age (years)	22.59	21.46	21.77	0.07 (0.968)
Sex-female	17 (100)	13 (100)	10 (76.9)	-
Initial pain	5.76±1.99	5.92±1.44	4.92±1.55	1.32 (0.279)
Initial MCO	1.35±2.54	1.84±2.85	3.00±2.01	1.64 (0.207)
Initial noise	33.06±7.90	31.38±6.21	29.92±3.38	0.92 (0.408)

(MCO: maximum comfortable opening)

F=ANOVA, Values are presented as n, n (%) or mean±standard deviation. Group A: simultaneous application of arthrocentesis and occlusal splint, Group B: arthrocentesis after occlusal splint use, Group C: occlusal splint use only.

*Hye-Sung Lee et al: Effect of simultaneous therapy of arthrocentesis and occlusal splints on temporomandibular disorders: anterior disc displacement without reduction. J Korean Assoc Oral Maxillofac Surg 2013*

**Table 3.** Comparison of pain, MCO, and noise between groups

Variable	Time	A	B	C
Pain (VAS)	Baseline	5.76±1.99	5.92±1.44	4.92±1.55
	1 week	3.41±1.77	4.31±2.43	3.08±1.26
	1 month	2.24±1.44	3.15±2.48	2.77±1.42
	3 months	1.88±1.41	2.77±1.74	2.69±1.18
	6 months	1.38±1.65	1.73±1.99	2.00±1.41
	MCO (mm)	Baseline	33.06±7.91	31.38±6.21
1 week		37.53±7.21	34.08±5.42	32.08±3.86
1 month		40.53±6.18	37.62±4.59	33.38±3.45
3 months		41.41±4.91	39.38±4.09	34.69±3.99
6 months		43.06±5.09	41.92±3.80	36.54±3.99
Noise (VAS)		Baseline	1.35±2.54	1.85±2.85
	1 week	1.00±1.77	1.54±2.18	1.62±1.61
	1 month	0.59±0.94	1.46±2.15	1.15±1.52
	3 months	0.38±0.70	1.15±1.99	1.54±1.66
	6 months	0.62±0.99	1.23±2.42	1.46±1.45
	Pain<3 (weeks)		7.65±7.69	16.54±17.83
MCO≥38 (weeks)		5.06±5.93	14.62±16.93	40.00±13.16
Pain<3 & MCO≥38 (or 10) (weeks)		8.65±7.26	24.69±19.51	42.00±12.49

(VAS: visual analog scale, MCO: maximum comfortable opening)

Values are presented as mean±standard deviation.

*Hye-Sung Lee et al: Effect of simultaneous therapy of arthrocentesis and occlusal splints on temporomandibular disorders: anterior disc displacement without reduction. J Korean Assoc Oral Maxillofac Surg 2013*

**Table 4.** Change patterns for pain, MCO, and noise between groups (n=43)

Variable	Time	A (n=17)	B (n=13)	C (n=13)	Time*Group F (P)
Pain	Baseline	4.13±0.51	4.22±0.23	4.05±0.28	1.48 (0.199)
	1 week	3.70±0.48	3.86±0.51	3.64±0.45	
	1 month	3.36±0.53	3.56±0.61	3.54±0.48	
	3 months	3.22±0.59	3.51±0.55	5.54±0.45	
	6 months	2.95±0.68	3.11±0.63	3.26±0.60	
MCO	Baseline	5.81±0.23	5.76±0.19	5.73±0.11	1.21 (0.314)
	1 week	5.94±0.19	5.85±0.16	5.80±0.11	
	1 month	6.02±0.15	5.95±0.12	5.83±0.10	
	3 months	6.04±0.11	6.00±0.10	5.87±0.10	
	6 months	6.08±0.11	6.06±0.09	5.92±0.10	
Noise	Baseline	2.77±0.81	2.95±0.89	3.53±0.65	1.69 (0.171)
	1 week	2.72±0.70	2.94±0.77	3.11±0.58	
	1 month	2.64±0.49	2.93±0.72	2.88±0.63	
	3 months	2.54±0.40	2.80±0.69	3.06±0.62	
	6 months	2.64±0.51	2.75±0.77	3.05±0.59	

(MCO: maximum comfortable opening)

F=repeated measure of ANOVA.

Values are presented as mean±standard deviation.

Hye-Sung Lee et al: Effect of simultaneous therapy of arthrocentesis and occlusal splints on temporomandibular disorders: anterior disc displacement without reduction. *J Korean Assoc Oral Maxillofac Surg* 2013

age in each was 22.59 (group A), 21.46 (group B), and 21.77 (group C) ( $F=0.07$ ,  $P=0.968$ ). There were no statistical differences among the three groups in terms of baseline pain ( $F=1.32$ ,  $P=0.279$ ), MCO ( $F=1.64$ ,  $P=0.207$ ), and noise ( $F=0.92$ ,  $P=0.408$ ). (Table 2)

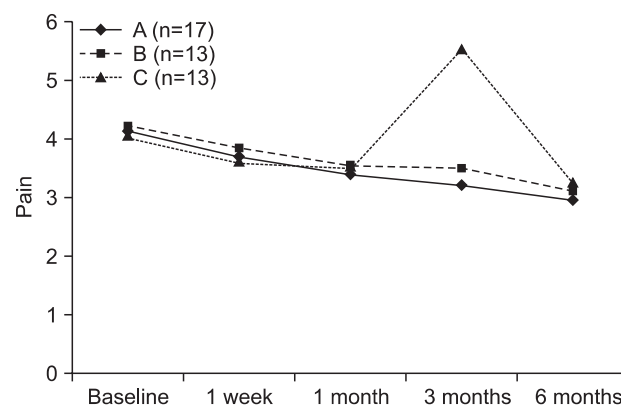
## 2. Descriptive data on pain, MCO, and noise

The descriptive data for pain, MCO, and noise in each group are presented in Table 3. The baseline mean VAS scores for pain for group A, group B, and group C were 5.76, 5.92, and 4.92, respectively. After treatment, there was a reduction in the mean VAS for pain in all groups, with group A, group B, and group C recording 1.38, 1.73, and 2.00, respectively, at the follow-up check after 6 months.

The baseline mean MCO of group A, group B, and group C was 33.06, 31.38, and 29.92, respectively. After treatment, there was an increase in mean MCO in all groups, with group A, group B, and group C recording 43.06, 41.92, and 36.54, respectively. At the follow-up check after 6 months, increases of MCO for group A, group B, and group C were 10.00, 10.54, and 6.62, respectively.

The baseline mean VAS scores for noise of group A, group B, and group C were 1.35, 1.85, and 3.00, respectively. After treatment, there was a reduction in the mean VAS for noise in all groups, with group A, group B, and group C recording 0.62, 1.23, and 1.46, respectively.

For group A, the period of pain<3 was 7.65 weeks, MCO



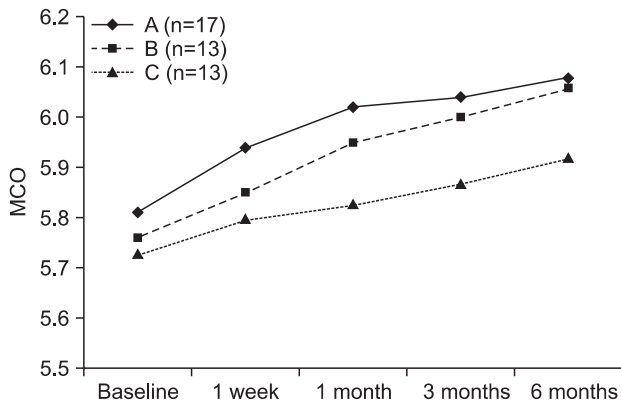
**Fig. 1.** Comparison of visual analog scale (VAS) pain values between groups. F=repeated measure of ANOVA.

Hye-Sung Lee et al: Effect of simultaneous therapy of arthrocentesis and occlusal splints on temporomandibular disorders: anterior disc displacement without reduction. *J Korean Assoc Oral Maxillofac Surg* 2013

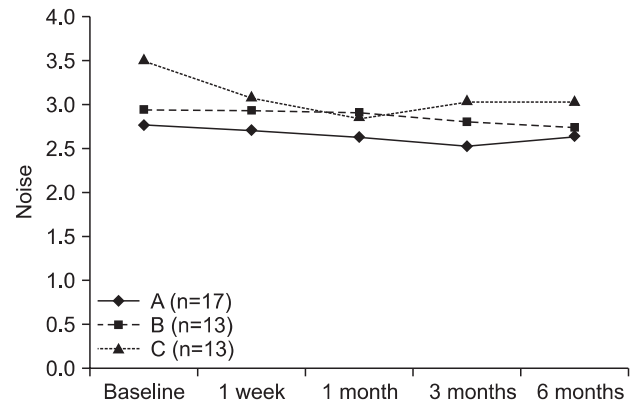
≥38 (or 10) was 5.06 weeks, and both pain<3 and MCO ≥38 (or 10) were 8.65 weeks. For group B, the period of pain<3 was 16.54 weeks, MCO ≥38 (or 10) was 14.62 weeks, and both were 24.69 weeks. Finally, group C recorded 22.08 weeks for the period of pain<3, 40.00 weeks for MCO ≥38 (or 10), and 42.00 weeks for both.

## 3. Comparison of VAS values and MCO between groups

The change patterns for pain, MCO, and noise in each group are shown in Table 4 and Figs. 1-3. We checked the variables at five points: baseline and 1 week, 1 month,



**Fig. 2.** Comparison of maximum comfortable opening (MCO) values between groups. F=repeated measure of ANOVA. Hye-Sung Lee et al: Effect of simultaneous therapy of arthrocentesis and occlusal splints on temporomandibular disorders: anterior disc displacement without reduction. J Korean Assoc Oral Maxillofac Surg 2013



**Fig. 3.** Comparison of the visual analog scale (VAS) noise values between groups. F=repeated measure of ANOVA. Hye-Sung Lee et al: Effect of simultaneous therapy of arthrocentesis and occlusal splints on temporomandibular disorders: anterior disc displacement without reduction. J Korean Assoc Oral Maxillofac Surg 2013

**Table 5.** Comparison of the period to become normal state between groups

Variable	A (n=17)	B (n=13)	C (n=13)	F (P)
Pain<3	4.06±0.95	4.55±1.24	4.79±1.35	1.53 (0.228)
MCO ≥ 38 (or 10)	3.80±0.76 <sup>1</sup>	4.55±1.06 <sup>2</sup>	5.96±0.36 <sup>3</sup>	28.71 (<0.001)
Pain<3 & MCO ≥ 38 (or 10)	4.28±0.83 <sup>1</sup>	5.12±1.10 <sup>2</sup>	6.02±0.34 <sup>3</sup>	16.62 (<0.001)

(MCO: maximum comfortable opening)

F=repeated measure of ANOVA.

1<2<3

Hye-Sung Lee et al: Effect of simultaneous therapy of arthrocentesis and occlusal splints on temporomandibular disorders: anterior disc displacement without reduction. J Korean Assoc Oral Maxillofac Surg 2013

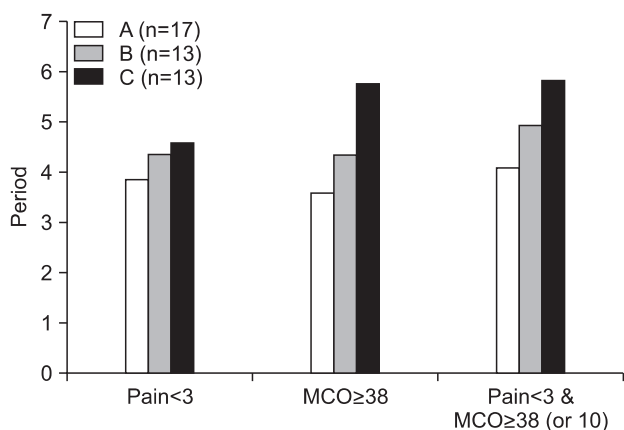
3 months, and 6 months later. For pain, there was no interaction between group and time ( $F=1.48, P=0.199$ ). Time had a significant main effect ( $F=58.31, P<0.001$ ), but the same cannot be said for group ( $F=0.702, P=0.502$ ). Based on Bonferroni’s post hoc test, the levels of pain were found to decrease continuously; the difference was significant in group A ( $F=27.12, P<0.001$ ) and group B ( $F=20.11, P<0.001$ ). In contrast, pain in group C showed a decreasing tendency but increased 3 months later ( $F=15.34, P<0.001$ ).

For MCO, there was no interaction between group and time ( $F=1.21, P=0.314$ ). Group had a significant main effect ( $F=6.25, P=0.004$ ); the main effect of time was not significant, however ( $F=49.67, P<0.001$ ). For noise, there was no interaction between group and time ( $F=1.69, P=0.171$ ). Time had a significant main effect ( $F=4.87, P=0.014$ ), whereas the main effect of group was not significant ( $F=2.34, P=0.109$ ). Bonferroni’s post hoc test showed that noise in group C changed significantly compared to group A or group B. Noise in group C decreased from baseline ( $3.53±0.65$ ) to 1 month later ( $2.88±0.63$ ) and increased 3 months ( $3.06±0.62$ ) and 6 months ( $3.05±0.59$ ) later.

4. Comparison of the period to achieve normal state between groups

ANOVA were conducted to determine if there was any relationship between group and study variables, i.e., period of pain<3, MCO ≥ 38 (or 10) and both pain<3 and MCO ≥ 38 (or 10). Table 5 and Fig. 4 shows that the mean log value of pain<3 was 4.06 in group A, 4.55 in group B, and 4.79 in group C. There was no association between group and period of pain<3 ( $F=1.53, P=0.228$ ). For MCO ≥ 38 (or 10), the mean log level was 3.80 in group A, 4.55 in group B, and 5.96 in group C. There was significant difference according to treatment ( $F=28.71, P<0.001$ ). Group B took longer time to achieve normal state than group A, with group C taking longer time than group B.

For both pain<3 and MCO ≥ 38 (or 10), the mean log score of group A was 4.28, that of group B was 5.12, and that of group C was 6.02. The difference was statistically significant ( $F=16.62, P<0.001$ ). Therefore, “simultaneous application of arthrocentesis and occlusal splint” was proven to be an effective method for TMD.



**Fig. 4.** Comparison of the period to achieve normal state between groups. F=repeated measure of ANOVA.

Hye-Sung Lee et al: *Effect of simultaneous therapy of arthrocentesis and occlusal splints on temporomandibular disorders: anterior disc displacement without reduction. J Korean Assoc Oral Maxillofac Surg* 2013

#### IV. Discussion

This study compared the treatment outcomes of the simultaneous application of arthrocentesis and occlusal splint (group A), arthrocentesis after occlusal splint use (group B), and occlusal splint use only (group C).

As a result, all groups in this study showed improvement in pain, MCO, and noise. There was no interaction between group and time, however. On the other hand, an association was observed between group and period of normal state. For  $MCO \geq 38$  (or 10), there was a significant difference by treatment. Group B took longer time to achieve normal state than group A, with group C taking longer time than group B. For both  $pain < 3$  and  $MCO \geq 38$  (or 10), a statistically significant difference was noted. Group A took less time to achieve normal state than group B and group C. A more effective result was observed in group A than in the two other groups at the initial stage.

Occlusal splint is one of the most widely used treatments for TMD. Carraro and Caffesse<sup>16</sup> claimed that the adoption of occlusal splint reduced TMJ pain by approximately 70% and muscle pain related to increased muscle activity by around 85.2%. According to de Leeuw et al.<sup>17</sup>, a nonsurgical approach achieved long-term effects for patients with internal derangement in a 30-year follow-up study. The initiation of splint use within a short period after symptom onset was found to increase treatment efficiency<sup>18</sup>. Thus, occlusal splint insertion and physical treatment are the most commonly used conservative alternatives<sup>19</sup> through which approximately 90% of all TMD cases can be successfully treated<sup>20</sup>.

Nonetheless, Major and Nebbe<sup>21</sup> reported that the use of occlusal splint resulted in the effective reduction of headache and muscle pain, but that it had a limitation in the reduction of TMJ pain. According to Lundh et al.<sup>22</sup>, occlusal splint had no advantage in treating disc dislocation without reduction.

Therefore, in the treatment of TMD, conservative therapies such as occlusal splint do not achieve a satisfactory outcome in some cases. A surgical method should be considered in such cases. Surgical methods include arthrocentesis, arthroscopy, discectomy, and insertion of implant.

In 1986, Sanders<sup>23</sup> reported that arthrocentesis using saline solution or Ringer's solution was effective in the treatment of synovitis in a case study. Arthrocentesis is developed and established by many researchers - including Murakami et al.<sup>24</sup> in 1987 and Nitzan et al.<sup>25</sup> in 1990 - as a treatment option that shows satisfactory prognosis.

Arthrocentesis is a minimally invasive procedure that may be performed under local anesthesia with or without sedation; its main purpose is to clear the joint of tissue debris, blood, and pain mediators, believed to be byproducts of intra-articular inflammation<sup>26</sup>.

Kropmans et al.<sup>27</sup> investigated the results of 62 previous studies and reported that the combined treatment of arthrocentesis and occlusal splint was effective.

According to Park et al.<sup>28</sup>, the combination of arthrocentesis and stabilization splint for TMD patients enabled an increase in the amount of maximum mouth opening and decrease in the average value of pain.

In light of the results of this study, arthrocentesis and occlusal splint are good for TMD patients. Note, however, that the simultaneous application of arthrocentesis and occlusal splint is more effective, reducing the patient's discomfort in a shorter time and improving the patient's quality of life.

#### V. Conclusion

The improvement of symptoms was noted in group A, group B, and group C, but group A exhibited quicker improvement than the other groups in terms of pain reduction and MCO increases. In other words, a more effective result was observed in group A than in the two other groups at the initial stage.

#### References

1. Karlis V, Glickman R. Nonsurgical management of temporomandibular disorders. In: Miloro M, Ghali GE, Larsen PE,

- Waite P. Peterson's principles of oral and maxillofacial surgery. 2nd ed. Hamilton: BC Decker; 2004:949-50.
2. Ohnuki T, Fukuda M, Nakata A, Nagai H, Takahashi T, Sasano T, et al. Evaluation of the position, mobility, and morphology of the disc by MRI before and after four different treatments for temporomandibular joint disorders. *Dentomaxillofac Radiol* 2006;35:103-9.
  3. Choi JH, Kim IK, Oh NS, Oh SS, Kim ES, Lee SH, et al. A clinical study in the prognosis of the temporomandibular disorder. *J Korean Assoc Oral Maxillofac Surg* 2000;26:497-506.
  4. Peterson LJ. Temporomandibular joint disease. In: Peterson LJ. *Contemporary oral and maxillofacial surgery*. 2nd ed. St. Louis: Mosby-Year Book; 1993:713-36.
  5. Yustin D, Neff P, Rieger MR, Hurst T. Characterization of 86 bruxing patients with long-term study of their management with occlusal devices and other forms of therapy. *J Orofac Pain* 1993;7:54-60.
  6. Nitzan DW. Intraarticular pressure in the functioning human temporomandibular joint and its alteration by uniform elevation of the occlusal plane. *J Oral Maxillofac Surg* 1994;52:671-9.
  7. Sato S, Kawamura H, Motegi K. Management of nonreducing temporomandibular joint disk displacement. Evaluation of three treatments. *Oral Surg Oral Med Oral Pathol Oral Radiol Endod* 1995;80:384-8.
  8. Barkin S, Weinberg S. Internal derangements of the temporomandibular joint: the role of arthroscopic surgery and arthrocentesis. *J Can Dent Assoc* 2000;66:199-203.
  9. Alkan A, Kilic E. A new approach to arthrocentesis of the temporomandibular joint. *Int J Oral Maxillofac Surg* 2009;38:85-6.
  10. Alpaslan C, Kahraman S, Güner B, Cula S. Does the use of soft or hard splints affect the short-term outcome of temporomandibular joint arthrocentesis? *Int J Oral Maxillofac Surg* 2008;37:424-7.
  11. Dworkin SF, LeResche L. Research diagnostic criteria for temporomandibular disorders: review, criteria, examinations and specifications, critique. *J Craniomandib Disord* 1992;6:301-55.
  12. American Association of Oral and Maxillofacial Surgeons. 1984 criteria for TMJ meniscus surgery. Chicago: The Association; 1984:1-40.
  13. Nitzan DW, Dolwick MF, Martinez GA. Temporomandibular joint arthrocentesis: a simplified treatment for severe, limited mouth opening. *J Oral Maxillofac Surg* 1991;49:1163-7.
  14. Holmlund A, Hellsing G. Arthroscopy of the temporomandibular joint. An autopsy study. *Int J Oral Surg* 1985;14:169-75.
  15. McCain JP. Arthroscopy of the human temporomandibular joint. *J Oral Maxillofac Surg* 1988;46:648-55.
  16. Carraro JJ, Caffesse RG. Effect of occlusal splints on TMJ symptomatology. *J Prosthet Dent* 1978;40:563-6.
  17. de Leeuw R, Boering G, Stegenga B, de Bont LG. Symptoms of temporomandibular joint osteoarthritis and internal derangement 30 years after non-surgical treatment. *Cranio* 1995;13:81-8.
  18. Emshoff R. Clinical factors affecting the outcome of occlusal splint therapy of temporomandibular joint disorders. *J Oral Rehabil* 2006;33:393-401.
  19. Chung SC, Kim HS. The effect of the stabilization splint on the TMJ closed lock. *Cranio* 1993;11:95-101.
  20. Randolph CS, Greene CS, Moretti R, Forbes D, Perry HT. Conservative management of temporomandibular disorders: a posttreatment comparison between patients from a university clinic and from private practice. *Am J Orthod Dentofacial Orthop* 1990;98:77-82.
  21. Major PW, Nebbe B. Use and effectiveness of splint appliance therapy: review of literature. *Cranio* 1997;15:159-66.
  22. Lundh H, Westesson PL, Eriksson L, Brooks SL. Temporomandibular joint disk displacement without reduction. Treatment with flat occlusal splint versus no treatment. *Oral Surg Oral Med Oral Pathol* 1992;73:655-8.
  23. Sanders B. Arthroscopic surgery of the temporomandibular joint: treatment of internal derangement with persistent closed lock. *Oral Surg Oral Med Oral Pathol* 1986;62:361-72.
  24. Murakami KI, Iizuka T, Matsuki M, Ono T. Recapturing the persistent anteriorly displaced disk by mandibular manipulation after pumping and hydraulic pressure to the upper joint cavity of the temporomandibular joint. *Cranio* 1987;5:17-24.
  25. Nitzan DW, Dolwick MF, Heft MW. Arthroscopic lavage and lysis of the temporomandibular joint: a change in perspective. *J Oral Maxillofac Surg* 1990;48:798-801.
  26. Diraçoğlu D, Saral IB, Keklik B, Kurt H, Emekli U, Özçakar L, et al. Arthrocentesis versus nonsurgical methods in the treatment of temporomandibular disc displacement without reduction. *Oral Surg Oral Med Oral Pathol Oral Radiol Endod* 2009;108:3-8.
  27. Kropmans TJ, Dijkstra PU, Stegenga B, de Bont LG. Therapeutic outcome assessment in permanent temporomandibular joint disc displacement. *J Oral Rehabil* 1999;26:357-63.
  28. Park YH, Lee SH, Yoon HJ. An effect of combination with arthrocentesis and stabilization splint treatment on temporomandibular joint disorder patient. *J Korean Assoc Maxillofac Plast Reconstr Surg* 2010;32:32-6.