

Endodontic treatment of mandibular molar with root dilaceration using Reciproc single-file system

Daniely Amorin Meireles¹, Mariana Mena Barreto Bastos¹, André Augusto Franco Marques², Lucas da Fonseca Roberti Garcia^{3*}, Emílio Carlos Sponchiado Júnior¹

¹Department of Endodontics, Federal University of Amazonas School of Dentistry, Manaus, AM, Brazil

²Department of Endodontics, State University of Amazonas School of Dentistry, Manaus, AM, Brazil

³Department of Dental Materials and Prosthodontics, University of São Paulo Ribeirão Preto School of Dentistry, Ribeirão Preto, SP, Brazil

Received April 17, 2013;
Revised June 7, 2013;
Accepted June 8, 2013.

¹Meireles DA, Bastos MMB, Sponchiado EC Jr, Department of Endodontics, Federal University of Amazonas School of Dentistry, Manaus, AM, Brazil

²Marques AAF, Department of Endodontics, State University of Amazonas School of Dentistry, Manaus, AM, Brazil

³Garcia LFR, Department of Dental Materials and Prosthodontics, University of São Paulo Ribeirão Preto School of Dentistry, Ribeirão Preto, SP, Brazil

*Correspondence to

Lucas da Fonseca Roberti Garcia, DDS, MSc, PhD.
Post-doctorate Researcher, Department of Dental Materials and Prosthodontics, University of São Paulo Ribeirão Preto School of Dentistry, Rua Siró Kaku, n° 72, apto. 73, Bairro Jardim Botânico, Ribeirão Preto, São Paulo, Brasil CEP, 14021-614
TEL, +55-016-3442-7273; E-mail, drlucas.garcia@gmail.com

Biomechanical preparation of root canals with accentuated curvature is challenging. New rotatory systems, such as Reciproc, require a shorter period of time to prepare curved canals, and became a viable alternative for endodontic treatment of teeth with root dilaceration. Thus, this study aimed to report a clinical case of endodontic therapy of root with accentuated dilaceration using Reciproc single-file system. Mandibular right second molar was diagnosed as asymptomatic irreversible pulpitis. Pulp chamber access was performed, and glide path was created with #10 K-file (Dentsply Maillefer) and PathFile #13, #16 and #19 (Dentsply Maillefer) up to the temporary working length. The working length measured corresponded to 20 mm in the mesio-buccal and mesio-lingual canals, and 22 mm in the distal canal. The R25 file (VDW GmbH) was used in all the canals for instrumentation and final preparation, followed by filling with Reciproc gutta-percha cones (VDW GmbH) and AH Plus sealer (Dentsply Maillefer), using thermal compaction technique. The case has been receiving follow-up for 6 mon and no painful symptomatology or periapical lesions have been found. Despite the difficulties, the treatment could be performed in a shorter period of time than the conventional methods. (*Restor Dent Endod* 2013;38(3):167-171)

Key words: Endodontics; Instrumentation technique; Pulpitis; Reciproc; Root canal

Introduction

Endodontic therapy has reached high success rates thanks to the development of equipment and instrumentation techniques that allow professionals to solve a large number of clinical cases in a shorter period of time. Technological advances have enabled the development of new instruments made of nickel-titanium (NiTi) alloys that have unique characteristics such as shape memory property and superelasticity.^{1,2} Given these characteristics, many NiTi endodontic instruments with fixed taper larger than the conventional ones were introduced into the market with the purpose of facilitating root canal instrumentation in the crown-apex direction, in addition to having a constant taper of 0.04, 0.06, 0.08, 0.10, and 0.12 mm/mm.³⁻⁵

More recently, a new concept was introduced for root canal biomechanical preparation using only one motor-driven NiTi instrument, with no previous instrumentation.^{1,4} The new single-file system with reciprocating motion includes three instruments called Reciproc (R25, R40 and R50), an electric motor (VDW Silver Reciproc, VDW GmbH, Munich, Germany), absorbent paper points and gutta-percha cones.^{6,7} These files are

made of M-Wire NiTi alloy that offers greater flexibility and greater resistance to cyclic fatigue than traditional NiTi.⁸ The main advantage is that the working time is four times faster than the traditional NiTi systems, eliminating cross-contamination between patients, once the instrument is discarded after use.⁸⁻¹⁰ Thus, this manuscript aimed to report a clinical case of endodontic therapy using Reciproc NiTi system in a mandibular molar with an accentuated root curvature.

Case report

The patient, a 22-year old man, complaining of moderate pain in tooth #47 upon chewing, was referred to the Dental Clinic of the Federal University of Amazonas, Brazil. The patient did not have any systemic diseases and were not under any type of medication or drugs. Intraoral examination revealed the presence of a temporary restoration. The tooth was tested for pulp sensibility with Endo Frost spray (Roeko GmbH & Co., Langenau, Germany) and responded positively to the cold test, and negatively to the mobility test. The periapical radiographic examination revealed that the temporary restoration was extremely deep, since the tooth had already been submitted to pulpotomy procedure. Moreover, an accentuated dilaceration in the mesial root, a developmental anomaly characterized by an abrupt change in the axial inclination of the root, was observed. Also, no periapical lesions were observed (Figure 1).

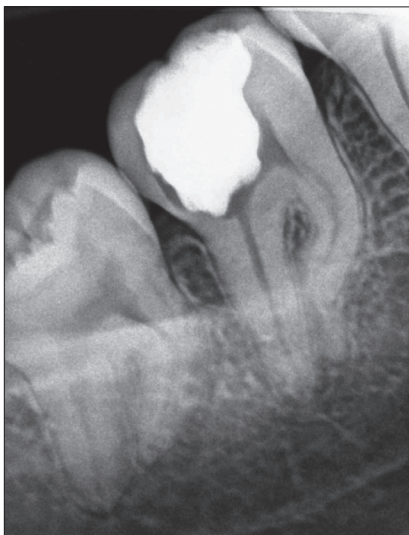


Figure 1. Initial periapical radiograph revealing presence of a deep temporary restoration and accentuated curvature of mesial root in tooth #47.

The tooth was diagnosed as asymptomatic irreversible pulpitis and endodontic treatment was instituted. After local anesthesia (Xylestesin 2%, Cristália Produtos Químicos Farmacêuticos Ltda., Itapira, SP, Brazil) and rubber dam isolation (Hygienic, Coltene/Whaledent AG, Alstatten, Switzerland) of the operative area, the temporary restoration was removed and pulp chamber access procedure using spherical burs No. 1013 (KG Sorensen, São Paulo, SP, Brazil) and tapered flame shaped burs No. 2200 (KG Sorensen) was performed. Next, the root canals orifices were located with the aid of a straight exploratory probe. The glide path was performed using #10 K-files (Dentsply Maillefer, Ballaigues, Switzerland) and Pathfile #13, #16 and #19 (Dentsply Maillefer) up the working length of 18 mm.

Biomechanical preparation of the cervical and middle thirds was performed using the Reciproc system (VDW GmbH, Munich, Germany) coupled to the electric motor Silver Reciproc VDW handpiece (Sirona Dental Systems GmbH, Bensheim, Germany) with 6 : 1 reduction in the Reciproc ALL mode and a R25 file with 0.08 taper. When the cervical and middle thirds were finalized, the working length was measured with the aid of an electronic apex locator (Joypex 5, Denjoy Dental Co., Ltd., Changsha, China), which revealed that the real working length was 20 mm in the mesio-buccal and mesio-lingual canals, and 22 mm in the distal canal. To finalize and refine apical preparation, the R25 file of the Reciproc system was used again in the real working length. At each change of instrument, the canals were irrigated with 2.5 mL of 2.5% Sodium Hypochlorite solution (Biodinâmica, Ibiporã, PR, Brazil) using a disposable syringe and NaviTip needle (Ultradent, South Jordan, UT, USA). After complete instrumentation, 17% ethylenediaminetetraacetic acid (EDTA, Biodinâmica, Ibiporã, PR, Brasil) was used for smear layer removal. The canals were dried with absorbent paper points R5 (VDW GmbH) and filled using gutta-percha cones R25 (VDW GmbH) and AH Plus sealer (Dentsply Maillefer), by thermal compaction technique using McSpadden #50 (Dentsply Maillefer).

Next, the pulp chamber was cleaned to remove the excess of gutta-percha and sealer. Glass-ionomer restorative cement (Vidrion R, SS White, Rio de Janeiro, RJ, Brazil) was used as temporary restoration due to its good sealing ability and fluoride release. After 2 weeks, the tooth was definitely restored with composite resin (Z250, 3M ESPE, Sumaré, SP, Brazil) (Figure 2). Continued follow-up over 6 months has shown a successful outcome from endodontic perspective (Figure 3). Clinically, the tooth presented no painful symptomatology, and radiographically, no signs of failure in root canal filling or periapical lesions were observed.

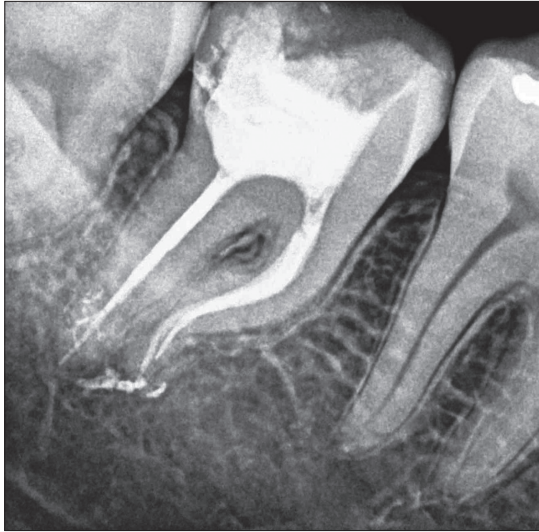


Figure 2. Tooth #47 temporarily restored with glass ionomer cement after root canal filling.

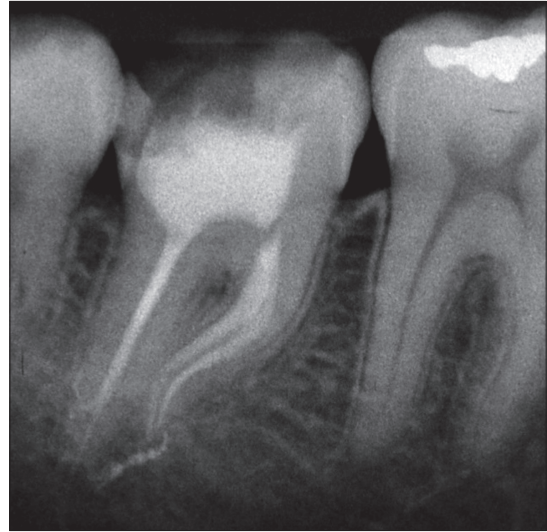


Figure 3. Periapical radiograph of tooth #47 after 6 months, revealing no presence of failure in root canal filling or periapical lesions.

Discussion

For years, several attempts have been made to improve and facilitate biomechanical preparation using different types of motor-driven NiTi instruments.⁵ The present article reports a clinical case of endodontic treatment of root with accentuated dilaceration using Reciproc single-file system. The authors chose to use the new Reciproc system due to the advantages of reduced working time and biomechanical effectiveness, providing greater comfort to the patient and professionals.^{9,10} With the advance of root canal preparation techniques, the number of files used in endodontic treatment had to be reduced. Based on this new concept, Yared described a protocol for root canal preparation using only one NiTi rotary instrument.⁴ The technique consisted of using only one #8 K-type file for glide path creation and a F2 file from the ProTaper rotary system for apical preparation with alternating movements of rotation.⁴

Recently, the previously mentioned technique was revised and a new reciprocating motion called reciprocation was developed.¹⁰ In reciprocation, the instrument rotates counterclockwise and clockwise with 120° of difference between the two movements.⁹⁻¹¹ For every 3 cycles, the instrument takes a turn. Thus, if the instruments are used in 10 cycles of reciprocation per second, it is equivalent to 300 RPM.⁹⁻¹¹ The new reciprocating motion, due to the differentiated kinematics with rotation in counterclockwise direction greater than in the clockwise direction, causes a reduction in the screwing-in effect, with a consequent

reduction of the compression forces, bending fatigue and torsion fracture.^{8,9,12} Moreover, the use of balanced forces technique for biomechanical preparation, such as used in this case report, allows maintenance of the original canal shape in curved root canals.^{10,11}

Several studies which evaluated the instrumentation time and the amount of debris extruded apically after biomechanical preparation, reported that reciprocating instrumentation causes more extrusion of debris than conventional ones.¹³ However, a recent study which compared the ability of shaping and cleaning effectiveness of Reciproc system observed smaller amount of debris in the apical third of canals prepared with this system.¹⁰ Regarding mechanical properties, many studies reported that Reciproc system presented flexural fatigue resistance, cyclic fatigue and torsional strength more appropriate than others found in the market.^{8,9,14-16} Also, according to Kim *et al.*, Reciproc might be more suited for biomechanical preparation of roots with accentuated curvature due to its superior fatigue resistance.⁸ Such increased fatigue resistance is due to the release of reaction stresses in the file by reversing the rotational direction.^{4,12}

It is known that biomechanical preparation time is strictly dependent on the technique and the numbers of instruments used.¹⁰ According to Bürklein *et al.*, Reciproc system decreases the preparation time by 62%, in comparison to other rotatory systems.¹⁰ The reduced biomechanical preparation time when using single-file systems, such as Reciproc, is extremely relevant, since

irrigation content and chemical debridement is also reduced. To compensate for the decreased irrigation time, larger volumes of sodium hypochlorite solution (2.5 mL at each change of instrument) was used in this case, to improve chemical dissolution of debris and disinfection of the root canal system.^{10,17}

It is valid to emphasize that biomechanical preparation of the distal canal was performed easily. However, preparation of both mesial canals was challenging due to the severe root dilaceration. Because of such dilaceration, the glide path was created with Pathfile system. This system has a constant taper of 0.02 mm/mm, in addition to the advantages of the improved design of the tip, which reduces the risk of zip formation and apical deviation, while maintaining the root canal curvature.^{18,19} Due to the mentioned accentuated root canal curvature, the use of a file with a larger diameter could result in apical transportation or zip formation.¹⁶ In this clinical case, anatomical apical diameter was corresponding to a #20 K-file. Thus, according to manufacturer's recommendations, the instrument R25 taper 0.08 was chosen for apical preparation. Moreover, the manufacturer indicates such file size (R25) for narrow and curved canals when manual instruments do not passively reach the real working length. Whereas conventional systems have several apical sizes with gradual diameter increase, Reciproc has files with apical size 25, 40 and 50. The risk of apical transportation and zip formation increases significantly in curved canals, as the file size increases.¹⁶ For this reason, the Reciproc R25 file was selected for biomechanical preparation in this clinical case.

Moreover, the authors decided to use a thermal compaction technique for root canal filling because it provides greater flow of gutta-percha, better adaptation to the root canal walls and adequate filling of anatomical details, such as lateral canals and accessories.²⁰ Such filling technique was capable of promote an adequate hermetic sealing of the root canal along its entire length, despite of the accentuate dilaceration, as can be seen in Figure 2. Also, the McSpadden filling technique promotes lateral and apical gutta-percha plasticization and condensation, allowing filling of whole root canal system.²⁰

Conclusions

This case report demonstrated that the new Reciproc system is an excellent alternative to accomplish root canal instrumentation, especially in roots with accentuated dilaceration. However, further clinical studies are needed to confirm the effectiveness of this new root canal instrumentation system.

Conflict of Interest: No potential conflict of interest relevant to this article was reported.

References

1. Prichard J. Rotation or reciprocation: a contemporary look at NiTi instruments? *Br Dent J* 2012;212:345-346.
2. Elayouti A, Chu AL, Kimionis I, Klein C, Weiger R, Löst C. Efficacy of rotary instruments with greater taper in preparing oval root canals. *Int Endod J* 2008;41:1088-1092.
3. Marchesan MA, Arruda MP, Silva-Sousa YT, Saquy PC, Pecora JD, Sousa-Neto MD. Morphometrical analysis of cleaning capacity using nickel-titanium rotary instrumentation associated with irrigating solutions in mesiodistal flattened root canals. *J Appl Oral Sci* 2003;11:55-59.
4. Yared G. Canal preparation using only one Ni-Ti rotary instrument: preliminary observations. *Int Endod J* 2008;41:339-344.
5. Hülsmann M, Peters OA, Dummer PMH. Mechanical preparation of root canals: shaping goals, techniques and means. *Endod Topics* 2005;10:30-76.
6. Alapati SB, Brantley WA, Iijima M, Clark WA, Kovarik L, Buie C, Liu J, Ben Johnson W. Metallurgical characterization of a new nickel-titanium wire for rotary endodontic instruments. *J Endod* 2009;35:1589-1593.
7. Gutmann JL, Gao Y. Alteration in the inherent metallic and surface properties of nickel-titanium root canal instruments to enhance performance, durability and safety: a focussed review. *Int Endod J* 2012;45:113-128.
8. Kim HC, Kwak SW, Cheung GS, Ko DH, Chung SM, Lee W. Cyclic fatigue and torsional resistance of two new nickel-titanium instruments used in reciprocation motion: Reciproc versus WaveOne. *J Endod* 2012;38:541-544.
9. Gavini G, Caldeira CL, Akisue E, Candeiro GT, Kawakami DA. Resistance to flexural fatigue of Reciproc R25 files under continuous rotation and reciprocating movement. *J Endod* 2012;38:684-687.
10. Bürklein S, Hinschitzka K, Dammaschke T, Schäfer E. Shaping ability and cleaning effectiveness of two single-file systems in severely curved root canals of extracted teeth: Reciproc and WaveOne versus Mtwo and ProTaper. *Int Endod J* 2012;45:449-461.
11. Roane JB, Sabala CL, Duncanson MG Jr. The 'balanced force' concept for instrumentation of curved canals. *J Endod* 1985;11:203-211.
12. De-Deus G, Moreira EJ, Lopes HP, Elias CN. Extended cyclic fatigue life of F2 ProTaper instruments used in reciprocating movement. *Int Endod J* 2010;43:1063-1068.
13. Bürklein S, Schäfer E. Apically extruded debris with reciprocating single-file and full-sequence rotary instrumentation systems. *J Endod* 2012;38:850-852.
14. Pedullà E, Grande NM, Plotino G, Gambarini G, Rapisarda

- E. Influence of continuous or reciprocating motion on cyclic fatigue resistance of 4 different nickel-titanium rotary instruments. *J Endod* 2013;39:258-261.
15. Bürklein S, Benten S, Schäfer E. Shaping ability of different single-file systems in severely curved root canals of extracted teeth. *Int Endod J* 2013;46:590-597.
 16. Yoo YS, Cho YB. A comparison of the shaping ability of reciprocating NiTi instruments in simulated curved canals. *Restor Dent Endod* 2012;37:220-227.
 17. Lim YJ, Park SJ, Kim HC, Min KS. Comparison of the centering ability of Wave·One and Reciproc nickel-titanium instruments in simulated curved canals. *Restor Dent Endod* 2013;38:21-25.
 18. Gergi R, Rjeily JA, Sader J, Naaman A. Comparison of canal transportation and centering ability of twisted files, Pathfile-ProTaper system, and stainless steel hand K-files by using computed tomography. *J Endod* 2010;36:904-907.
 19. Berutti E, Cantatore G, Castellucci A, Chiandussi G, Pera F, Migliaretti G, Pasqualini D. Use of nickel-titanium rotary PathFile to create the glide path: comparison with manual preflaring in simulated root canals. *J Endod* 2009;35:408-412.
 20. Michelotto AL, Moura-Netto C, Araki AT, Akisue E, Moura AA, Sydney GB. *In vitro* analysis of thermocompaction time and gutta-percha type on quality of main canal and lateral canals filling. *Braz Oral Res* 2010;24:290-295.