

RESEARCH ARTICLE

Hypoxia-inducible Factor 1 Alpha (HIF-1 α) as a Prognostic Indicator in Patients with Gastric Tumors: A Meta-analysis

Zhi-Gang Zhang^{1,2}, Qiu-Ning Zhang^{2,3}, Xiao-Hu Wang^{1,2,3*}, Jin-Hui Tian^{1,2}

Abstract

Background and Objective: Though researched for years, the prognostic role of hypoxia-inducible factor 1 alpha (HIF-1 α) in gastric cancer is still controversial. We thus undertook a systematic review to assess the relationship. **Method:** A systematically literature search of Pubmed, Embase, Web of Science, China Biological Medicine Disc and Cochrane Library was undertaken in February 2013, and the reference lists of articles were retrieved. **Results:** 12 trials (1,555 participants) were included to assess the association between HIF-1 α expression and survival. Summary hazard ratios (HRs) were calculated. HIF-1 α expression was significantly correlated with poor overall survival of gastric cancer patients (HR=1.34, 95% CI: 1.13-1.58; $P=0.0009$), but not with poor disease free survival of gastric cancer patients (HR=1.67, 95% CI: 0.99-2.82; $P=0.06$). **Conclusion:** HIF-1 α was associated with poor OS, but not DFS, especially for Asian patients. But studies evaluating relationships of HIF-1 α with OS and DFS in non-Asian gastric cancer patients appear needed.

Keywords: Stomach neoplasm - Hypoxia-inducible factor - survival - meta-analysis

Asian Pac J Cancer Prev, 14 (7), 4195-4198

Introduction

Although its declining incidence, gastric tumor still accounted for 8% of the total new cancer cases and 10% of total deaths caused by cancer worldwide (Bertuccio et al., 2009; Jemal et al., 2011). The highest incidence rates were high in Eastern Asia, Eastern Europe, and South America while twice as high in males as in females. Despite improvement in surgical techniques and oncology treatments, the prognosis of gastric cancers was still poor. New treatment methods are still needed and new therapy targets may help.

HIF was recognized to be the master regulatory protein in the response of cells to change oxygen levels (Semenza., 2003). HIF family composed of bHLH-PAS proteins including an O²-labile alpha subunit (HIF-1 α , HIF-2 α , or HIF-3 α) and a stable beta subunit (HIF-1 β), which together bind hypoxia responsive elements (HREs). HIF-1 α accounts for an important effect on tumor growth and progression which is degraded in normoxia, but stabilized in hypoxia. HIF-1 α expression in a variety of human cancers tissue was first observed by Zhong, et al (Zhong et al., 1999). Then subsequent studies with greater numbers of patients had observed a negative correlation between HIF-1 α expression and prognosis. And the targeted inhibition of HIF-1 α has been shown to inhibit the growth of gastric tumors in animals (Yeo et al., 2003; Stoeltzing et al., 2004). But there were still conflicting results in several tumor sub-sites, including cervical, lung and ovarian cancer. The prognostic role of HIF-1 α in

gastric tumor had been searched in many trials particular in East Asia. Most have shown expression of HIF-1 α was associated with a poor prognosis; however, others didn't or only showed a trend without statistically significance. Aiming to evaluate the prognostic role of HIF-1 α expression in gastric tumor, we undertook a systematic review according to the Cochrane Handbook 5.1.

Materials and Methods

Search strategy

Systematic literature searches in Cochrane Library, PubMed, EMBASE, Web of Science, and China Biological Medicine Disc were conducted to identify available clinical studies. All search queries were updated until February 2013. The keywords were ('Hypoxia-inducible factor 1' OR HIF 1) AND ('Gastric' OR 'stomach' OR 'Gastro*') AND ('adenocarcinoma' OR 'carcinoma' OR 'tumor' OR 'cancer' OR 'Neoplasm' OR 'malignan*'). MeSH terms as well as free text words were used. Pre-retrievals were performed to adjust the search queries in the individual database. In addition, reference lists were traced to complement search queries.

Selection criteria

Clinical studies identified by the searches were scrutinized by two independent observers (Zhang ZG and Zhang QN). Publications were included in pooled analyses if they met all of the following criteria:

- 1). The patients must be gastric cancer patients.

¹Evidence Based Medicine Center of Lanzhou University, ²The First Clinical Medical College of Lanzhou University, ³Department of Radiation Oncology, Gansu Provincial Tumor Hospital, Lanzhou, China *For correspondence: xhwanggs@126.com

Table 1. The General Characteristics of Included Studies

Author and year of publication	Study location	No of tissue specimens	criteria of HIF-1 α expression Median (rang)	Outcomes	follow-up
Isobe T 2012	Japan	128	Positive if TNS \geq 5%.	OS, DFS	44.9(0-60)
Qiu MZ 2011	China	188	Positive if TNS at both the cancer central and invasive front	OS	60(3-120)
Shen CL 2010	China	135	intensity (0-no, 1-light, 2-moderate, 3-severe) positive if intensity \geq 1	OS	(5-104)
Nakamura J 2009	Japan	91	Positive if TNS at both the cancer central and invasive front	DFS	22.5(0.3-99.8)
Zhou LH 2009	China	62	positive if TNS \geq 10%	OS	(1-82)
Oh SY 2008	Korea	114	Positive if TNS \geq 10%	DFS	24.5(14-32)
Kolev Y 2008	Japan	152	Strong CS \geq 50% or TNS \geq 10%	OS, DFS	53(1-144)
Griffiths EA 2007	UK	135	positive if TNS \geq 0%	OS, DFS	48(13-118)
Yang ZR 2007	China	135	intensity (0-no, 1-light, 2-moderate, 3-severe) positive if intensity \geq 1	OS	18(2-40)
Urano N 2006	Japan	146	Positive if TNS \geq 10%	OS	(0-90)
Sumiyoshi Y 2006	Japan	216	Positive if TNS \geq 10%	OS	(0-60)
Takahashi R 2003	Japan	53	Positive if TNS \geq 10%	OS	81.7 \pm 63.2* (12-222)

TNS, Tumour nuclear staining; CS, cytoplasmic staining; CF, clinicopathological features; OS, overall survival; DFS, disease free survival; RFS, relapse free survival *Mean \pm SD

2). Studies compared the different outcomes between HIF-1 expression or not.

3). The immunohistochemical staining method and the diagnosis criteria of HIF-1 expression must be reported.

4). If studies involved multiple cancer patients, there must be a subgroup analysis of gastric cancer.

5) Studies must report overall survival (OS) or disease free survival (DFS).

Data extraction

Following data were extracted and cross-checked from all clinical studies by two individual authors (Zhang ZG and Zhang QN). Firstly, General characteristics: first author, year of publication, sample size, study location, assessment of HIF-1 α staining. If necessary data were extracted from figures, discrepancies were discussed together for a unanimous decision. If the HR or standard errors (SE) weren't reported in included studies, we calculate or estimate the HR from available data or Kaplan-Meie curves using the methods reported by Tierney et al. (2007).

Statistical analysis

For primary outcomes, hazard ratio (HR) was used for meta-analyses; pooled analyses were performed by inverse variance method using random-effects models. Heterogeneity between trials was assessed by means of the I^2 test and Cochran's Q statistic. All meta-analyses were performed in Review Manager 5.1 and a P -value 0.05 was considered statistically significant.

Results

The search strategies identified 12 eligible clinical studies (Takahashi et al., 2003; Sumiyoshi et al., 2006; Urano et al., 2006; Griffiths et al., 2007; Yang et al., 2007; Kolev et al., 2008; Oh et al., 2008; Zhou et al., 2009; Nakamura et al., 2010; Shen et al., 2010; Qiu et al., 2011; Isobe et al., 2013). PRISMA flowchart was described in

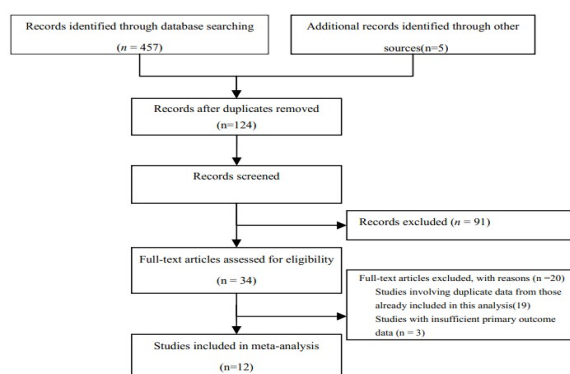


Figure 1. Flow Chart

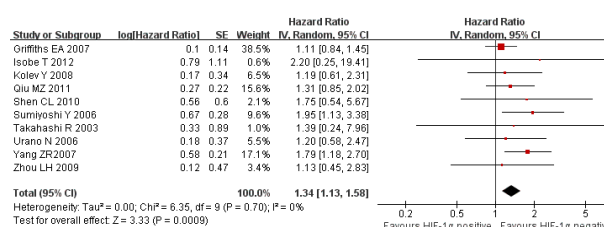


Figure 2. Meta-analysis of the Relationship of HIF-1 α and OS

Figure 1. Most of them located in East Asia (11 studies). The general characteristics were present in Table 1.

Overall Survival (OS)

Compared with non-expression, HIF-1 α expression was associated with significantly worse OS (HR=1.34, 95%CI: 1.13-1.58; $P=0.0009$) (Takahashi et al., 2003; Sumiyoshi et al., 2006; Urano et al., 2006; Griffiths et al., 2007; Yang et al., 2007; Kolev et al., 2008; Zhou et al., 2009; Shen et al., 2010; Qiu et al., 2011; Isobe et al., 2013) (Figure 2).

DFS

Compared with non-expression, HIF-1 α expression was not associated with significantly worse DFS (HR=1.67, 95%CI: 0.99-2.82; $P=0.06$) (Kolev et al., 2008;

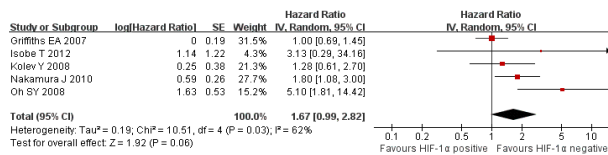


Figure 3. Meta-analysis of the Relationship of HIF-1 α and DFS

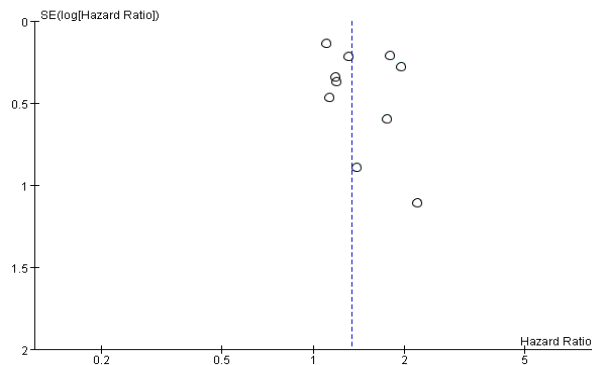


Figure 4. Publication Bias

Oh et al., 2008; Nakamura et al., 2010; Isobe et al., 2013) (Figure 3).

Evaluation of publication bias

The funnel plot of the log HRs versus the inverse of their variances of the individual studies was preformed. There was no indication of an obvious for publication bias (Figure 4).

Discussion

Summary of finding: Available evidence indicated HIF-1 α was associated with worse OS, but not associated with worse DFS. Since expression of HIF-1 α was first observed in some tumors types by Zhong et al. (1999), it has emerged as a key regulator of the growth of solid tumors by subsequent studies. Over the past ten years, there was increased evidence suggesting that HIF-1 α may be involved in the development and prognosis of gastric tumourigenesis. When uncommonly expressed or low expressed in normal or benign gastric tissue, positive HIF-1 α staining was found in pre-malignant gastric tissue such as *H. pylori* gastritis, intestinal metaplasia, etc (Griffiths et al., 2007). And progressively increased expression has been observed in the pre-malignant and malignant phase of gastric tumors.

Tumorigenesis is a multistep process that requires certain properties include uncontrolled cell division, suppression of senescence, inhibition of apoptosis and induction of angiogenesis (Hanahan et al., 2000). In the process, HIF-1 α expression may be influenced by factors other than hypoxia. Vascular endothelial growth factor (VEGF) expression is a key factor in angiogenesis which is essential for growth and metastasis of solid tumors. A recent Meta-analysis had demonstrated that positive expression of tissue VEGF were associated with poor prognosis in resectable gastric cancer (Liu et al., 2012). When tumors grow larger, newly vessels should generate to deliver oxygen because the diffusion distances limitation of oxygen. Tumor vascularity can be assessed by staining the blood vessel endothelia in the tissue and

expressed in microvessel density (Vermeulen et al., 1996). HIF-1 α may present as a regulatory protein in the expression of VEGF. There was one study reported the worst prognosis in patients with VEGF (+) and HIF-1 α (+) (Isobe et al., 2013). So based on available evidence, HIF-1 α could be recognized as an independent prognostic factor in patients with gastric tumors.

Strength and limitations: This meta-analysis used rigor meta-analysis methods to evaluate the relationship of HIF-1 α with gastric cancer OS and DFS, and included all available study about this topic. However, our meta-analysis still has limitations.

First: Most studies we included were about Asian patients. And few non-Asian studies were found.

Second: Though immunohistochemical assays method of HIF-1 α was similar, the positive criterion of HIF-1 α was different among studies. Though tumor nuclear staining were conducted in all included studies, the thresholds proportion of tumor nuclear staining to determine positive HIF-1 α varied from 0 to 10%. And also there was some different grading standard to identify weak, distinct or strong expression. In two studies (Nakamura et al., 2010; Qiu et al., 2011), TNS at both the cancer central and invasive front was identified as positive.

Implications: Available evidence showed that HIF-1 α was associated with worse OS, but not associated with worse DFS. However, most studies were from Asian countries, so studies in non-Asian countries should be conducted in the future.

At the same time, the thresholds proportion of tumor nuclear staining to determine positive HIF-1 α varied among studies, so in the future, a well recognized standard should be formed worldwide.

In conclusion, HIF-1 α was associated with poor OS, but not DFS, especially for Asian patients. But studies that evaluated the relationships of HIF-1 α with OS and DFS in non-Asian gastric cancer patients were needed.

Acknowledgements

The author(s) declare that they have no competing interests.

References

- Bertuccio P, Chatenoud L, Levi F, et al (2009). Recent patterns in gastric cancer: a global overview. *Int J Cancer*, **125**, 666-73.
- Griffiths EA, Pritchard SA, Valentine HR, et al (2007). Hypoxia-inducible factor-1alpha expression in the gastric carcinogenesis sequence and its prognostic role in gastric and gastro-oesophageal adenocarcinomas. *Br J Cancer*, **96**, 95-103.
- Hanahan D, Weinberg RA (2000). The hallmarks of cancer. *Cell*, **100**, 57-70.
- Isobe T, Aoyagi K, Koufujii K, et al (2013). Clinicopathological significance of hypoxia-inducible factor-1 alpha (HIF-1alpha) expression in gastric cancer. *Int J Clin Oncol*, **18**, 293-304.
- Jemal A, Bray F, Center MM, et al (2011). Global cancer statistics. *CA Cancer J Clin*, **61**, 69-90.
- Kolev Y, Uetake H, Takagi Y, Sugihara K (2008). Lactate dehydrogenase-5 (LDH-5) expression in human gastric cancer: association with hypoxia-inducible factor (HIF-

- 1alpha) pathway, angiogenic factors production and poor prognosis. *Ann Surg Oncol*, **15**, 2336-44.
- Liu L, Ma XL, Xiao ZL, et al (2012). Prognostic value of vascular endothelial growth factor expression in resected gastric cancer. *Asian Pac J Cancer Prev*, **13**, 3089-97.
- Nakamura J, Kitajima Y, Kai K, et al (2010). HIF-1alpha is an unfavorable determinant of relapse in gastric cancer patients who underwent curative surgery followed by adjuvant 5-FU chemotherapy. *Int J Cancer*, **127**, 1158-71.
- Oh SY, Kwon HC, Kim SH, et al (2008). Clinicopathologic significance of HIF-1alpha, p53, and VEGF expression and preoperative serum VEGF level in gastric cancer. *BMC Cancer*, **8**, 123.
- Qiu MZ, Han B, Luo HY, et al (2011). Expressions of hypoxia-inducible factor-1alpha and hexokinase-II in gastric adenocarcinoma: the impact on prognosis and correlation to clinicopathologic features. *Tumour Biol*, **32**, 159-66.
- Semenza GL (2003). Targeting HIF-1 for cancer therapy. *Nat Rev Cancer*, **3**, 721-32.
- Shen CL, Shen ZB, Chen WD (2010). Expressions of VEGF, HIF-1 in gastric cancer and their impact on prognosis. *Chin Gen Prac*, **13**, 2460-6.
- Stoeltzing O, McCarty MF, Wey JS, et al (2004). Role of hypoxia-inducible factor 1alpha in gastric cancer cell growth, angiogenesis, and vessel maturation. *J Natl Cancer Inst*, **96**, 946-56.
- Sumiyoshi Y, Kakeji Y, Egashira A, et al (2006). Overexpression of hypoxia-inducible factor 1 α and p53 is a marker for an unfavorable prognosis in gastric cancer. *Clin Cancer Res*, **12**, 5112-7.
- Takahashi R, Tanaka S, Hiyama T, et al (2003). Hypoxia-inducible factor-1alpha expression and angiogenesis in gastrointestinal stromal tumor of the stomach. *Oncol Rep*, **10**, 797-802.
- Tierney JF, Stewart LA, Ghersi D, et al (2007). Practical methods for incorporating summary time-to-event data into meta-analysis. *Trials*, **8**, 16.
- Urano N, Fujiwara Y, Doki Y, et al (2006). Overexpression of hypoxia-inducible factor-1 alpha in gastric adenocarcinoma. *Gastric Cancer*, **9**, 44-9.
- Vermeulen PB, Gasparini G, Fox SB, et al (1996). Quantification of angiogenesis in solid human tumours: an international consensus on the methodology and criteria of evaluation. *Eur J Cancer*, **32A**, 2474-84.
- Yang ZR, Wu Q, Li DW, Chen JW (2007). Expression and clinical significance of Notch1 and HIF-1 α proteins in human gastric carcinoma. *J Shanxi Med Univ*, **38**, 498-502.
- Yeo EJ, Chun YS, Cho YS, et al (2003). YC-1: a potential anticancer drug targeting hypoxia-inducible factor 1. *J Natl Cancer Inst*, **95**, 516-25.
- Zhong H, De Marzo AM, Laughner E, et al (1999). Overexpression of hypoxia-inducible factor 1alpha in common human cancers and their metastases. *Cancer Res*, **59**, 5830-5.
- Zhou LH, Li LH, G L (2009). Expressions of TP and HIF-1 α in gastric carcinoma tissues and their correlations with prognosis. *Chin J Cance R Prev Treat*, **16**, 1315-9.