

## Reduction of superior-lateral intact mandibular condyle dislocation with bone traction hook

Bong Chul Kim<sup>1</sup>, Sara Rebeca Kang Samayoa<sup>2</sup>, Hyung Jun Kim<sup>2</sup>

<sup>1</sup>Department of Oral and Maxillofacial Surgery, Daejeon Dental Hospital, College of Dentistry, Wonkwang University, Daejeon,

<sup>2</sup>Department of Oral and Maxillofacial Surgery, College of Dentistry, Yonsei University, Seoul, Korea

**Abstract** (J Korean Assoc Oral Maxillofac Surg 2013;39:238-241)

Lateral and superior-lateral dislocations of the intact condyle are a rare complication, following traumatic insult to the mandible. We report an unusual case of a 54-year-old male patient who experienced both types of dislocations of the intact condyles with symphysis fracture following a road-traffic accident. Under general anesthesia, conventional manipulation was unsuccessful in relocating the condyles into the glenoid fossa. After applying a percutaneous traction force, using a bone traction hook placed at the sigmoid notch, the displaced intact mandibular condyles were repositioned, and the symphyseal fracture was finally reduced and fixed. The mouth opening was within normal limits, and favorable occlusion was confirmed one month postoperatively. To our knowledge, this is the first case of dislocation of both intact condyles--associated with symphysis fracture--being reduced with bone traction hook.

**Key words:** Lateral dislocation, Mandibular fractures, Reduction, Condyle

[paper submitted 2013. 1. 3 / revised 2013. 1. 30 / accepted 2013. 1. 31]

### I. Introduction

Condylar dislocations commonly occur in association with a mandibular fracture as a result of facial trauma, and its displacement is commonly anterior rather than posterior, lateral, or superior. Condylar dislocations with combined direction of displacement have often been misdiagnosed or entirely neglected due to their extremely rare occurrence. Such is the case of superior-lateral dislocations. According to Yoshii et al.<sup>1</sup>, clinicians should bear in mind the possibility of an unusual condylar dislocation whenever the signs, symptoms, and clinical courses are not typical of common mandibular fracture. In this paper, we present an unusual case of lateral dislocation of the intact mandibular condyle with symphysis fracture and describe a method of reduction using bone-

traction hook.

This study was approved by the local Ethics Committee of the Dental College Hospital of Yonsei University, Seoul, Korea, after obtaining written consent from the patient.

### II. Case Report

A 54-year-old man visited Yonsei University Health System with four-day history of maxillofacial trauma. During the injury, he was under the influence of alcohol; he only recalled being hit with a falling luggage from a passing truck before landing on the ground. He did not experience loss of consciousness or vomiting. Before he was referred to the Department of Oral and Maxillofacial Surgery, the severity of his injuries was evaluated at the emergency room. The medical history revealed controlled diabetes mellitus and hypertension. During the physical examination, limitation of mandibular movement, unfavorable occlusion, tenderness to palpation of chin and bilateral temporomandibular joints (TMJ), and bony prominence in both preauricular regions were observed. The panoramic radiograph and three-dimensional computed tomography (3D CT) showed fracture of the symphyseal region and dislocation of both condyles. The 3D CT clearly revealed the evident lateral displacement of the left condyle;

#### *Hyung Jun Kim*

Department of Oral and Maxillofacial Surgery, College of Dentistry, Yonsei University, 50, Yonsei-ro, Seodaemun-gu, Seoul 120-752, Korea  
TEL: +82-82-2-2228-3132 FAX: +82-2-2227-8022  
E-mail: kimoms@yuhs.ac

©This is an open-access article distributed under the terms of the Creative Commons Attribution Non-Commercial License (<http://creativecommons.org/licenses/by-nc/3.0/>), which permits unrestricted non-commercial use, distribution, and reproduction in any medium, provided the original work is properly cited.

Copyright © 2013 The Korean Association of Oral and Maxillofacial Surgeons. All rights reserved.

the right condyle was severely dislocated laterally from the glenoid fossa and engaged over the lateral surface of the zygomatic arch. The bilateral condyles and zygomatic arches were intact and were not fractured.(Fig. 1)

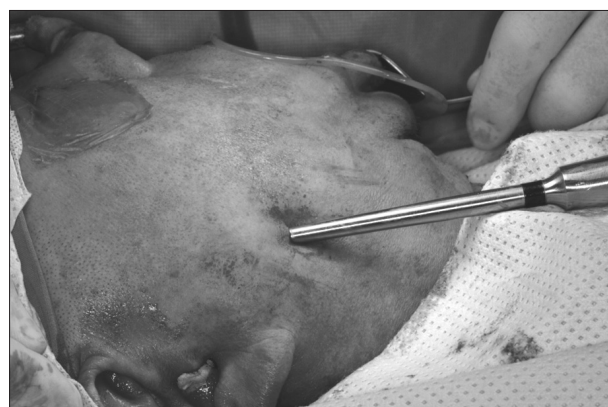The patient was hospitalized and immediately transferred to the operating room. Under general anesthesia via nasal intubation, manual reduction of the bilateral condyle dislocation was attempted, to no avail. Bone traction hook was placed at the sigmoid notch through stab incision, and reduction was finally achieved after applying outward traction. (Fig. 2) Open reduction and internal fixation of the mandibular symphysis fracture were done with self-reinforced, biodegradable poly-70L/30DL-lactide plates and screws. The mandible was placed into the intermaxillary fixation (IMF) with IMF screws and elastics for seven days. Intensive jaw physiotherapy was instituted for one month. We instructed the patient to open his mouth to the maximum extent possible and move anteriorly/laterally.

Lateral and posterior-anterior cephalographic images were obtained during the first post-operative day and month. All images verified the position of the bilateral dislocated condyles into the glenoid fossa and reduction of symphysis fracture. Even though the right condyle seemed to be displaced slightly laterally (Fig. 3), mouth opening was found to be within normal limits, and favorable occlusion was confirmed. No symptoms of TMJ disorder were observed. Unfortunately, the patient was not cooperative, and long-term follow-up could not be performed.

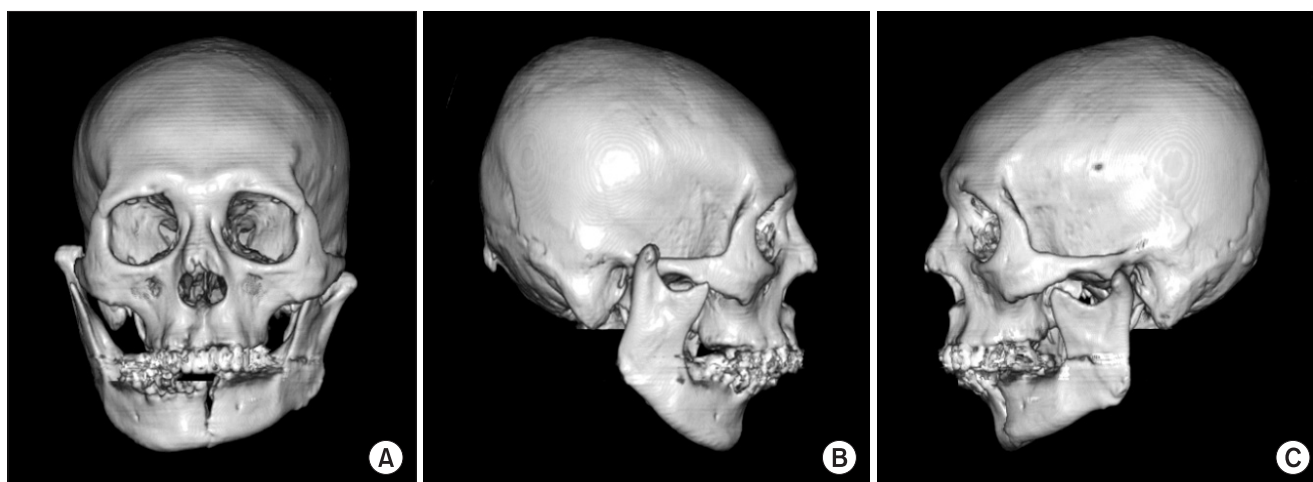
### III. Discussion

Although PubMed database listed 23 cases published between 1969 and 2011<sup>1-17</sup>, there were few reports of superior-lateral dislocation of intact mandibular condyle. Medial pulling of the pterygoid muscles during impact on the face may partly contribute to the rarity of condylar lateral displacement<sup>13</sup>. According to Amaral et al.<sup>17</sup>, maxillofacial trauma associated with superior or lateral dislocation of the intact mandibular condyle is more predominant among young male adults who have figured in a road traffic accident.

Allen and Young<sup>2</sup> classified the lateral dislocation of the

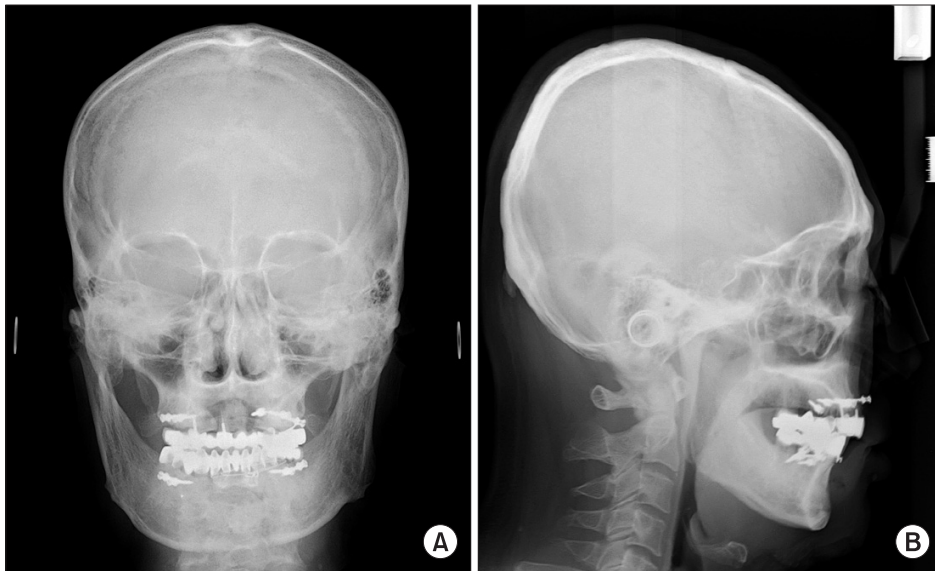

**Fig. 2.** Successful reduction of the right intact condyle was performed by applying external force with bone traction hook via stab incision at the level of sigmoid notch of the same side.  
*Bong Chul Kim et al: Reduction of superior-lateral intact mandibular condyle dislocation with bone traction hook. J Korean Assoc Oral Maxillofac Surg 2013*



**Fig. 1.** Three-dimensional reconstruction of the computed tomography scan showing the bilateral dislocation of the condyles situated lateral to the zygomatic arch and associated with symphysis fracture. A. The posterior-anterior view shows symphyseal fracture with marked lateral displacement on the left side of the mandible. B. The right lateral view exhibits the right condyle head dislocated superior-laterally to the zygomatic arch. C. Lateral view, left side.

*Bong Chul Kim et al: Reduction of superior-lateral intact mandibular condyle dislocation with bone traction hook. J Korean Assoc Oral Maxillofac Surg 2013*



**Fig. 3.** Postoperative posterior-anterior (A) and lateral (B) cephalographic images demonstrating the satisfactory reduction of symphyseal fracture and bilateral reduction of both mandibular intact condyles. Slight lateral displacement of the right condyles is noticeable in the lateral view.

Bong Chul Kim et al: Reduction of superior-lateral intact mandibular condyle dislocation with bone traction hook. J Korean Assoc Oral Maxillofac Surg 2013

mandibular condyle into two types: type I (lateral subluxation), wherein the condyle is laterally displaced from the fossa; and type II (complete dislocation), wherein the condyle has been dislocated both laterally and superiorly as it enters the temporal fossa. Satoh et al.<sup>8</sup> further subdivided type II dislocation into three subcategories: type IIA, wherein the condyle is not hooked above the zygomatic arch; type IIB, wherein the condyle is hooked above the zygomatic arch; and type IIC, wherein the condyle is lodged into the zygomatic arch. The present case fits the criteria of right-type IIB and left-type I mandibular condyle dislocations.

Amaral et al.<sup>17</sup> pointed out that high energy of trauma could induce this type of dislocation and anterior mandibular fractures. According to Allen and Young<sup>2</sup>, in such cases, there was always a history of trauma to the chin usually associated with fracture in the symphyseal region. The related mandibular fracture obviously promoted the rotation and movement of the ramus, which would facilitate the superior or lateral dislocation of the condyle as observed in the current case and previously reported cases<sup>2,6-9,11,13,17</sup>. As described by other authors, however, intact mandibular condyle dislocations may also occur occasionally without traumatic fractures<sup>5,12,14,16</sup>.

Among the treatment options for intact condyle dislocations, manual reduction is the simplest, least traumatic, and safest<sup>1,12,18</sup>. Nonsurgical methods such as traction wire placed at the angle of the mandible<sup>6,9</sup> or mouth props--functioning as fulcrum--placed in the molar region<sup>12</sup> have been previously used. According to the literature review, however, open reduction was selected for treating 52.2% of the cases, whereas

closed reduction was carried out in the remaining 43.5%<sup>1-17</sup>. Reduction was not completed in one case<sup>11</sup>. The higher rates of open reduction may be correlated to the waiting time for treatment<sup>17</sup>. Delay in treatment may cause fibrosis of the glenoid fossa, resulting in incomplete reduction. The formation of fibrous tissue can make manual reduction impossible<sup>12</sup>. In the present case, the patient visited the emergency room four days after the trauma, and manual reduction under general anesthesia was unsuccessful. To our knowledge, this is the first reported case of type IIB dislocation reduced with the aid of bone traction hook. By modifying the approach of close reduction, we were able to impose strong traction, disengage the condyle from above the zygomatic arch, and relocate both condyles to their normal positions. Despite the radiographic evidence of slight lateral displacement of the right condyle in the postoperative posterior-anterior cephalographic image (Fig. 3), the patient did not manifest any discomfort or mouth opening limitation.

In summary, superior or lateral dislocation of the intact condyle is often neglected yet requires thorough physical and radiographic examinations. Early diagnosis and management are strongly emphasized because prolonged dislocation can make reduction more difficult, leading to unsatisfactory results. Manual reduction is the first treatment option for superior-lateral condylar dislocations; in delayed cases, however, open reduction or application of strong traction force by means of an extraoral route--bone traction hook, for example--is highly recommended in this case report due to its favorable outcome.

## References

1. Yoshii T, Hamamoto Y, Muraoka S, Teranobu O, Shigeta Y, Komori T. Traumatic dislocation of the mandibular condyle into the temporal fossa in a child. *J Trauma* 2000;49:764-6.
2. Allen FJ, Young AH. Lateral displacement of the intact mandibular condyle. A report of five cases. *Br J Oral Surg* 1969;7:24-30.
3. Brusati R, Painsi P. Facial nerve injury secondary to lateral displacement of the mandibular ramus. *Plast Reconstr Surg* 1978;62:728-33.
4. Worthington P. Dislocation of the mandibular condyle into the temporal fossa. *J Maxillofac Surg* 1982;10:24-7.
5. DeVita CL, Friedman JM, Meyer S, Breiman A. An unusual case of condylar dislocation. *Ann Emerg Med* 1988;17:534-6.
6. Ferguson JW, Stewart IA, Whitley BD. Lateral displacement of the intact mandibular condyle. Review of literature and report of case with associated facial nerve palsy. *J Craniomaxillofac Surg* 1989;17:125-7.
7. To EW. Supero-lateral dislocation of sagittally split bifid mandibular condyle. *Br J Oral Maxillofac Surg* 1989;27:107-13.
8. Satoh K, Suzuki H, Matsuzaki S. A type II lateral dislocation of bilateral intact mandibular condyles with a proposed new classification. *Plast Reconstr Surg* 1994;93:598-602.
9. Kapila BK, Lata J. Superolateral dislocation of an intact mandibular condyle into the temporal fossa: a case report. *J Trauma* 1996;41:351-2.
10. Hoard MA, Tadge JP, Gampper TJ, Edlich RF. Traumatic chronic TMJ dislocation: report of an unusual case and discussion of management. *J Craniomaxillofac Trauma* 1998;4:44-7.
11. Rattan V. Superolateral dislocation of the mandibular condyle: report of 2 cases and review of the literature. *J Oral Maxillofac Surg* 2002;60:1366-9.
12. Bu SS, Jin SL, Yin L. Superolateral dislocation of the intact mandibular condyle into the temporal fossa: review of the literature and report of a case. *Oral Surg Oral Med Oral Pathol Oral Radiol Endod* 2007;103:185-9.
13. Hsieh CH, Chen CT, Tsai HH, Lai JP. Lateral dislocation of bilateral intact mandibular condyles with symphysis fracture: a case report. *J Trauma* 2007;62:1518-21.
14. Li Z, Li ZB, Shang ZJ, Wu ZX. An unusual type of superolateral dislocation of mandibular condyle: discussion of the causative mechanisms and clinical characteristics. *J Oral Maxillofac Surg* 2009;67:431-5.
15. Lloyd TE, Sivarajasingam V. An unusual cranial dislocation of the mandibular condyle. *Br J Oral Maxillofac Surg* 2010;48:176-7.
16. Papadopoulos H, Edwards RS. Superolateral dislocation of the condyle: report of a rare case. *Int J Oral Maxillofac Surg* 2010;39:508-10.
17. Amaral MB, Bueno SC, Silva AA, Mesquita RA. Superolateral dislocation of the intact mandibular condyle associated with panfacial fracture: a case report and literature review. *Dent Traumatol* 2011;27:235-40.
18. Kallal RH, Gans BJ, Lagrotteria LB. Cranial dislocation of mandibular condyle. *Oral Surg Oral Med Oral Pathol* 1977;43:2-10.