

1

Traumatic bone cyst resembling a periapical abscess: A case report

Department of Dentistry, Dongsan medical center, College of Medicine, Keimyung University

Ju-Yeon Cho

ABSTRACT

Traumatic bone cyst resembling a periapical abscess: A case report

Department of Dentistry, Dongsan medical center, College of Medicine, Keimyung University
Ju-Yeon Cho

Traumatic bone cyst is known as a symptomless, radiolucent bony lesion incidentally found during routine radiographic examinations. The main characters of traumatic bone cyst are asymptomatic and unicystic radiolucent bony lesion with vital tooth. This case is a confusing case of a traumatic bone cyst with sudden gingival swelling and appearance like a periapical abscess. After surgical exploration and drainage, clinical and radiographic examination showed bony healing with pulpal vitality preserved after 7 months postoperatively.

Key words : traumatic bone cyst, periapical, abscess

I. Introduction

The radiolucent areas surrounding the apices of a tooth may be misdiagnosed as apical periodontitis or periradicular cyst with pulpal involvement¹⁾. Especially in case of having history of previous trauma, the periradicular radiolucency of the post-traumatic areas tends to be easily considered as a chronic periapical lesion due to pulpal necrosis of affected tooth²⁾.

Moreover, if gingival or facial swelling accompanies with such circumstances, erroneous diagnosis of odontogenic abscess as a result of pulpal infection may be led^{1, 3)}. So, the accurate diagnosis is essential to consider the lesion to be of endodontic or non-endodontic origin and ensure the maintenance of pulpal vitality⁴⁾.

The traumatic bone cyst is a vacant intraosseous cystic lesion within bony wall that mainly occurs in the mandible of

young patients^{2, 5}). However, it cannot be regarded as a true cyst because of the absence of a capsule and epithelial lining^{1, 5, 6}. The etiology of the lesion is unclear and may be associated with traumatic injury⁷. The teeth that involved in the area of the cyst remain vital and surgical intervention almost results in complete resolution of the defect^{4, 8, 9}.

The following report presents an unusual case of traumatic bone cyst that could be misdiagnosed as periapical abscess with persistent gingival swelling.

II. Case report

A 16-year-old boy was referred for evaluation of chin and gingival swelling that had been persisted for one week in spite of antimicrobial medication. The

medical history was unremarkable and the dental history indicated that there was no toothache but tenderness at anterior gingival swelling area of mandible.

The patient informed that he hit his own chin against something 4 months ago and the sudden swelling started one week before visiting our hospital. He has been taking antimicrobial agent for a week at other clinic but the gingival swelling persisted.

Clinical examination revealed a soft swelling on the mucolabial fold of anterior mandibular incisors with slight chin swelling. A periapical abscess, periradicular cyst or other soft tissue tumor were suspected.

The panoramic and periapical radiograph showed a small round radiolucency measuring about 1cm around the periradicular area of left central incisor and lateral

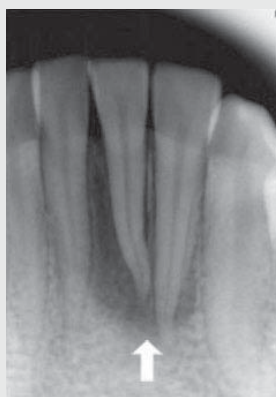

Fig. 1 Periapical x-ray showed periradicular radiolucency around mandibular incisors

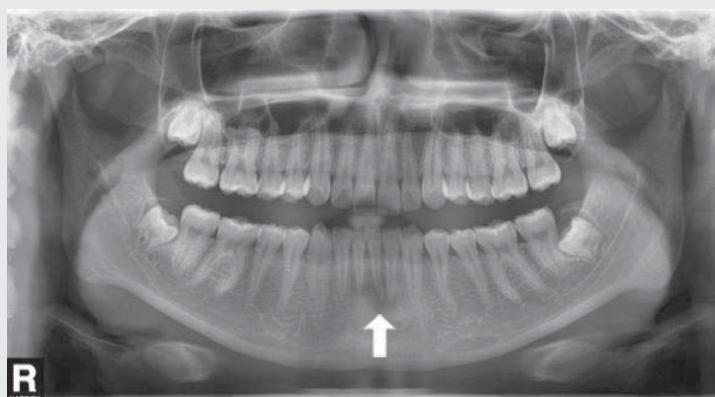


Fig. 2 Dental panoramic view

incisor of mandible(Fig. 1,2), so soft tissue tumor was ruled out and periradicular abscess or cyst was taken into consideration.

A periapical abscess with vestibular swelling of left mandibular central and lateral incisors due to devitalized pulp was strongly suspicious because of prior trauma history and being negative to electronic pulp test(EPT) and cold test. But the color, mobility and percussion test of involved teeth were normal and similar to that of adjacent teeth.

Under local anesthesia, incision and drainage were performed at lower anterior vestibule, but bloody exudate with floating tissue particles was emerged instead of purulent discharge.

Bloody discharge was swabbed for microbial culture, and tissues from incisional biopsy together with the floating

tissue debris were sent to laboratory for histological examination after curettage of the lesion.

Histological examination revealed granulation tissue rather than cystic lesion due to the absence of epithelial lining(Fig. 3). Microorganism identified from the culture was streptococcus α -hemolyticus which was frequently found in oral cavity.

Follow-up after 1, 4, 7 month postoperatively showed slight delayed but increasing response to EPT and cold test of left mandibular central and lateral incisor, which considered as being vital.

The postoperative course was favorable. There has been no recurrence and the patient is still in follow up periods of 7 months after surgical operation. The radiolucency around left mandibular incisors was also reduced, and the involved teeth showed normal color and nearly

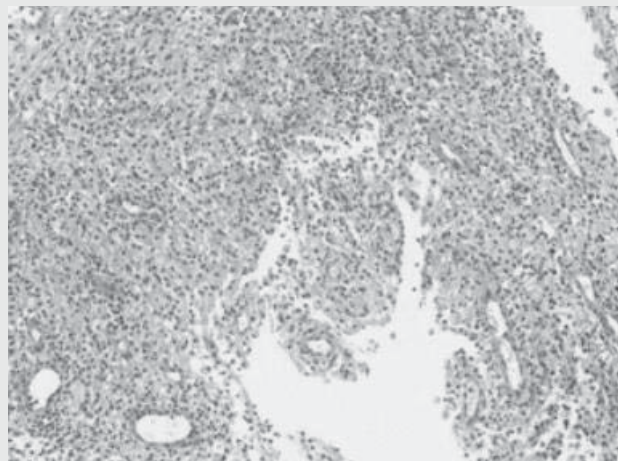


Fig. 3 Microscopic view, granulation tissues without epithelial linings (H&E staining, original magnification $\times 100$)

normal response to pulpal vitality test(Fig. 4, 5). However, long term follow up is still needed.

III. Discussion

The traumatic bone cyst is a rare lesion of the jaws and the pathogenesis remains unclear. The most accepted hypothesis at present is the traumatic-hemorrhagic theory, which suggests that the lesions develop when intramedullary blood clots due to trauma do not dissolve or resolve¹⁰.

This theory explains the higher incidence of traumatic bone cysts in young individuals and also explains the presence of blood within the lesions.

Traumatic bone cysts are considered almost exclusively mandibular lesions¹¹, especially the posterior areas although the

symphysis may also be a site of predilection^{12, 13}. The histologic feature reveals only a connective tissue membrane lining the lesion, which is the characteristic of pseudocysts, and hemorrhagic foci, cholesterol crystals and osteoclasts may be found within the lesion^{14, 15}. A final diagnosis of a traumatic bone cyst is usually made at the time of surgery. Surgeons usually encounter an empty or bloody, serous-filled cavity, which may represent different stages in the development of traumatic bone cyst^{3, 4, 16}.

The treatment of choice for traumatic bone cysts is curettage of the lesion, which generally results in short term healing^{14, 15, 17, 18}. Recurrence is rare, but when occurs, it is usually present within three months of surgery⁵. After conventional therapy has proved unsuccessful, other treatment options like the placement of bone chips,

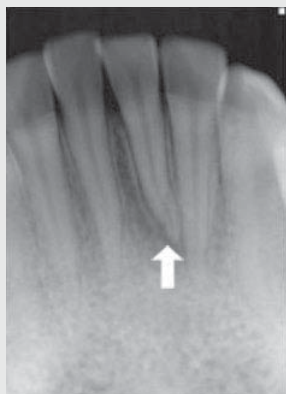

Fig. 4 periapical x-ray(7 months after curettage): reduced radiolucency and intact lamina dura

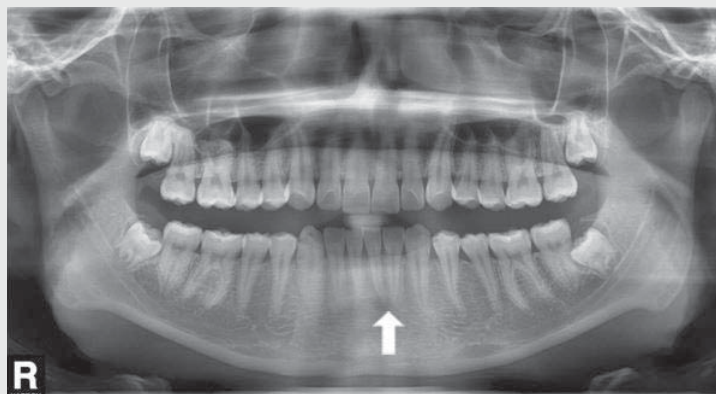


Fig. 5 Dental panoramic view(7 months after curettage)

hydroxyapatite, packing the cavity with thrombin sponge or aspiration may be included^{4, 19)}.

In this case, intraoral swelling in the labial vestibule of 16-year-old boy was misdiagnosed as odontogenic infection at first, but proved as traumatic bone cyst after clinical, radiographic and histological correlation. There was a prior history of trauma and periradicular radiolucency, which mimic the signs and symptoms of an endodontic lesion. But careful diagnosis avoided unnecessary endodontic treatment of the young patient's teeth. He had been free of symptom after trauma for four months, and there were no fracture of mandibular incisors. But slight crowding of mandibular incisors was observed which was suspected of producing TFO(truma

from occlusion). Therefore, the cause of sudden gingival swelling might be the result of TFO or other infection of previous traumatic bone cyst, rather than periapical abscess due to pulpal necrosis. Surgical exploration and curettage revealed clear, bloody exudate instead of purulent discharge, and resulted in progressive reduction of the radiolucency and intact lamina dura of the involved tooth at the 7 months follow up appointment. The tooth showed positive to EPT and cold test and there were no clinical symptoms or discoloration. The clinical, radiological and histological findings of traumatic bone cyst are very diverse²⁰⁾, therefore we should put these together for getting accurate diagnosis.

참 고 문 헌

- Rodrigues CD, Estrela C. Traumatic bone cyst suggestive of large apical periodontitis. *Journal of endodontics*. 2008;34(4):484-9.
- Kahler B. Traumatic bone cyst suggestive of a chronic periapical abscess: a case report. *Australian endodontic journal : the journal of the Australian Society of Endodontology Inc*. 2011;37(2):73-5.
- Rosen DJ, Ardekian L, Machtei EE, Peled M, Manor R, Laufer D. Traumatic bone cyst resembling apical periodontitis. *Journal of periodontology*. 1997 ;68(10):1019-21.
- Hansen LS, Sapone J, Sproat RC. Traumatic bone cysts of jaws. *Oral surgery, oral medicine, and oral pathology*. 1974;37(6):899-910.
- Martins-Filho PR, Santos Tde S, de Araujo VL, Santos JS, Andrade ES, da Silva LC. Traumatic bone cyst of the mandible: a review of 26 cases. *Brazilian journal of otorhinolaryngology*. 2012;78(2):16-21.
- Matsumura S, Murakami S, Kakimoto N, Furukawa S, Kishino M, Ishida T, et al. Histopathologic and radiographic findings of the simple bone cyst. *Oral surgery, oral medicine, oral pathology, and endodontics*. 1998;85(5):619-25.
- Dellinger TM, Holder R, Livingston HM, Hill WJ. Alternative treatments for a traumatic bone cyst: a longitudinal case report. *Quintessence international*. 1998;29(8):497-502.

참 고 문 헌

8. Rushton MA. Solitary bone cysts in the mandible. *British dental journal*. 1946;81(2):37-49.
9. Cowan CG. Traumatic bone cysts of the jaws and their presentation. *International journal of oral surgery*. 1980;9(4):287-91.
10. Howe GL. 'Haemorrhagic cysts' of the mandible. II. *The British journal of oral surgery*. 1965;3(2):77-91.
11. Ruiz-Hubard EE, Harrison JW. Healing of a traumatic bone cyst after nonsurgical endodontic treatment. *Journal of endodontics*. 1987;13(1):40-2.
12. Sapp JP, Stark ML. Self-healing traumatic bone cysts. *Oral surgery, oral medicine, and oral pathology*. 1990;69(5):597-602.
13. Tong AC, Ng IO, Yan BS. Variations in clinical presentations of the simple bone cyst: report of cases. *Journal of oral and maxillofacial surgery : official journal of the American Association of Oral and Maxillofacial Surgeons*. 2003;61(12):1487-91.
14. Harnet JC, Lombardi T, Klewansky P, Rieger J, Tempe MH, Clavert JM. Solitary bone cyst of the jaws: a review of the etiopathogenic hypotheses. *Journal of oral and maxillofacial surgery : official journal of the American Association of Oral and Maxillofacial Surgeons*. 2008;66(11):2345-8.
15. Baqain ZH, Jayakrishnan A, Farthing PM, Hardee P. Recurrence of a solitary bone cyst of the mandible: case report. *The British journal of oral & maxillofacial surgery*. 2005;43(4):333-5.
16. Kuhmichel A, Bouloux GF. Multifocal traumatic bone cysts: case report and current thoughts on etiology. *Journal of oral and maxillofacial surgery : official journal of the American Association of Oral and Maxillofacial Surgeons*. 2010;68(1):208-12.
17. Penarrocha-Diago M, Sanchis-Bielsa JM, Bonet-Marco J, Minguez-Sanz JM. Surgical treatment and follow-up of solitary bone cyst of the mandible: a report of seven cases. *The British journal of oral & maxillofacial surgery*. 2001;39(3):221-3.
18. Feinberg SE, Finkelstein MW, Page HL, Dembo JB. Recurrent "traumatic" bone cysts of the mandible. *Oral surgery, oral medicine, and oral pathology*. 1984;57(4):418-22.
19. Chapman PJ, Romaniuk K. Traumatic bone cyst of the mandible; regression following aspiration. *International journal of oral surgery*. 1985;14(3):290-4.
20. 윤정훈, 김도경, 안성건, 김수관. 악골 외상성 골낭의 임상 및 병리조직학적 분석. *대한악안면성형외과학회지* 2003; 25:18-24.