

Gram-negative Septicemia after Infliximab Treatment in an Infant with Refractory Kawasaki Disease

Jin Hwan Lee, M.D., Jung Min Yoon, M.D., Jae Woo Lim, M.D.,
Kyong Og Ko, M.D., Ph.D., and Eun Jung Cheon, M.D.

Department of Pediatrics, Konyang University College of Medicine, Daejeon, Korea

Kawasaki disease (KD) is an immune-mediated disease which is a leading cause of acquired cardiovascular disease in developed country. Recently, tumor necrosis factor- α (TNF- α) blocker, infliximab has been considered a promising option for patients with refractory KD. Although chronic use of a TNF- α blocker could increase risk of opportunistic infections, a few studies have documented that use of infliximab was safe without serious adverse effects in patients with KD. We observed serious bacterial infection after infliximab treatment in an infant with refractory KD. Our patient was a 5-month-old male infant diagnosed with KD who did not respond to repeated doses of intravenous immunoglobulin. We effectively treated him with a single infusion of infliximab (5 mg/kg), but gram-negative (*Acinetobacter Iwoffii*) septicemia developed after infliximab infusion. Therefore, we report a case of serious septicemia after treatment with infliximab, and suggest considering the risk of severe infection when deciding whether to prescribe infliximab to an infant with refractory KD.

Key Words: Kawasaki disease, Tumor necrosis factor- α , Infliximab, Septicemia

Introduction

Kawasaki disease (KD) is an acute febrile disease of unknown etiology, characterized by systemic vascular inflammation involving the small- and medium-sized arteries, with a predilection for the coronary arteries¹⁾. Intravenous immunoglobulin (IVIG) infusion is an effective therapy for acute KD, as it reduces the duration of fever and the prevalence of

coronary artery aneurysms²⁾. Nevertheless, approximately 10% of patients are refractory to IVIG treatment; refractory KD is defined as persistent fever of $\geq 38.5^{\circ}\text{C}$ for 36 hours after initial IVIG treatment³⁾. These patients are in need of additional therapy, such as repeated doses of IVIG or pulse methylprednisolone^{4, 5)}.

Recently, infliximab, tumor necrosis factor- α (TNF- α) blocker, has also been considered a promising option for patients with refractory KD⁶⁾. Although chronic use of a TNF- α blocker might increase the risk of opportunistic infections⁷⁾, a few studies have documented that the use of infliximab was safe, without serious adverse effects, in patients with KD refractory to IVIG^{8, 9)}. However, we observed a case of gram-negative septicemia that developed after infliximab treatment in a 5-month-

*The authors have no conflicts of interest relevant this article to disclose.

Received : 21 July 2014, Revised : 28 August 2014

Accepted : 1 September 2014

Correspondence : Eun Jung Cheon, M.D.

Department of Pediatrics, Konyang University College of Medicine, Daejeon, Korea

Tel : +82-42-600-9230, Fax : +82-42-600-9090

E-mail : ejcheon000@kyuh.ac.kr

old infant with refractory KD.

Case Report

A 5-month-old male infant with body weight of 5.7 kg (<3rd percentiles) and height of 63 cm (10–25th percentiles), was admitted because of high fever up to 40°C developed at two days prior to admission. He was born at 36(+6) gestational weeks with birth weight of 2 kg. He had been small for gestational age because of maternal hypertension. Physical examination revealed bilateral non-exudative conjunctival injection, red cracked lips, strawberry tongue, subcutaneous edema, erythema of hands and feet, erythema at the BCG site, and erythematous maculopapular rashes on the trunk and extremities. Laboratory tests showed the following results (1st hospital day [HD]): white blood cell (WBC) count 39,200 cells/μL (segmented neutrophils 77%, lymphocytes 20%), hemoglobin (Hb) 10.9 g/dL, hematocrit (Hct) 32.1%, platelet count 466,000 cells/μL, erythrocyte sedimentation rate (ESR) 61 mm/h, C-reactive protein (CRP) 16.5 mg/dL, albumin 4.0 g/dL, protein 6.29 g/dL, asparatate aminotransferase/alanine aminotransferase (AST/ALT) 34/17 IU/L,

and N-terminal fragment of prohormone B-type natriuretic peptide (NT-proBNP) 1,040 pg/mL (Table 1). Urinalysis showed 10–20 WBC per high power field. No respiratory virus was identified in the common respiratory virus polymerase chain reaction (RV-PCR) test. The results of initial blood and urine cultures were unremarkable. We performed echocardiography, which revealed an aneurysm of 5 mm in diameter at the left main coronary artery.

His fever persisted despite treatment with IVIG (2 g/kg; 2nd HD) and aspirin (50 mg/kg/day); therefore, we administered a second dose of IVIG (2 g/kg; 4th HD). He was also treated with empirical antibiotic (ampicillin/sulbactam) from the 1st to the 12th day after admission. Nevertheless, the patient remained febrile, and other symptoms of KD persisted. The follow-up laboratory examination (5th HD) showed the following results: WBC count 12,800 cells/μL (segmented neutrophils 49%, lymphocytes 37%), Hb 9.2 g/dL, Hct 28%, ESR 69 mm/h, CRP 18.1 mg/dL, albumin 2.4 g/dL, protein 7.5 g/dL, AST/ALT 18/45 IU/L, NT-proBNP 3,066 pg/mL, blood urea nitrogen (BUN) 2.6 mg/dL and creatinine (Cr) 0.35 mg/dL. Echocardiography revealed a 5-mm fusiform dilatation in the proximal lesion of the

Table 1. Clinical Course of the Laboratory Findings

Day	WBC (cells/μL)	Seg. N (%)	Hb (g/dL)	Platelet (cells/μL)	Albumin (g/dL)	AST (IU/L)	ALT (IU/L)	CRP (mg/dL)	ESR (mm/h)	NT-proBNP (pg/mL)
Initial admission										
1	39,200	77	10.9	466,000	4	34	17	16.5	61	1,040
5	12,800	49	9.2	331,000	2.4	18	45	18.1	69	3,066
17	16,700	26.1	8.8	995,000	3.7	42	48	0.2	49	388
Readmission										
1	24,700	48.1	9.2	660,000	3.8	27	18	3.9	42	
5	28,100	30	9.4	606,000	3.3	26	16	12.3	68	
9	16,700	34.2	9.5	698,000	3.7	46	31	0.8	45	

Abbreviations: WBC, white blood cell; Seg. N, segmented neutrophil; Hb, hemoglobin; AST, asparatate aminotransferase; ALT, alanine aminotransferase; CRP, C-reactive protein; ESR, erythrocyte sedimentation rate; NT-proBNP, N-terminal fragment of prohormone B-type natriuretic peptide.

left anterior descending (LAD) artery, entire tubular dilatation in the other coronary arteries, and trivial mitral regurgitation. He was diagnosed with refractory KD and we decided to perform the treatment with a single infusion of infliximab (5 mg/kg) (7th HD). All symptoms of KD, including fever, improved within 48 hours after infliximab infusion. The patient was discharged on low-dose aspirin at the seventeenth day of illness. At five days after discharge, he was readmitted because of abrupt onset of high fever, mild generalized edema, and poor urination without any other respiratory symptoms. The patient showed lethargic and edematous appearance; his blood pressure was 80/50 mmHg, and his pulse rate was 130 beats/min. Laboratory investigations (1st HD) revealed: WBC count 24,700 cells/ μ L (segmented neutrophils 48.1%, lymphocytes 34.1%), Hb 9.2 g/dL, Hct 28.2%, platelet count 660,000 cells/ μ L, ESR 42 mm/h, CRP 3.9 mg/dL, albumin 3.8 g/dL, protein 7.5 g/dL, AST/ALT 27/18 IU/L, BUN/Cr 15.7/0.46 mg/dL. Urinalysis was clear, and a chest radiogram was unremarkable. Echocardiographic findings were similar to those from the previous examination. We prescribed intravenous antibiotic (ampicillin/sulbac-

tam) from the 1st day of readmission. Nevertheless, the patient had persistent spiking fever and remained lethargic and edematous appearance. On the fifth day of readmission, CRP level was increased up to 12.3 mg/dL, and the initial a couple of blood cultures showed the presence of *Acinetobacter lwoffii*, which was susceptible to cefotaxime, gentamicin, and imipenem. We promptly administered cefotaxime according to the results of the blood culture. On the seventh day of readmission, the patient's fever gradually subsided, and his general condition recovered. A follow-up blood culture was subsequently negative. The patient was treated with appropriate antibiotics for two weeks and then discharged (Fig. 1). Three months later, we consulted a pediatric immunologist for evaluation of his immunologic function, and all immunologic tests were normal. Therefore, we assumed that our patient's gram-negative septicemia might be associated with infusion of infliximab, based on his previous history of treatment with an immunosuppressant agent, clinical findings such as a spiking fever, lethargy, oligouria, and hypotension, positive blood cultures, and dramatic improvement of symptoms including fever after treatment with an

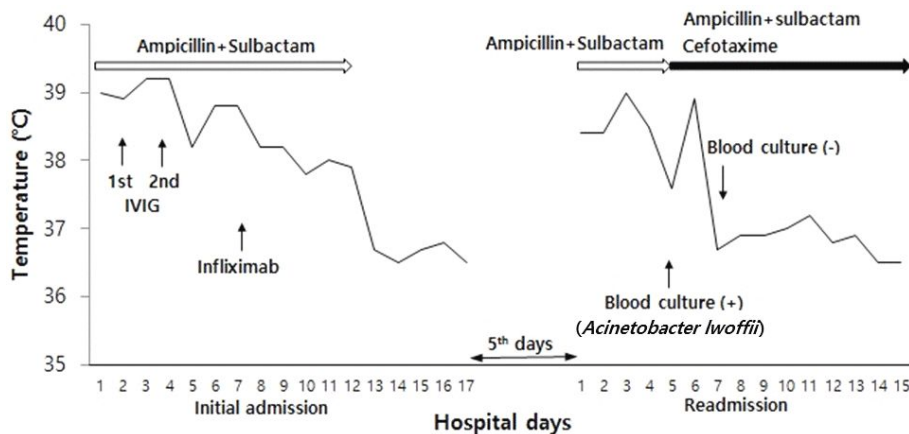


Fig. 1. Changes in the body temperature and the types of interventions used during the hospital course.

antibiotic susceptible to *A. Iwoffii*.

Discussion

Standard treatment of KD with IVIG and high-dose aspirin is highly effective²⁾; 80–90% of patients show disease remission. Unresponsiveness to IVIG has been considered a major risk factor for the development of coronary artery lesions³⁾. Recently, it has been suggested that pulse methylprednisolone⁵⁾ and second line treatments, such as infliximab and methotrexate¹⁰⁾, may be used for children with KD who fail to respond to a repeated doses of IVIG.

TNF- α blockers have been shown to be effective immunosuppressive therapy in most children and adolescents with refractory Crohn's disease (CD)¹¹⁾. As well, TNF- α and TNF- α soluble receptors I and II concentrations increase in the acute phase of KD, and they are the highest in children who subsequently develop coronary artery aneurysms¹²⁾. Infliximab neutralizes the biological activity of TNF- α by binding with high affinity to the soluble and transmembrane forms of TNF- α . Neutralization of the biological activity of TNF- α leads to an overall reduction in inflammation. So infliximab administration can be a very important rescue medication for children with refractory KD⁹⁾¹³⁾. Mori et al. described a case series in which 18 of 20 patients were effectively treated with infliximab to prevent progression to coronary artery lesions, without any adverse events¹⁴⁾.

Infliximab inhibits the binding of TNF- α and its receptors, and it subsequently reduces production of pro-inflammatory cytokines, such as interleukins 1 and 6. As a result, this limits leukocyte migration and expression of adhesion molecules by

endothelial cells and leukocytes. Infliximab also limits the activation of neutrophil and eosinophil functional activity and interferes with the production of cytotoxic metabolites by macrophages, thereby decreasing phagocytic killing activity. Surface-bound TNF- α is likely to be involved in cell-to-cell interactions, possibly potentiating the activation of specific and non-specific immune effective cells¹⁵⁾. Given the complex cytokine interactions and the multiple cytokine targets, infliximab-associated immunomodulation is very likely to lead to a higher risk of severe infections. It has been noted that chronic use of a TNF- α blocker over months to years was associated with an increased risk of infections with mycobacteria and fungi^{16, 17)}. Furthermore, Kroesen et al. documented that disseminated infections may give rise to serious bacterial infections from both gram-positive and gram-negative microorganisms in patients with rheumatoid arthritis who received anti-TNF- α therapy¹⁸⁾. A case report described an adult patient with CD receiving infliximab who experienced pulmonary infection due to *Acinetobacter* species, diagnosed via quantitative sputum cultures, along with another gram-negative infection¹⁹⁾. However, although a few studies reported that single infusions of infliximab were not associated with severe infection in any infants with KD⁹⁾, complications caused by a single dose of infliximab have not been clearly documented.

Generally, while the effectiveness of antibiotic use is not clear, a previous study demonstrated that KD is associated with marked activation of monocyte/macrophages and the selective expansion of V β 2- and, less so, of V β 8.1/8.2-expressing T cells in the peripheral blood from KD patients during the acute phase of their illness. These immunologic fea-

tures are characteristic of diseases that are caused by bacterial toxins, which act as superantigens²⁰. In other respects, there is a possibility that bacterial infection caused by immunomodulation during and after treatment with infliximab can occur. In our case, we administered an antibiotic empirically during treatment with infliximab; however, they were ineffective against *A. Iwoffii*. Therefore, we could not prevent the development of septicemia caused by *A. Iwoffii*. For that reason, we suppose that administration of appropriate antibiotics not only can help prevent KD, which might be triggered by bacterial infection, but can also help prevent septicemia after infliximab treatment.

Our patient, a 5-month-old male infant with KD, failed to defervesce despite repeated doses of IVIG. Therefore, a single infusion of infliximab (5 mg/kg) was administered on the seventh day of illness; his fever and other systemic symptoms promptly resolved within 2 days. However, within 2 weeks after treatment with infliximab, he was diagnosed with *A. Iwoffii* septicemia, having clinical symptoms such as a spiking fever, lethargy, oligouria, and hypotension. *A. Iwoffii* is an immotile, aerobic gram-negative coccobacillus that has become important in nosocomial infections, mostly involving patients with impaired host defense. Although differentiation between blood specimen contamination by skin inhabitants and true bacteremia is sometimes rather difficult, significant bacteremia caused by *Acinetobacter* species is highest rate of nosocomial bacteremia occurring during the second week of hospitalization. Especially, it is well known that *Acinetobacter spp.* is considered to be organisms capable of causing severe nosocomial infection in neonatal intensive care units²¹.

Regrettably, we did not perform immunologic tests

in our patient, but we consulted a pediatric immunologist in another hospital, and his investigations revealed that the patient's immunologic function was competent. Our patient experienced septicemia within 2 weeks after an infusion of infliximab. Bruns et al. documented that infliximab-mediated deletion of T cells persists for 2 weeks after initiating therapy²². Furthermore, our patient's clinical symptoms, including a fever, resolved dramatically after treatment with an antibiotic to which *A. Iwoffii* was susceptible, according to the results of the microbiological sensitivity tests. Considering the above reasons, we speculate that gram-negative septicemia in our patient may have been associated with the use of infliximab. Therefore, we suggest that patients, especially infants or young children, should be closely monitored for signs and symptoms of infection during and after treatment with infliximab, including the possible development of serious infections.

한 글 요약

불응성 가와사키병 환아에서 infliximab 사용 후 발생한 패혈증

건양대학교 의과대학 소아과학교실

이진환 · 윤정민 · 임재우 · 고경옥 · 천은정

최근 가와사키병에서 tumor necrosis factor- α (TNF- α) blocker인 infliximab 단일 정주 요법이 불응성 가와사키병 환아들에게 유용한 치료제로 여겨지고 있다. 장기적인 TNF- α blocker 사용이 기회감염의 위험을 증가시킬 수 있지만, 가와사키병 환아들에게 infliximab 사용이 심각한 부작용을 초래하지 않으며 안전하게 사용된 증례들이 보고된 바 있다. 불응성 가와사키병을 앓고 있는 5개월 된 영아에서 infliximab (5 mg/

kg) 단일 정주 요법을 사용하였고 가와사키 증상이 호전되었으나 infliximab 치료 후 *Acinetobacter Iwoffii*에 의한 패혈증이 발생하였다. 그래서 저자들은 불응성 가와사키병을 앓은 영아에서 infliximab 치료 후 발생한 패혈증의 첫 사례를 보고하며 infliximab 치료 선택에 있어 기회 감염의 위험성에 대해 고려할 것을 당부하는 바이다.

References

- Melish ME. Kawasaki syndrome. *Pediatr Rev* 1996;17:153-62.
- Newburger JW, Takahashi M, Burns JC, Beiser AS, Chung KJ, Duffy CE, et al. The treatment of Kawasaki syndrome with intravenous gamma globulin. *N Engl J Med* 1986;315:341-7.
- Burns JC, Capparelli EV, Brown JA, Newburger JW, Glode MP. Intravenous gamma-globulin treatment and retreatment in Kawasaki disease. US/Canadian Kawasaki Syndrome Study Group. *Pediatr Infect Dis J* 1998;17:1144-8.
- Sundel RP, Burns JC, Baker A, Beiser AS, Newburger JW. Gamma globulin re-treatment in Kawasaki disease. *J Pediatr* 1993;123:657-9.
- Furukawa T, Kishiro M, Akimoto K, Nagata S, Shimizu T, Yamashiro Y. Effects of steroid pulse therapy on immunoglobulin-resistant Kawasaki disease. *Arch Dis Child* 2008;93:142-6.
- Burns JC, Mason WH, Hauger SB, Janai H, Bastian JF, Wohrley JD, et al. Infliximab treatment for refractory Kawasaki syndrome. *J Pediatr* 2005;146:662-7.
- Bongartz T, Sutton AJ, Sweeting MJ, Buchan I, Matteson EL, Montori V. Anti-TNF antibody therapy in rheumatoid arthritis and the risk of serious infections and malignancies: systematic review and meta-analysis of rare harmful effects in randomized controlled trials. *JAMA* 2006;295:2275-85.
- Yu HJ, Lee SJ, Sohn S. Infliximab treatment for a patient with refractory Kawasaki disease. *Korean J Pediatr* 2006;49:987-90.
- Adriana H, Tremoulet, Sonia J. Infliximab for intensification of primary therapy for Kawasaki disease: a phase 3 randomised, double-blind, placebo-controlled trial. *The Lancet* 2014;83:1731-8.
- Shin JI, Lee JS, Choi JY, Kim DS, Girish M, Subramaniam. Refractory Kawasaki disease: infliximab or methotrexate therapy? *Indian J Pediatr* 2009;76:1184.
- Parashette KR, Makam RC, Cuffari C. Infliximab therapy in pediatric Crohn's disease: a review. *Clin Exp Gastroenterol* 2010;3:57-63.
- Matsubara T, Furukawa S, Yabuta K. Serum levels of tumor necrosis factor, interleukin 2 receptor, and interferon-gamma in Kawasaki disease involved coronary-artery lesions. *Clin Immunol Immunopathol* 1990;56:29-36.
- Burns JC, Best BM, Mejias A, Mahony L, Fixler DE, Jafri HS, et al. Infliximab treatment of intravenous immunoglobulin-resistant Kawasaki disease *J Pediatr* 2008;153:833-8.
- Mori M, Imagawa T, Hara R, Kikuchi M, Hara T, Nozawa T, et al. Efficacy and limitation of infliximab treatment for children with Kawasaki disease intractable to intravenous immunoglobulin therapy: report of an open-label case series. *J Rheumatol* 2012;39:864-7.
- Maini RN, Taylor PC. Anti-cytokine therapy for rheumatoid arthritis. *Annu Rev Med* 2000;51:207-29.
- Miyamoto H, Miura T, Morita E, Morizaki Y, Uehara K, Ohe T, et al. Fungal arthritis of the wrist caused by *Candida parapsilosis* during infliximab therapy for rheumatoid arthritis. *Mod Rheumatol* 2012;22:903-6.
- Keane J, Gershon S, Wise RP, Mirabile-Levens E, Kasznica J, Schwieterman WD, et al. Tuberculosis associated with infliximab, a tumor necrosis factor alpha-neutralizing agent. *N Engl J Med* 2001;345:1098-104.
- Kroesen S, Widmer AF, Tyndall A, Hasler P. Serious bacterial infections in patients with rheumatoid arthritis under anti-TNF-alpha therapy. *Rheumatology (Oxford)* 2003;42:617-21.
- Stratakos G, Kalomenidis I, Papas V, Malagari K, Kollintza A, Roussos C, et al. Cough and fever in a female with Crohn's disease receiving infliximab. *Eur Respir J* 2005;26:354-7.
- Leung DY, Meissner C, Fulton D, Schlievert PM. The potential role of bacterial superantigens in the pathogenesis of Kawasaki syndrome. *J Clin Immunol* 1995;15:11S-7S.
- Bergogne BE, Towner K. *Acinetobacter* spp. as nosocomial pathogens: Microbiological, clinical, and epidemiologic features. *Clin Microbiol Rev* 1996;9:148-65.
- Bruns H, Meinken C, Schauenberg P, Harter G, Kern P, Modlin RL, et al. Anti-TNF immunotherapy reduces CD8+ T cell-mediated antimicrobial activity against *Mycobacterium tuberculosis* in humans. *J Clin Invest* 2009;119:1167-77.