

Minimal Invasive Coronary Artery Fistula Ligation

Fotios A. Mitropoulos, M.D., Ph.D.¹, Meletios A. Kanakis, M.D., Ph.D.¹, Andrew Chatzis, M.D., Ph.D.¹, Constantinos Contrafouris, M.D., Ph.D.¹, Ioanna A. Sofianidou, M.D.¹, Achilleas G. Lioulas, M.D., Ph.D.²

A coronary artery fistula was surgically ligated in a 38-year-old woman via a left anterior mini-thoracotomy without the use of cardiopulmonary bypass. In selected cases, this surgical approach can provide an excellent surgical exposure for coronary artery fistula ligation. It also offers an excellent cosmetic result and shorter hospital stay.

Key words: 1. Coronary artery
2. Minimally invasive surgery
3. Thoracotomy
4. Congenital

CASE REPORT

A 38-year-old woman presented with a six-month history of progressive exertional dyspnea and a new onset of syncope episodes. Auscultation revealed a continuous murmur at the left sternal border. The rest of the clinical examination and laboratory workup was unremarkable. Transthoracic echocardiography showed an anomalous vascular structure originating from the circumflex artery and draining to the main pulmonary artery with a significant left to right shunt, mild dilatation of the right heart chambers, and a 60% ejection fraction. Magnetic resonance imaging and coronary angiography confirmed the presence of a coronary artery fistula (Fig. 1). The pulmonary to systemic flow ratio was calculated as 1.8 to 1. Transcatheter closure was not feasible due to the absence of an appropriate neck and the patient was therefore referred for surgical correction.

A left anterior mini-thoracotomy (5 cm) was performed and

the thoracic cavity was entered via the third intercostal space. With the left lung deflated, the left phrenic nerve was identified; the pericardium was then incised and suspended to the margins of the incision. The exposure was excellent and the fistulous tracts were identified (Fig. 2A). The fistula on the pulmonary artery side was obliterated with multiple pledgeted 5-0 polypropylene sutures (Fig. 2B). Transesophageal echocardiography confirmed the successful closure of the fistula, the lack of a residual shunt, and the lack of wall motion abnormalities, while the electrocardiogram did not show any signs of ischemia. The patient was extubated one hour after the completion of the procedure in the intensive care unit and was then transferred to the general ward. She was discharged on the second postoperative day. At six and twelve months follow-up, she remained free of any cardiovascular symptoms, while echocardiography showed no residual flow. Moreover, an excellent cosmetic result was achieved.

¹Department of Pediatric and Congenital Heart Surgery, Onassis Cardiac Surgery Center, ²Department of Thoracic Surgery, Sismanoglio General Hospital of Athens

Received: January 14, 2014, Revised: April 16, 2014, Accepted: April 16, 2014, Published online: December 5, 2014

Corresponding author: Meletios A. Kanakis, Department of Pediatric and Congenital Heart Surgery, Onassis Cardiac Surgery Center, Syngrou Avenue 356, Kallithea, Athens 17674, Greece

(Tel) 30-210-9493000 (Fax) 30-210-2433431 (E-mail) meletis_kanakis@yahoo.gr

© The Korean Society for Thoracic and Cardiovascular Surgery. 2014. All right reserved.

© This is an open access article distributed under the terms of the Creative Commons Attribution Non-Commercial License (<http://creativecommons.org/licenses/by-nc/3.0>) which permits unrestricted non-commercial use, distribution, and reproduction in any medium, provided the original work is properly cited.

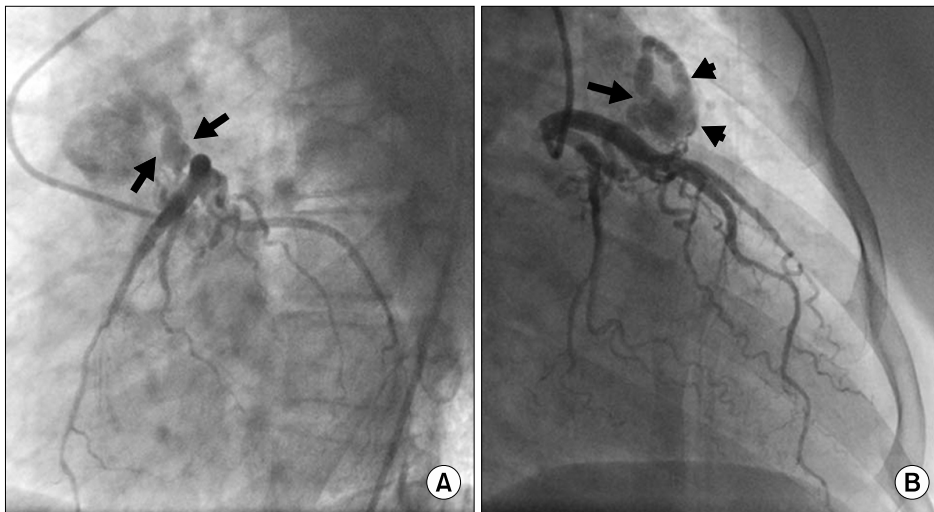


Fig. 1. Coronary arteriography depicting (A) the fistula originating from the circumflex artery and (B) draining into the main pulmonary artery (arrows).

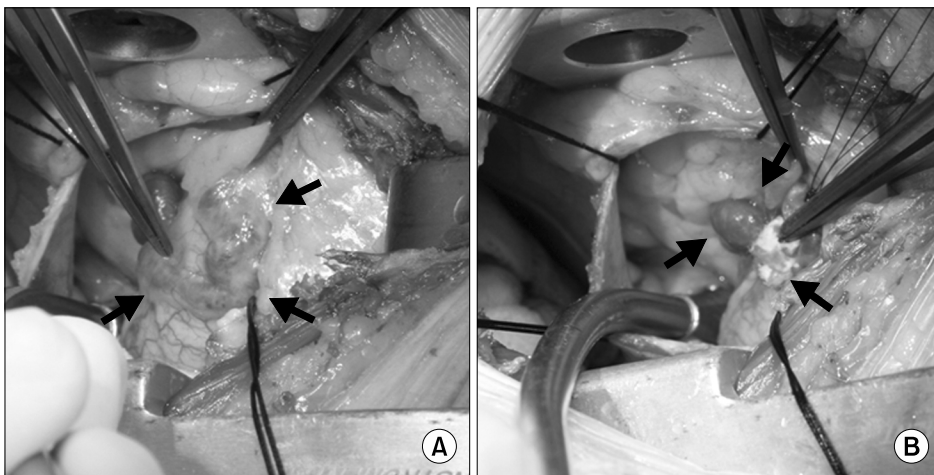


Fig. 2. Intraoperative photo showing (A) the fistulous tract (arrows) and (B) multiple pledgeted 5-0 polypropylene sutures occluding the fistula on the pulmonary artery side (arrows).

DISCUSSION

A coronary artery fistula is a mostly congenital, abnormal communication between a coronary artery or its branches and another cardiovascular structure. Several variations have been described. Most commonly, it originates from the right coronary artery (60%) followed by the left coronary artery (35%). It usually drains into the right heart chambers: most commonly the right ventricle (40%), followed by the right atrium (25%), the pulmonary artery (15%-20%), and the coronary sinus (7%) [1]. It can also be acquired by iatrogenic and non-iatrogenic trauma, infectious diseases, as a result of transcatheter catheter intervention, or as a clinical complication of Kawasaki disease [2]. These fistulae may increase in size

and cause symptoms, heart failure, or potentially lethal complications. Current treatment includes surgical ligation alone or accompanied by coronary artery bypass grafting with or without cardiopulmonary bypass support, or, alternatively, transcatheter closure [2,3].

Although the surgical correction of coronary artery fistulae is a fairly common procedure, we believe our presented case is the first reported case of surgical ligation of a coronary fistula via a left anterior mini-thoracotomy. This approach, known as the Chamberlain procedure, is a well-established technique in thoracic surgery and offers a reliable method for obtaining a tissue diagnosis in anterosuperior mediastinal masses. In cardiac surgery, the typical left anterior thoracotomy has an established role in repeated mitral valve sur-

gery [4-6], and its use for aortic valve replacement has also been described [7]. A left thoracotomy has also been used in mitral valve surgery as a minimal access approach and as an alternative for redoing cardiac surgery when a previous median sternotomy has been performed [8,9]. Its use has also recently been described for pulmonary valve replacement [6].

Using this approach in conjunction with double lumen tracheal intubation, an excellent surgical exposure of the anterior and left heart surface can be achieved. Although it was not necessary in our case, cardiovascular bypass could be established in this procedure. Although, it was not necessary in our case, cardiopulmonary bypass could be established through the aorta for arterial cannulation and the femoral vein for venous cannulation.

A left anterior mini-thoracotomy can provide an excellent surgical exposure for coronary artery fistula ligation in certain cases. It is a safe alternative with excellent cosmetic results and may minimize hospitalization time.

CONFLICT OF INTEREST

No potential conflict of interest relevant to this article was reported.

REFERENCES

1. Kouchoukos NT, Blackstone EH, Doty DB, Hanley FL, Karp RB. *Congenital anomalies of the coronary arteries: coronary arteriovenous fistula*. In: Kouchoukos NT, Blackstone EH, Doty DB, Hanley FL, Karp RB, editors. *Kirklin/Barratt-Boyes cardiac surgery*. 3rd ed. Philadelphia: Churchill Livingstone; 2003. p. 1240-7.
2. Mangukia CV. *Coronary artery fistula*. *Ann Thorac Surg* 2012;93:2084-92.
3. Mitropoulos FA, Kanakis MA, Davlouros PA, Triantis G. *Congenital left main coronary artery to coronary sinus fistula*. *Heart Surg Forum* 2011;14:E255-7.
4. Suzuki Y, Pagani FD, Bolling SF. *Left thoracotomy for multiple-time redo mitral valve surgery using on-pump beating heart technique*. *Ann Thorac Surg* 2008;86:466-71.
5. Crooke GA, Schwartz CF, Ribakove GH, et al. *Retrograde arterial perfusion, not incision location, significantly increases the risk of stroke in reoperative mitral valve procedures*. *Ann Thorac Surg* 2010;89:723-9.
6. Barnard J, Hoschtitzky A, Hasan R. *Pulmonary valve replacement through a left thoracotomy approach*. *Ann Thorac Surg* 2012;93:306-8.
7. Barreda T, Laali M, Dorent R, Acar C. *Left thoracotomy for aortic and mitral valve surgery in a case of mediastinal displacement due to pneumonectomy*. *J Heart Valve Dis* 2008;17:239-42.
8. Saunders PC, Grossi EA, Sharony R, et al. *Minimally invasive technology for mitral valve surgery via left thoracotomy: experience with forty cases*. *J Thorac Cardiovasc Surg* 2004;127:1026-31.
9. Kim DC, Chee HK, Song MG, et al. *Comparative analysis of thoracotomy and sternotomy approaches in cardiac reoperation*. *Korean J Thorac Cardiovasc Surg* 2012;45:225-9.