

# Analysis and evaluation of relative positions of mandibular third molar and mandibular canal impacts

Hang-Gul Kim, Jae-Hoon Lee

Department of Oral and Maxillofacial Surgery, College of Dentistry, Dankook University, Cheonan, Korea

**Abstract** (J Korean Assoc Oral Maxillofac Surg 2014;40:278-284)

**Objectives:** This study used cone-beam computed tomography (CBCT) images to categorize the relationships between the mandibular canal and the roots and investigated the prevalence of nerve damage.

**Materials and Methods:** Through CBCT images, contact and three-dimensional positional relationships between the roots of the mandibular third molar and the mandibular canal were investigated. With this data, prevalence of nerve damage according to the presence of contact and three-dimensional positional relationships was studied. Other factors that affected the prevalence of nerve damage were also investigated.

**Results:** When the mandibular third molar and the mandibular canal were shown to have direct contact in CBCT images, the prevalence of nerve damage was higher than in other cases. Also, in cases where the mandibular canal was horizontally lingual to the mandibular third molar and the mandibular canal was vertically at the cervical level of the mandibular third molar, the prevalence of nerve damage was higher than in opposite cases. The percentage of mandibular canal contact with the roots of the mandibular third molar was higher when the mandibular canal was horizontally lingual to the mandibular third molar. Finally, the prevalence of nerve damage was higher when the diameter of the mandibular canal lumen suddenly decreased at the contact area between the mandibular canal and the roots, as shown in CBCT images.

**Conclusion:** The three-dimensional relationship of the mandibular third molar and the mandibular canal can help predict nerve damage and can guide patient expectations of the possibility and extent of nerve damage.

**Key words:** Paresthesia, Mandibular nerve, Third molars

[paper submitted 2014. 7. 29 / revised 1st 2014. 9. 3, 2nd 2014. 9. 5 / accepted 2014. 9. 10]

## I. Introduction

Extraction of the mandibular third molar is the most widely performed oral and maxillofacial surgery. However, one of the severe complications of this surgery is damage to the inferior alveolar nerve<sup>1,2</sup>, causing dysesthesia or paresthesia, in 0.4%<sup>3</sup> to 13.4%<sup>4</sup> of cases. Damage to the inferior alveolar nerve occurs most frequently when the root of mandibular third molar and the nerve are in direct contact<sup>2,5</sup>. Additionally, patient age, surgical technique, and surgeon experience

may influence the prevalence of complications<sup>6,7</sup>.

Recently, cone-beam computed tomography (CBCT) has become an important tool in oral and maxillofacial radiology because it is more economic and causes less radiation exposure than conventional computed tomography (CT). Though CBCT is more expensive and causes more radiation exposure than panoramic radiography, it is applied widely due to its three-dimensional capability. In particular, when the mandibular third molar and the mandibular canal are adjacent, CBCT is able to visualize the buccolingual position, curvature and number of roots, the distance and location from the mandibular canal, the loss of cortical layer of the mandibular canal, and the direction of the mandibular canal<sup>8-12</sup>.

However, studies involving cases from which to evaluate the prevalence of nerve damage are insufficient. In addition, few studies demonstrate the prevalence of nerve damage according to the positional relationships of the two structures or the shapes of the roots or the mandibular canal.

This study discusses clinical complications experienced

---

### Jae-Hoon Lee

Department of Oral and Maxillofacial Surgery, College of Dentistry, Dankook University, 119 Dandae-ro, Dongnam-gu, Cheonan 330-714, Korea  
TEL: +82-41-550-0271 FAX: +82-41-551-8988  
E-mail: Lee201@dku.edu

©This is an open-access article distributed under the terms of the Creative Commons Attribution Non-Commercial License (<http://creativecommons.org/licenses/by-nc/3.0/>), which permits unrestricted non-commercial use, distribution, and reproduction in any medium, provided the original work is properly cited.

Copyright © 2014 The Korean Association of Oral and Maxillofacial Surgeons. All rights reserved.

---

The present research was conducted by the research fund of Dankook University in 2014.

after extraction of the mandibular third molar from patients who had overlapping panoramic radiography views of the root of the mandibular third molar and the mandibular canal. The positional relationship between the mandibular third molar and the mandibular canal was analyzed radiographically, and the influence on the damage to the inferior alveolar nerve was also studied. Moreover, the prevalence of nerve damage according to the shapes of the roots of the mandibular canal were studied.

## II. Materials and Methods

### 1. Materials

From 2012 to 2013, patients who visited Dankook University Dental Hospital (Cheonan, Korea) for mandibular third molar extraction were evaluated, and the patients with an overlapped panoramic radiography view of the root of the mandibular third molar and the mandibular canal were included in this study. Cases with cysts or tumors of the mandible were excluded. A total of 224 CBCT images of the mandibular third molar were included in this study. The institutional review board of Dankook University Dental Hospital approved the design of this retrospective cohort study.

The CBCT machine used in this study was a PHT-60FO model (VATECH Corp., Hwaseong, Korea), and mandibular third molars were exposed at 80 kV and 2 mA for 17 seconds. Images were processed using 3DX software (Mortita, Kyoto, Japan) and evaluated through light emitting diode monitors.

### 2. Methods

#### 1) CBCT evaluation of the mandibular third molar

The following aspects were investigated using the CBCT images of 224 mandibular third molars: (1) Impaction depth (partial or entire), (2) number of roots (1, 2, >2), (3) shape and curvature of mesial and distal roots (straight, buccal, lingual, distal, mesial), (4) proximity of the roots and the mandibular canal, and (5) horizontal and vertical positional relationships between the roots and the mandibular canal.

#### 2) Evaluation of nerve damage prevalence according to roots and mandibular canal proximity

To determine how contact between the roots of the mandibular third molar and the mandibular canal influenced the prevalence of loss of sensory nerve function, two groups were created according to the CBCT images: group 1, no

contact between the roots of the mandibular third molar and the mandibular canal, with a separating cortex layer; group 2, contact between the roots of the mandibular third molar and the mandibular canal, without a separating cortex layer.

Logistic regression analyses were used for statistical purposes. The results were statistically significant when the *P*-value was less than 0.001.

#### 3) Evaluation of nerve damage prevalence according to the horizontal and vertical positional relationships between the roots and the mandibular canal

The relationships between the roots of the mandibular third molar and the mandibular canal, based on CBCT images, were used to evaluate nerve damage prevalence according to the horizontal and vertical positions. The location of the mandibular canal to the mandibular third molar was categorized horizontally (buccal, apical, lingual) and vertically (apical one-third, middle one-third, cervical one-third). The prevalence of nerve damage according to the positional relationships was investigated. The Pearson chi-square test was used for statistical purposes.

#### 4) Contact between the mandibular third molar and mandibular canal according to buccolingual position

The buccolingual relations of the roots of the mandibular third molar and the mandibular canal and the contact between the mandibular third molar and the mandibular canal were studied to investigate the variations in the prevalence of nerve damage according to the buccolingual position of the mandibular canal based on CBCT images. Fisher's exact test was used for statistical analysis.

#### 5) Evaluation of other variables that caused nerve damage when there was direct contact between the mandibular third molar and the mandibular canal

Tooth-related variables and nerve canal-related variables were studied separately to investigate other variables that caused nerve damage when there was direct contact between the mandibular third molar and the mandibular canal.

Tooth-related variables included age, gender, and buccal or oral bending of the distal root. Nerve canal-related variables included age, gender, diameter of the canal lumen, root bending inside the canal, and contact area between the root and the canal. IBM SPSS Statistics version 19.0 (IBM Co., Armonk, NY, USA) was used for statistical analysis.

### III. Results

#### 1. CBCT evaluation of the mandibular third molar

The results of impaction depth, number of roots, shape and curvature of mesial and distal roots, proximity of the roots and the mandibular canal, and horizontal and vertical positional relationships between the roots and the mandibular canal from 224 mandibular third molars based on CBCT were as follows. The majority of teeth were partially impacted and had two roots. Twenty-one teeth (9.3%) had their distal roots curved in the buccolingual direction, and 71 teeth (31.7%) were in contact with the mandibular canal. Finally, the man-

**Table 1.** Distribution of tooth-related variables as observed in cone-beam computed tomography in relation to surgical interventions (n=224)

Parameter	No. of teeth
State of impaction	
Impacted	16
Partially impacted	208
Number of roots	
1	23
2	166
>2	35
Distal root bending	
Yes	73
No	151
Distal root, buccal or oral bending	
Yes	21
No	203
Distal root, mesial or distal bending	
Yes	89
No	135
Mesial root bending	
Yes	106
No	118
Mesial root, buccal or oral bending	
Yes	22
No	202
Mesial root, mesial or distal bending	
Yes	170
No	54
Direct contact with the canal	
Yes	71
No	153
Position of IAC in relation to MTM	
Horizontal	
Buccal	108
Apical	57
Lingual	59
Vertical	
Apical one-third	158
Middle one-third	62
Cervical one-third	4

(IAC: inferior alveolar canal, MTM: mandibular third molar)  
 Hang-Gul Kim et al: Analysis and evaluation of relative positions of mandibular third molar and mandibular canal impacts. J Korean Assoc Oral Maxillofac Surg 2014

dibular canal tended to be on the buccal side (48.2%) rather than the lingual side (26.3%) or at the apex (25.4%) relative to the roots of the mandibular third molar.(Table 1)

#### 2. Nerve damage prevalence according to the proximity of the roots and mandibular canal

CBCT images of 224 teeth were studied. In all, 11 teeth (4.9%) experienced nerve damage that affected the inferior alveolar nerve. Only one patient in group 1 had nerve damage, while 10 patients in group 2 experienced nerve damage in the absence of a cortex layer. The prevalence of paresthesia when the roots of the mandibular third molar contacted the mandibular canal was 21 times greater than that of cases without contact. In conclusion, the presence of contact between the two structures greatly influenced resulting nerve damage.(Table 2)

#### 3. Nerve damage prevalence according to the horizontal and vertical positional relationships between the roots and the mandibular canal

The prevalence of nerve damage according to the horizontal and vertical positional relationships between the roots and the mandibular canal is shown.(Fig. 1) Horizontally, the prevalence was higher when the mandibular canal was lingual to the roots of the mandibular third molar. Vertically, the prevalence was higher as the depth of the mandibular third molar increased relative to the mandibular canal.(Table 3)

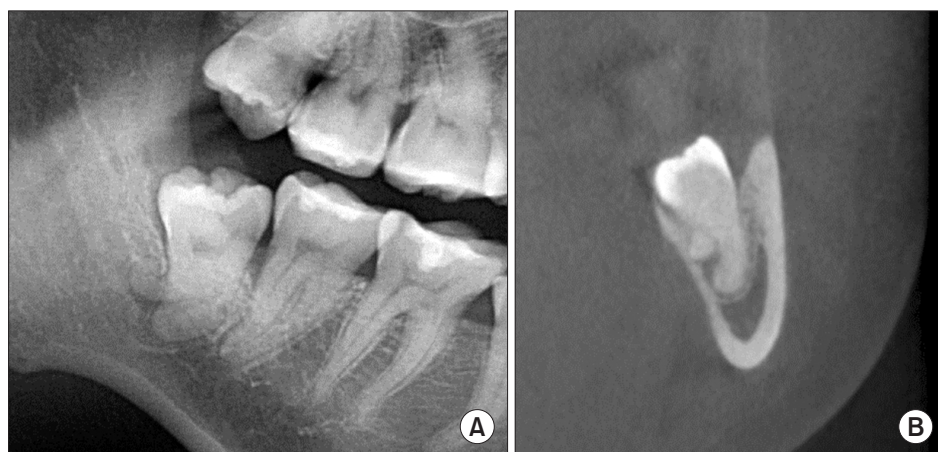
#### 4. Investigation of the contact between the mandibular third molar and mandibular canal according to the buccolingual position

The possibility of contacting the roots was higher when the

**Table 2.** Prevalence and relative risk of paresthesia according to the cortical integrity of the inferior alveolar canal (IAC)

Cortical integrity of the IAC	No. of teeth		P-value
	With paresthesia	Healthy	
Intact (group 1)	1	153	<0.001
Disrupted (group 2)	10	71	

Relative risk, 21.5; 95% confidence interval, 2.7-157.  
 Group 1: no contact between the roots of the mandibular third molar and the mandibular canal, with a separating cortex layer. Group 2: contact between the roots of the mandibular third molar and the mandibular canal, without a separating cortex layer.  
 Hang-Gul Kim et al: Analysis and evaluation of relative positions of mandibular third molar and mandibular canal impacts. J Korean Assoc Oral Maxillofac Surg 2014



**Fig. 1.** Radiographic images of a patient with paresthesia. A. A panoramic radiographic image shows the roots of the mandibular third molar overlapping the mandibular canal. B. The roots show lingual bending, and the continuity of the canal of the inferior alveolar nerve is lost.

Hang-Gul Kim et al: Analysis and evaluation of relative positions of mandibular third molar and mandibular canal impacts. *J Korean Assoc Oral Maxillofac Surg* 2014

**Table 3.** Prevalence of paresthesia and position of the IAC in relation to the MTM

Position of IAC in relation to MTM	Affected teeth, n (%)	Teeth with paresthesia, n (%)	No. of teeth in each group		P-value <sup>1</sup>
			Intact	Disrupted	
<b>Horizontal</b>					
Buccal	108 (48.2)	2 (1.9)	0	2	0.018
Apical	57 (25.4)	2 (3.5)	1	1	
Lingual	59 (26.3)	7 (11.9)	0	7	
<b>Vertical</b>					
Apical one-third	158 (70.5)	6 (3.8)	1	5	0.027
Middle one-third	62 (27.7)	4 (6.5)	0	4	
Cervical one-third	4 (1.8)	1 (25)	0	1	

(IAC: inferior alveolar canal, MTM: mandibular third molar)

<sup>1</sup>Pearson's chi-square test.

Hang-Gul Kim et al: Analysis and evaluation of relative positions of mandibular third molar and mandibular canal impacts. *J Korean Assoc Oral Maxillofac Surg* 2014

**Table 4.** Relationship between the buccolingual position and proximity of the canal

	Separate from canal, n (%)	Contact with canal, n (%)	Total (n)
Buccal	91 (59.5)	17 (23.9)	108
Apical	54 (35.3)	3 (4.2)	57
Lingual	8 (5.2)	51 (71.8) <sup>1</sup>	59
Total	153 (100)	71 (100)	224

<sup>1</sup>Fisher's exact test; P<0.01.

Hang-Gul Kim et al: Analysis and evaluation of relative positions of mandibular third molar and mandibular canal impacts. *J Korean Assoc Oral Maxillofac Surg* 2014

mandibular canal was located more lingual than the mandibular third molar. In 51 of the cases (71.8%) where the mandibular canal was lingually positioned, the nerve and roots had contact with each other. When the mandibular canal was buccally positioned, 17 cases (23.9%) showed no contact between the nerve and the roots. In this respect, there is an

**Table 5.** Multivariate logistic regression analysis for tooth-related factors for paresthesia prevalence

Parameter	Direct contact (n=71)	
	Odds ratio	P-value
Gender (male vs. female)	1.0	>0.05
Age (ascending)	1.1	>0.05
Distal root, buccal/oral bending (no bending vs. yes)	13.3	>0.05

Hang-Gul Kim et al: Analysis and evaluation of relative positions of mandibular third molar and mandibular canal impacts. *J Korean Assoc Oral Maxillofac Surg* 2014

increased likelihood of contact with the nerve canal when the mandibular canal is lingually positioned, and as a result, there is a greater possibility of nerve damage.(Table 4)

- Evaluation of other variables that caused nerve damage when there was direct contact between the mandibular third molar and the mandibular canal

Other variables that caused nerve damage were studied, with the exception of direct contact between the mandibular third molar and the mandibular canal. For tooth-related variables, the possibility of nerve damage was high if the patient was aged or the distal root was curved buccolingually, but the value was not statistically significant.(Table 5) The differences among the nerve canal-related variables of gender, age, root bending inside the canal, and the contact area between the root and the canal were not statistically significant. However, the possibility of nerve damage was high when the diameter of the canal lumen at the contact area between the root and the canal decreased, and this value was statistically significant. Therefore, a decrease in canal lumen contact with the root is related to the degree of nerve damage after extraction.(Table 6)

**Table 6.** Multivariate logistic regression analysis for canal-related factors for paresthesia prevalence

Parameter	Direct contact (n=71)	
	Odds ratio	P-value
Gender (male vs. female)	0.6	>0.05
Age (ascending)	1.1	>0.05
Diameter of the canal lumen (constant)		
>1/2 the diameter	62.1	<0.05
≤1/2 the diameter	43.6	<0.05
Canal in root bending (no vs. yes)	32.8	>0.05
Contact area between root and canal (root length: <1/2 vs. ≥1/2)	1.1	>0.05

Hang-Gul Kim et al: Analysis and evaluation of relative positions of mandibular third molar and mandibular canal impacts. J Korean Assoc Oral Maxillofac Surg 2014

#### IV. Discussion

Extraction of the mandibular third molar is one of the most common oral and maxillofacial surgeries. Complications such as hemorrhage, infection, edema, trismus, alveolar osteitis, ecchymosis, and nerve damage can occur after surgery. A number of clinicians have studied if additional CBCT before mandibular third molar extraction could decrease the prevalence of postoperative complications. Susarla and Dodson<sup>13</sup> suggested that additional information provided by CBCT images could decrease the prevalence of paresthesia.

Numerous studies on the diagnostic usefulness of CBCT for mandibular third molar extraction have been reported<sup>5,14,15</sup>. Suomalainen et al.<sup>9</sup> suggested that CBCT is more reliable than panoramic radiography for evaluating the number of roots. In addition, it has been reported that CBCT is more effective than panoramic radiography for determining the shape or the number of roots, which can be difficult to determine<sup>11</sup>. With these anatomic data, surgical confidence with regard to complete extraction of the roots of the mandibular third molar can be increased. This increased confidence can lead to reduced surgical times and might further decrease postoperative complications. Most teeth in this study were partially impacted and had two roots, important factors in surgery. Additionally, the mandibular canal was primarily located buccal (48.2%) to the mandibular third molar. This resembles the data reported by Kaeppler<sup>16</sup> when they studied 234 mandibular third molars and determined that the mandibular canal was buccal to 136 teeth (53.6%), was between the roots in 93 teeth (26.8%), was lingual side to 45 teeth (13.0%), and was below the roots in 21 teeth (6.0%). However, Tantanapornkul et al.<sup>8</sup> reported that the mandibular canal was located below the mandibular third molar in 64 of 142 teeth (45%), lingual to 37 teeth (26%), buccal to 36 teeth (25%), and between the

roots in five teeth (4%).

Maegawa et al.<sup>17</sup> analyzed the horizontal and vertical positional relationships between 47 mandibular third molars and the mandibular canal using CT images and concluded that the cortical integrity of the mandibular canal is related to nerve damage. Tantanapornkul et al.<sup>8</sup> evaluated 142 teeth and suggested that the prevalence of nerve damage is higher if there is direct contact between the mandibular third molar and the mandibular canal. In addition, Nakamori et al.<sup>18</sup> reported that a separating cortex layer of the mandibular canal is a critical factor in postoperative nerve damage. In this study of 224 teeth with additional CBCT images, 11 teeth experienced paresthesia after extraction, 10 teeth of which had direct contact between the roots of the mandibular third molar and the mandibular canal. Absence of cortical integrity of the mandibular canal in CBCT images suggests direct contact between the mandibular third molar and the inferior alveolar nerve and damage or exposure of the nerve after extraction. There is a greater possibility of nerve damage and cortex layer disruption if there is direct contact between the mandibular third molar and the mandibular canal, because of the force that is exerted on the teeth and the movements during surgery. Consequently, the cortical integrity of the mandibular canal is an important factor for postoperative nerve damage. Although the nerve damage in this study was temporary, this post-surgical complication can be stressful for the operating surgeons. Therefore, it is important to confirm any contact between the two structures before an extraction. CBCT is a good tool to assure such contact.

Determination of the exact location of the mandibular canal illustrates the safe region for removing bone for extraction and the hazardous region that requires surgical caution<sup>19</sup>. The inferior alveolar nerve is exposed more often when the mandibular canal is located lingual to the roots of the mandibular third molar<sup>20</sup>. This study determined that the prevalence of nerve damage was higher when the mandibular canal was located at the lingual side rather than at the buccal side of the tooth of interest. Therefore, if the mandibular canal is located at the lingual side of the mandibular third molar, the crown can be located lingually in order to rotate the tooth opposite to the mandibular canal and prevent nerve damage<sup>21</sup>. In this study, the cortical integrity of the mandibular canal was more likely to be lost when the inferior alveolar nerve was located at the lingual side, and contact between the mandibular canal and the teeth was present more often at the lingual side than the buccal side.

Never damage does not always occur, even when the man-

dibular third molar and the mandibular canal contact each other. One study reported a high prevalence of paresthesia when the diameter of the canal lumen decreases near the location of the roots of the mandibular third canal and where there is contact with the mandibular canal based on CBCT images<sup>19</sup>. Additionally, Mahasantipiya et al.<sup>15</sup> analyzed 202 mandibular third molars with CBCT images and suggested that the change in diameter of the canal lumen is related to the prevalence of nerve damage. In this study, paresthesia after the extraction increased significantly when the diameter of the canal lumen decreased.

This study investigated the relationship of the mandibular third molar and the mandibular canal as shown in CBCT images and the correlation with postoperative complications, especially nerve damage. Even though CBCT images cannot significantly prevent complications after extractions compared with panoramic radiograph images, evaluating the contacts between the mandibular third molar and the mandibular canal using CBCT images and the changes in the diameter of the canal lumen can be effective for predicting the extent of nerve damage prior to surgery. Of the 224 teeth in this study evaluated with CBCT images, only 11 experienced temporary nerve damage. However, this is a serious complication for patients and a great postoperative burden for surgeons. Consequently, this study provides useful information for clinicians about evaluating risk factors for postoperative complications and nerve damage using CBCT images.

## V. Conclusion

Panoramic radiograph images indicate that, when the mandibular third molar and the mandibular canal are in direct contact, it is critical to determine the exact positional relationship of the two structures with CBCT images. The presence of contact between the mandibular third molar and the mandibular canal in CBCT images was determined to be related to the degree of nerve damage. The frequency of roots that contacted the mandibular canal was higher when the mandibular canal was lingual to the mandibular third molar, and consequently, the prevalence of nerve damage was higher. Additionally, the analysis indicated that a decrease in the diameter of the canal lumen at the contact area affected the prevalence of nerve damage. In conclusion, CBCT can be valuable for determining the three-dimensional relationship of the mandibular third molar and the mandibular canal; this can allow operating surgeons to explain the possibility and extent of nerve damage to prospective patients.

## Conflict of Interest

No potential conflict of interest relevant to this article was reported.

## References

1. Robinson PP, Loescher AR, Yates JM, Smith KG. Current management of damage to the inferior alveolar and lingual nerves as a result of removal of third molars. *Br J Oral Maxillofac Surg* 2004;42:285-92.
2. Kipp DP, Goldstein BH, Weiss WW Jr. Dysesthesia after mandibular third molar surgery: a retrospective study and analysis of 1,377 surgical procedures. *J Am Dent Assoc* 1980;100:185-92.
3. Cheung LK, Leung YY, Chow LK, Wong MC, Chan EK, Fok YH. Incidence of neurosensory deficits and recovery after lower third molar surgery: a prospective clinical study of 4338 cases. *Int J Oral Maxillofac Surg* 2010;39:320-6.
4. Lopes V, Mumenya R, Feinmann C, Harris M. Third molar surgery: an audit of the indications for surgery, post-operative complaints and patient satisfaction. *Br J Oral Maxillofac Surg* 1995;33:33-5.
5. Monaco G, Montecchi M, Bonetti GA, Gatto MR, Checchi L. Reliability of panoramic radiography in evaluating the topographic relationship between the mandibular canal and impacted third molars. *J Am Dent Assoc* 2004;135:312-8.
6. Güllicher D, Gerlach KL. Sensory impairment of the lingual and inferior alveolar nerves following removal of impacted mandibular third molars. *Int J Oral Maxillofac Surg* 2001;30:306-12.
7. Jerjes W, Upile T, Shah P, Nhembe F, Gudka D, Kafas P, et al. Risk factors associated with injury to the inferior alveolar and lingual nerves following third molar surgery-revisited. *Oral Surg Oral Med Oral Pathol Oral Radiol Endod* 2010;109:335-45.
8. Tantanapornkul W, Okouchi K, Fujiwara Y, Yamashiro M, Maruoka Y, Ohbayashi N, et al. A comparative study of cone-beam computed tomography and conventional panoramic radiography in assessing the topographic relationship between the mandibular canal and impacted third molars. *Oral Surg Oral Med Oral Pathol Oral Radiol Endod* 2007;103:253-9.
9. Suomalainen A, Ventä I, Mattila M, Turtola L, Vehmas T, Peltola JS. Reliability of CBCT and other radiographic methods in preoperative evaluation of lower third molars. *Oral Surg Oral Med Oral Pathol Oral Radiol Endod* 2010;109:276-84.
10. Rood JP, Shehab BA. The radiological prediction of inferior alveolar nerve injury during third molar surgery. *Br J Oral Maxillofac Surg* 1990;28:20-5.
11. Flygare L, Ohman A. Preoperative imaging procedures for lower wisdom teeth removal. *Clin Oral Investig* 2008;12:291-302.
12. Susarla SM, Sidhu HK, Avery LL, Dodson TB. Does computed tomographic assessment of inferior alveolar canal cortical integrity predict nerve exposure during third molar surgery? *J Oral Maxillofac Surg* 2010;68:1296-303.
13. Susarla SM, Dodson TB. Preoperative computed tomography imaging in the management of impacted mandibular third molars. *J Oral Maxillofac Surg* 2007;65:83-8.
14. Ohman A, Kivijärvi K, Blombäck U, Flygare L. Pre-operative radiographic evaluation of lower third molars with computed tomography. *Dentomaxillofac Radiol* 2006;35:30-5.
15. Mahasantipiya PM, Savage NW, Monsour PA, Wilson RJ. Narrowing of the inferior dental canal in relation to the lower third molars. *Dentomaxillofac Radiol* 2005;34:154-63.
16. Kaeppler G. Conventional cross-sectional tomographic evaluation of mandibular third molars. *Quintessence Int* 2000;31:49-56.
17. Maegawa H, Sano K, Kitagawa Y, Ogasawara T, Miyauchi K, Sekine J, et al. Preoperative assessment of the relationship between the mandibular third molar and the mandibular canal by axial com-

- puted tomography with coronal and sagittal reconstruction. *Oral Surg Oral Med Oral Pathol Oral Radiol Endod* 2003;96:639-46.
18. Nakamori K, Fujiwara K, Miyazaki A, Tomihara K, Tsuji M, Nakai M, et al. Clinical assessment of the relationship between the third molar and the inferior alveolar canal using panoramic images and computed tomography. *J Oral Maxillofac Surg* 2008;66:2308-13.
  19. Eyrich G, Seifert B, Matthews F, Matthiessen U, Heusser CK, Kruse AL, et al. 3-Dimensional imaging for lower third molars: is there an implication for surgical removal? *J Oral Maxillofac Surg* 2011;69:1867-72.
  20. Jhamb A, Dolas RS, Pandilwar PK, Mohanty S. Comparative efficacy of spiral computed tomography and orthopantomography in preoperative detection of relation of inferior alveolar neurovascular bundle to the impacted mandibular third molar. *J Oral Maxillofac Surg* 2009;67:58-66.
  21. Ghaemina H, Meijer GJ, Soehardi A, Borstlap WA, Mulder J, Vlijmen OJ, et al. The use of cone beam CT for the removal of wisdom teeth changes the surgical approach compared with panoramic radiography: a pilot study. *Int J Oral Maxillofac Surg* 2011;40:834-9.