

Three-dimensional evaluation of maxillary anterior alveolar bone for optimal placement of miniscrew implants

Jin Hwan Choi^a
Hyung Seog Yu^b
Kee Joon Lee^b
Young Chel Park^b

^aPrivate Practice, Seoul, Korea

^bDepartment of Orthodontics, College of Dentistry, Yonsei University, Seoul, Korea

Objective: This study aimed to propose clinical guidelines for placing miniscrew implants using the results obtained from 3-dimensional analysis of maxillary anterior interdental alveolar bone by cone-beam computed tomography (CBCT). **Methods:** By using CBCT data from 52 adult patients (17 men and 35 women; mean age, 27.9 years), alveolar bone were measured in 3 regions: between the maxillary central incisors (U1–U1), between the maxillary central incisor and maxillary lateral incisor (U1–U2), and between the maxillary lateral incisor and the canine (U2–U3). Cortical bone thickness, labio-palatal thickness, and interdental root distance were measured at 4 mm, 6 mm, and 8 mm apical to the interdental cemento-enamel junction (ICEJ). **Results:** The cortical bone thickness significantly increased from the U1–U1 region to the U2–U3 region ($p < 0.05$). The labio-palatal thickness was significantly less in the U1–U1 region ($p < 0.05$), and the interdental root distance was significantly less in the U1–U2 region ($p < 0.05$). **Conclusions:** The results of this study suggest that the interdental root regions U2–U3 and U1–U1 are the best sites for placing miniscrew implants into maxillary anterior alveolar bone. [Korean J Orthod 2014;44(2):54–61]

Key words: Cone-beam computed tomography, Upper incisor intrusion, Cortical bone thickness, Gummy smile, Miniscrew implant

Received May 26, 2013; Revised August 21, 2013; Accepted August 21, 2013.

Corresponding author: Hyung Seog Yu.
Professor, Dental Hospital of Yonsei University College of Dentistry, 50 Yonsei-ro, Seodaemun-gu, Seoul 120-752, Korea.
Tel +82-2-2228-3100 **e-mail** yumichael@yuhs.ac

The authors report no commercial, proprietary, or financial interest in the products or companies described in this article.

© 2014 The Korean Association of Orthodontists.

This is an Open Access article distributed under the terms of the Creative Commons Attribution Non-Commercial License (<http://creativecommons.org/licenses/by-nc/3.0>) which permits unrestricted non-commercial use, distribution, and reproduction in any medium, provided the original work is properly cited.

INTRODUCTION

Gummy smile appears most frequently among women aged 20–30 years.¹ With an increasing number of adult female orthodontic patients,^{2,3} corrective treatment for a gummy smile has become important in the field of orthodontics. The goals of orthodontic treatment are not limited to simply achieving even teeth and well-occluded maxillo-mandibular dental arches. Such treatment also aims to provide a beautiful smile line that harmonizes with the face.^{4,5} In recent years, the increasing emphasis on a beautiful smile has increased the interest in treating a gummy smile using anterior-teeth intrusion.

Most patients with a gummy smile show excessive vertical growth of the maxillary bone.^{6,7} Patients with vertically overdeveloped maxillae have not always had good results from treatment by tooth extraction; frequently, gum exposure is actually increased after such attempts at correction. In contrast, anterior tooth intrusion using a miniscrew implant can provide good results because the surgeon can control the degree of gum exposure.^{8–14}

Many studies have assessed cortical bone thickness in the molar and premolar areas and in the midpalatal area for placement of miniscrew implants.^{15–20} In addition, recent clinical research findings on treatment with mini-

screw implants at the maxillary anterior alveolar bone have been reported.^{8–14} However, there is limited basic anatomical research aimed at determining the optimal placement of miniscrew implants.

This study aimed to evaluate the quality of maxillary anterior alveolar bone toward the goal of optimal miniscrew implant placement. Clinical guidelines were developed by measuring cortical-bone and labio-palatal thickness and interdental root distance using cone-beam computed tomography (CBCT).

MATERIALS AND METHODS

Subjects

Diagnostic CBCT (Point 3D C mobi 500C; Pointnix, Seoul, Korea) was conducted for patients who visited the private dental clinic (Seoul, Korea) to receive orthodontic treatment. Inclusion criteria for this study were as follows: no maxillary anterior cross-bite observed in clinical or radiographic tests; maxillary anterior crowding less than 2–3 mm; no maxillary anterior loss or microdontia; maxillary anterior spacing within 2 mm; completion of growth without orthodontic treatment; and no moderate or severe periodontitis. We included 52 subjects with an average age of 27.9 years. The study cohort included patients with skeletal CI I, CI II, and CI III and comprised 17 men (mean age, 27.6 years) and 35 women (mean age, 28.0 years) (Table 1). All patients provided informed consent for the use of their CT data in this study, which was approved by the KONIBP (Korea National Institute for Bioethics Policy, P01-201306-RS-01-00).

Table 1. Distribution of subjects by age and sex

Sex	Sample (n = 52)	Age (yr)	Age range (yr)
Men	17	27.6	19–38
Women	35	28.0	20–41

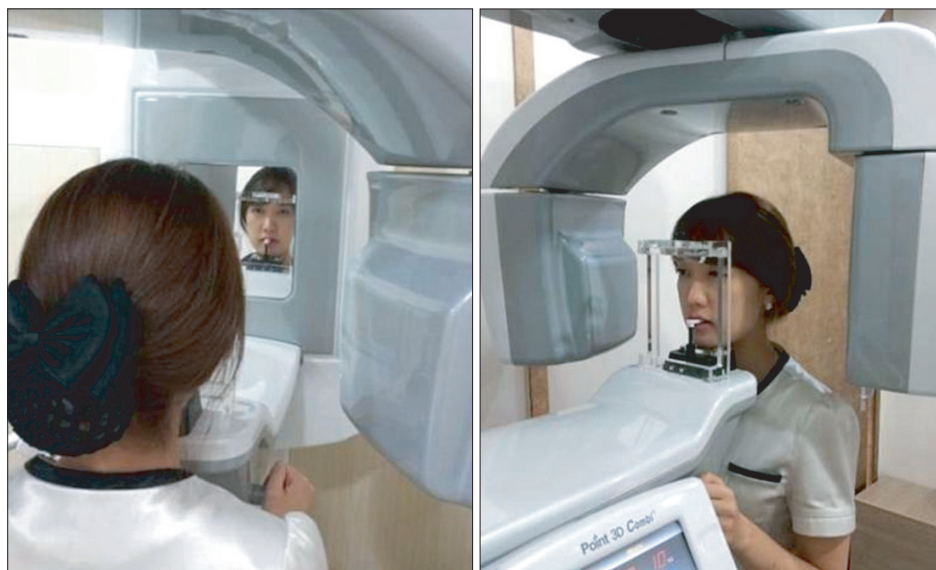

Figure 1. Cone-beam computed tomography scan in natural head position.

Measurements

The CBCT examinations were carried out after a vertical beam was fit to the central line of the patients' faces in the natural head position (NHP), in which they look at a mirror placed in front of the machine (Figure 1). The Digital Imaging and Communications in Medicine (DICOM) files obtained through CBCT (voxel size, 0.160 mm; field of view, 12 × 9 cm) were analyzed using OnDemand3D (Cybermed Inc., Seoul, Korea), a 3-dimensional (3D) analysis program. The reference planes for 3D analysis were the vertical and horizontal planes of the NHP obtained using CBCT. The horizontal plane was used as the reference plane for measurements (Figure 2).

Three interdental root regions were measured: between the maxillary central incisors (U1–U1), between the maxillary central incisor and the lateral incisor (U1–U2), and between the upper central incisor and the canine (U2–U3). For the regions U1–U2 and U2–U3, the site to the left or right with the least crowding was measured. In parallel with the reference line, the cortical bone

thickness on the labial side, the labio–palatal thickness, and the interdental root distance were measured at the 4 mm, 6 mm, and 8 mm levels apical to the interdental cementoenamel junction (ICEJ) (Figures 3–5).

Statistical analysis

Measurement and analysis of the data were carried out by a single researcher. To assess intra-examiner reliability, specimens were randomly extracted, and measurements were repeated 2 times at an interval of 1 week. No statistical differences were observed between the two sets of measurements ($p > 0.05$).

The data were analyzed using the SAS 9.2 Statistical Package program (SAS Institute, Cary, NC, USA). Because the data showed non-normal distribution, median and

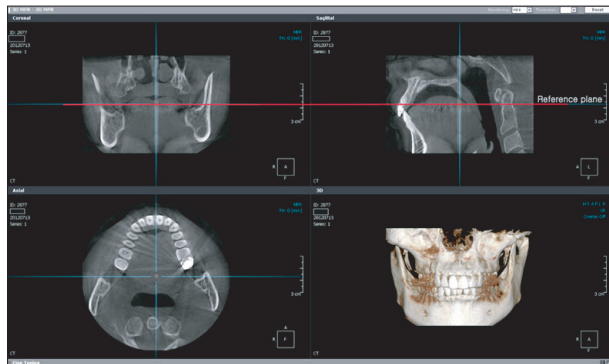


Figure 2. OnDemand3D (Cybermed Inc., Seoul, Korea) and reference plane.

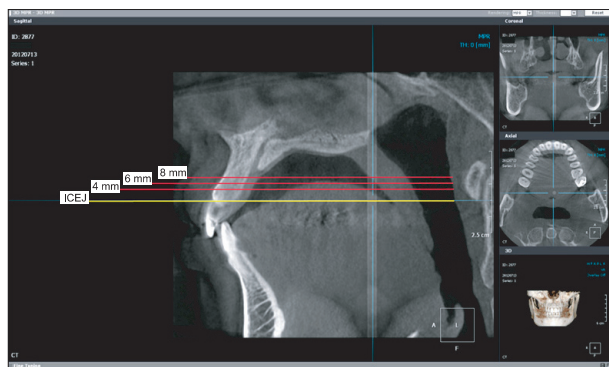


Figure 3. Reference line for measurement at 4 mm, 6 mm, and 8 mm levels of the interdental cementoenamel junction in sagittal view.

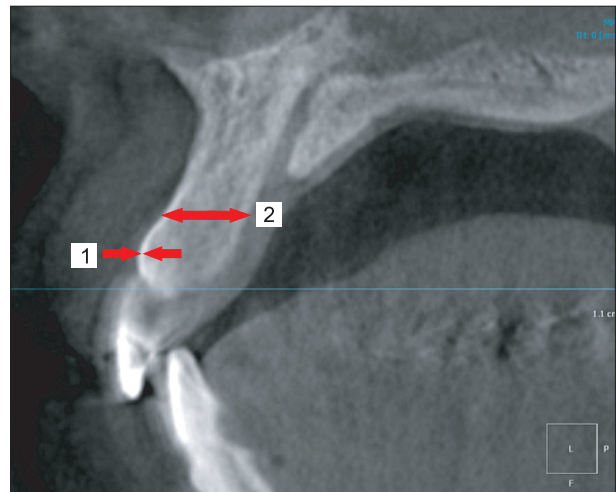


Figure 4. Measurement in sagittal view. 1, Cortical bone thickness; 2, labio-palatal thickness.

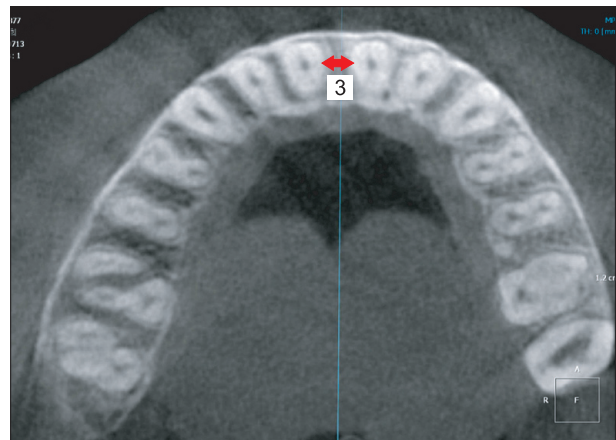


Figure 5. Measurement in axial view (4 mm level). 3, Interdental root distance.

interquartile ranges (IQR) were used instead of mean and standard deviation, and the Kruskal–Wallis Test was used to evaluate differences between and within the 3 regions.

RESULTS

Cortical bone thickness

Cortical bone was significantly thicker in the U2–U3 region than in the U1–U1 region. For all measured regions (U1–U1, U1–U2, and U2–U3), the cortical bone thickness tended to get thicker moving apically toward the ICEJ, and there was a significant difference between the 4 mm and 8 mm levels in the U1–U1 and U2–U3 regions ($p < 0.05$). In particular, the U1–U1 region

showed significantly thinner cortical bone, measuring about 0.70–0.80 mm ($p < 0.05$) (Table 2, Figure 6).

Labio-palatal thickness

The labio-palatal thickness was greatest in the U1–U2 region and was significantly less in the U1–U1 region ($p < 0.05$). In the U1–U1 region, the labio-palatal thickness decreased apically to the ICEJ; in particular, there was a significant difference between the 4 mm and 8 mm levels apical to the ICEJ ($p < 0.05$) (Table 3, Figure 7).

Interdental root distance

The interdental root distance was smallest in the U1–U2 region and largest in the U2–U3 region. In all measured regions (U1–U1, U1–U2, and U2–U3), the

Table 2. Cortical bone thickness at 4 mm, 6 mm, and 8 mm levels of the ICEJ

Site	Level		
	4 mm	6 mm	8 mm
U1–U1	0.70 ^{*†} (0.27)	0.80 [†] (0.30)	0.90 ^{*†} (0.34)
U1–U2	1.00 (0.30)	1.00 [†] (0.22)	1.10 [†] (0.21)
U2–U3	1.15 [*] (0.27)	1.20 [†] (0.20)	1.20 ^{*†} (0.13)

Values are presented as median (interquartile range).
^{*}Significant differences between 4 mm, 6 mm, and 8 mm levels ($p < 0.05$). [†]Significant differences between U1–U1, U1–U2, and U2–U3 ($p < 0.05$).
 ICEJ, Interdental cemento enamel junction; U1, upper central incisor; U2, upper lateral incisor; U3, upper canine.

Table 3. Labio-palatal thickness at 4 mm, 6 mm, and 8 mm levels of the ICEJ

Site	Level		
	4 mm	6 mm	8 mm
U1–U1	8.50 ^{*†} (1.45)	8.33 [†] (1.53)	7.88 ^{*†} (1.43)
U1–U2	9.56 (2.47)	9.77 (2.55)	9.87 (2.83)
U2–U3	9.43 (1.97)	9.48 (2.47)	9.08 (2.57)

Values are presented as median (interquartile range).
^{*}Significant differences between 4 mm, 6 mm, and 8 mm levels ($p < 0.05$). [†]Significant differences between U1–U1, U1–U2, and U2–U3 ($p < 0.05$).
 ICEJ, Interdental cemento enamel junction; U1, upper central incisor; U2, upper lateral incisor; U3, upper canine.

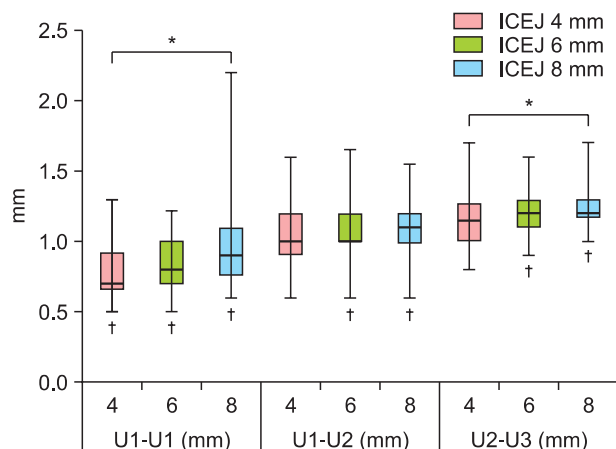


Figure 6. Box plot of cortical bone thickness.
^{*}Significant differences between 4 mm, 6 mm, and 8 mm levels ($p < 0.05$). [†]Significant differences between U1–U1, U1–U2, and U2–U3 ($p < 0.05$).
 U1, Upper central incisor; U2, upper lateral incisor; U3, upper canine; ICEJ, interdental cemento enamel junction.

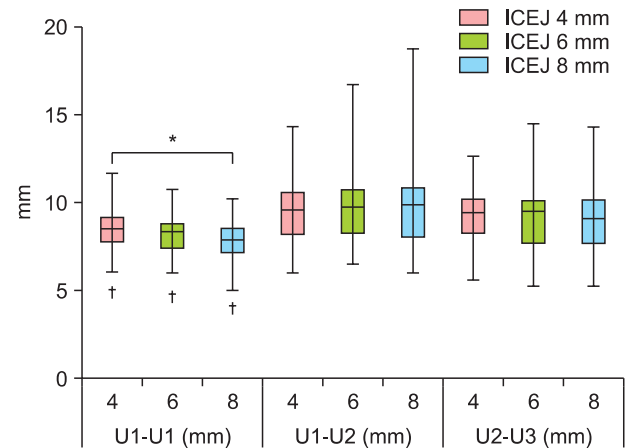


Figure 7. Box plot of labio-palatal thickness.
^{*}Significant differences between 4 mm, 6 mm, and 8 mm levels ($p < 0.05$). [†]Significant differences between U1–U1, U1–U2, and U2–U3 ($p < 0.05$).
 U1, Upper central incisor; U2, upper lateral incisor; U3, upper canine; ICEJ, interdental cemento enamel junction.

interdental root distances were significantly larger apical to the ICEJ ($p < 0.05$) (Table 4, Figure 8).

DISCUSSION

In the past, orthodontic treatment for gummy smile or deep overbite was considered very difficult. In severe cases, orthognathic surgery was usually recommended, and the more conservative choice of orthodontic treatment alone did not always yield good aesthetic results, namely, gum exposure is frequently increased after such attempts at correction.¹⁴

For cases involving premolar extraction, the application of additional intrusion force after placing a miniscrew implant into the maxillary anterior region yields good

results in patients with a gummy smile and a long face.⁸⁻¹⁴ In non-extraction patients with a deep bite, satisfactory results can be obtained by applying intrusion force toward the center of resistance after placing a miniscrew implant between the lateral incisor and the canine.⁸⁻¹⁴ Thus, the use of miniscrew implants in the maxillary anterior region is essential for treating gummy smile or anterior deep overbite.

Two clinical approaches that affect the stability of the current miniscrew implant are presently used.¹⁸ The first approach is to wait for osseointegration after placing a miniscrew implant and subsequently applying orthodontic force. In this approach, the quality of spongy bone is more important than cortical bone thickness.^{21,22} However, osseointegration takes time, so orthodontic force cannot be applied immediately. The second approach is to apply orthodontic force immediately after placing a miniscrew implant, before osseointegration occurs. In this approach, cortical bone thickness plays a more important role than bone quality in obtaining sufficient mechanical interaction between the miniscrew implants and bone. Many studies suggest that cortical bone thickness is the most important determinant of initial stability.²³⁻³⁴ For orthodontic correction, the initial stability provided by cortical bone thickness is a very important factor because the force is added just after implantation or within 1 to 3 weeks thereafter.

We observed that the cortical bone thickness at levels 4 to 8 mm apical to the ICEJ were 0.70 ± 0.27 to 0.90 ± 0.30 mm in the U1-U1 region, 1.00 ± 0.32 to 1.10 ± 0.21 mm in the U1-U2 region, and 1.15 ± 0.27 to 1.20 ± 0.13 mm in the U2-U3 region. According to Farnsworth et al.²⁰, the cortical bone thickness was 1.33 ± 0.24 mm in the U4-U5 region, 1.45 ± 0.28 mm in the U5-U6 region, and 1.26 ± 0.24 mm in the U6-U7 region. We observed that the cortical region of the maxillary anterior alveolar bone was thinner than that of the buccal premolar and molar regions. In particular, the region between the maxillary central incisors (U1-U1) showed a cortical bone thickness as small as 0.70–0.90 mm. Nevertheless, in practice, miniscrews are implanted in this region without any big problems in stability.⁸⁻¹⁴ An orthodontic force about 200–250 g is applied for retraction of anterior teeth, while a force of only 50–100 g is necessary for anterior tooth intrusion; thus, this relatively weak force does not cause stability problems.^{35,36}

In addition to cortical bone thickness, other factors affecting the stability of miniscrew implants should be considered. Davies³⁷ described the process of post-implant bone healing by contact osteogenesis and distant osteogenesis in spongy bone. Contact osteogenesis is the process whereby osteoprogenic cells origi-

Table 4. Interdental root distance at the 4 mm, 6 mm, and 8 mm levels of the ICEJ

Site	Level		
	4 mm	6 mm	8 mm
U1-U1	2.37* (0.67)	3.01* (0.69)	3.87* (0.99)
U1-U2	1.90**† (0.41)	2.28**† (0.60)	2.95**† (0.90)
U2-U3	2.80* (0.68)	3.24* (0.75)	3.88* (0.84)

Values are presented as median (interquartile range). *Significant differences between 4 mm, 6 mm, and 8 mm level ($p < 0.05$). †Significant differences between U1-U1, U1-U2, and U2-U3 ($p < 0.05$).

ICEJ, Interdental cemento enamel junction; U1, upper central incisor; U2, upper lateral incisor; U3, upper canine.

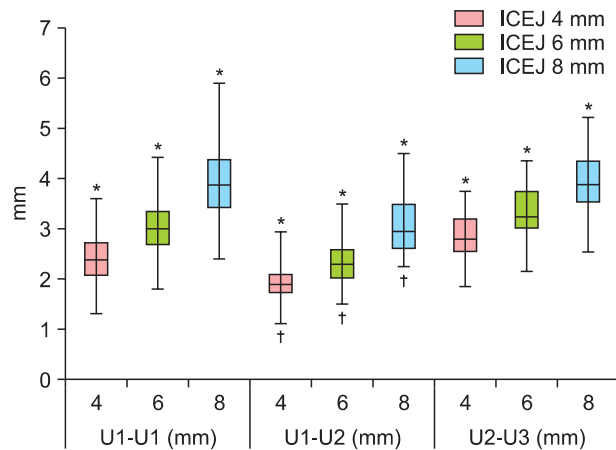


Figure 8. Box plot of interdental root distance. *Significant differences between 4 mm, 6 mm, and 8 mm levels ($p < 0.05$). †Significant differences between U1-U1, U1-U2, and U2-U3 ($p < 0.05$). U1, Upper central incisor; U2, upper lateral incisor; U3, upper canine; ICEJ, interdental cemento enamel junction.

nating from blood (medulla) attach to the surface of the miniscrew implant, forming a group. These cells change into osteoblast cells to form bone in the direction of the existing bone on the surface of the implant. Because this new bone is formed immediately at the surface of an implant, it plays a very important role in the initial and early stability of the implant.³⁷ Distant osteogenesis takes place in existing bone, with growth toward the surface of the miniscrew. If contact osteogenesis is not satisfactory early in the healing process, stabilization of the bone will take longer because the bone must be formed entirely by distant osteogenesis; poor initial stability can thus cause implant failure. Davies³⁷ suggested that the success of implants in thin or poor cortical bones (CI III and CI IV bones) depends on adequate contact osteogenesis.

Moon et al.³⁸ and Kuroda et al.³⁹ reported that while mandibular cortical bone is thicker than maxillary posterior alveolar bone, the success rate of implantation into the latter is similar to or higher than that of the mandibular molar region. Because factors related to spongy bone blood supply are reduced in the mandible as compared to the maxilla, the latter is a more favorable environment for contact osteogenesis in spongy bone. Thus, contact osteogenesis is an important factor determining miniscrew implant stability.

The labio-palatal thickness was greatest in the U1-U2 region and least in the U1-U1 region. In the U1-U1 region, the labio-palatal thickness decreased apically toward the ICEJ. In particular, there was a significant difference between the 4 mm and 8 mm levels. This trend relates to the incisive foramen, starting at the height of about 6 mm. Thus, the safe placement length for miniscrew implants placed in the U1-U1 region is thought to be 7-8 mm. In addition, at the 6 mm and 8 mm levels, the displacement of measurement values in the U1-U2 and U2-U3 regions appears to be relatively larger than that in the U1-U1 region. This observation indicates that the difference in displacement of labio-palatal thickness in the U1-U2 and U2-U3 regions was severe, as the difference depends on the depth of the maxillary palatal vault. Thus, if the palatal vault is deep, miniscrews with a length about 6-7 mm would be best for fixing miniscrew implants in the U1-U2 and U2-U3 regions.

The interdental root distance at the 4 mm and 8 mm levels was 2.37 ± 0.67 to 3.87 ± 0.99 mm in the U1-U1 region, 1.90 ± 0.41 to 2.95 ± 0.90 mm in the U1-U2 region, and 2.80 ± 0.68 to 3.88 ± 0.84 mm in the U2-U3 region. Regarding the mesiodistal dimension, Schnelle et al.¹⁵ suggested that at least 3 mm of interradicular space would be required for safe placement of a miniscrew implant. Poggio et al.⁴⁰ also emphasized maintaining enough interradicular space

to protect periodontal health and ensure implant stability. A minimum clearance of 1 mm of bone around the miniscrew implant has been recommended for safety.²⁴ However, Janson et al.⁴¹ recently proposed that the proximity of roots to miniscrew implants did not influence the stability or success rate when the distance between the miniscrew implant and dental root indicated no periodontal ligament invasion. Wider interradicular space can be achieved because miniscrew implants are generally placed at angle of about 60°-80°, but not perpendicular to cortical bone. The diameter of commonly used miniscrew implants is 1.2-1.6 mm. Considering the interdental root distance, this diameter poses no problem for maxillary anterior implants; however, especially for placement in the U1-U2 region, miniscrew implants with a diameter of 1.2 mm or 1.0 mm will be safer.

CONCLUSION

The region between the maxillary lateral incisor and the canine (U2-U3) should be the first choice for miniscrew implantation into maxillary anterior interdental alveolar bone. This choice is optimal regarding cortical bone thickness, interdental root distance, and labio-palatal thickness. However, this region requires the placement of 2 miniscrew implants in total, one on the left side and one on the right side. Alternatively, the region between the maxillary central incisors (U1-U1) may be considered the second best site, as intrusion of the maxillary anterior teeth is possible just with one miniscrew implant.

REFERENCES

1. Silberberg N, Goldstein M, Smidt A. Excessive gingival display-etiology, diagnosis, and treatment modalities. *Quintessence Int* 2009;40:809-18.
2. Jung MH. Age, extraction rate and jaw surgery rate in Korean orthodontic clinics and small dental hospitals. *Korean J Orthod* 2012;42:80-6.
3. Im DH, Kim TW, Nahm DS, Chang YI. Current trends in orthodontic patients in Seoul National University Dental Hospital. *Korean J Orthod* 2003;33:63-72.
4. Sarver DM. Principles of cosmetic dentistry in orthodontics: Part 1. Shape and proportionality of anterior teeth. *Am J Orthod Dentofacial Orthop* 2004; 126:749-53.
5. Sarver DM, Yanosky M. Principles of cosmetic dentistry in orthodontics: part 2. Soft tissue laser technology and cosmetic gingival contouring. *Am J Orthod Dentofacial Orthop* 2005;127:85-90.
6. Monaco A, Streni O, Marci MC, Marzo G, Gatto R, Giannoni M. Gummy smile: clinical parameters

- useful for diagnosis and therapeutical approach. *J Clin Pediatr Dent* 2004;29:19-25.
7. Levine RA, McGuire M. The diagnosis and treatment of the gummy smile. *Compend Contin Educ Dent* 1997;18:757-62, 764; quiz 766.
 8. Ohnishi H, Yagi T, Yasuda Y, Takada K. A mini-implant for orthodontic anchorage in a deep overbite case. *Angle Orthod* 2005;75:444-52.
 9. Deguchi T, Murakami T, Kuroda S, Yabuuchi T, Kamioka H, Takano-Yamamoto T. Comparison of the intrusion effects on the maxillary incisors between implant anchorage and J-hook headgear. *Am J Orthod Dentofacial Orthop* 2008;133:654-60.
 10. Lin JC, Liou EJ, Bowman SJ. Simultaneous reduction in vertical dimension and gummy smile using miniscrew anchorage. *J Clin Orthod* 2010;44:157-70.
 11. Saxena R, Kumar PS, Upadhyay M, Naik V. A clinical evaluation of orthodontic mini-implants as intraoral anchorage for the intrusion of maxillary anterior teeth. *World J Orthod* 2010;11:346-51.
 12. Polat-Özsoy Ö, Arman-Özçirpıcı A, Veziroğlu F, Çetinşahin A. Comparison of the intrusive effects of miniscrews and utility arches. *Am J Orthod Dentofacial Orthop* 2011;139:526-32.
 13. Senışık NE, Türkkahraman H. Treatment effects of intrusion arches and mini-implant systems in deepbite patients. *Am J Orthod Dentofacial Orthop* 2012;141:723-33.
 14. Kaku M, Kojima S, Sumi H, et al. Gummy smile and facial profile correction using miniscrew anchorage. *Angle Orthod* 2012;82:170-7.
 15. Schnelle MA, Beck FM, Jaynes RM, Huja SS. A radiographic evaluation of the availability of bone for placement of miniscrews. *Angle Orthod* 2004;74:832-7.
 16. Lee KJ, Joo E, Kim KD, Lee JS, Park YC, Yu HS. Computed tomographic analysis of tooth-bearing alveolar bone for orthodontic miniscrew placement. *Am J Orthod Dentofacial Orthop* 2009;135:486-94.
 17. Gahleitner A, Podesser B, Schick S, Watzek G, Imhof H. Dental CT and orthodontic implants: imaging technique and assessment of available bone volume in the hard palate. *Eur J Radiol* 2004;51:257-62.
 18. Deguchi T, Nasu M, Murakami K, Yabuuchi T, Kamioka H, Takano-Yamamoto T. Quantitative evaluation of cortical bone thickness with computed tomographic scanning for orthodontic implants. *Am J Orthod Dentofacial Orthop* 2006;129:721.e7-12.
 19. Kim JH, Park YC. Evaluation of mandibular cortical bone thickness for placement of temporary anchorage devices (TADs). *Korean J Orthod* 2012;42:110-7.
 20. Farnsworth D, Rossouw PE, Ceen RF, Buschang PH. Cortical bone thickness at common miniscrew implant placement sites. *Am J Orthod Dentofacial Orthop* 2011;139:495-503.
 21. Albrektsson T, Brånemark PI, Hansson HA, Lindström J. Osseointegrated titanium implants. Requirements for ensuring a long-lasting, direct bone-to-implant anchorage in man. *Acta Orthop Scand* 1981;52:155-70.
 22. Roberts WE, Smith RK, Zilberman Y, Mozsary PG, Smith RS. Osseous adaptation to continuous loading of rigid endosseous implants. *Am J Orthod* 1984;86:95-111.
 23. Costa A, Raffainl M, Melsen B. Miniscrews as orthodontic anchorage: a preliminary report. *Int J Adult Orthodon Orthognath Surg* 1998;13:201-9.
 24. Park HS, Jeong SH, Kwon OW. Factors affecting the clinical success of screw implants used as orthodontic anchorage. *Am J Orthod Dentofacial Orthop* 2006;130:18-25.
 25. Park J, Cho HJ. Three-dimensional evaluation of interradicular spaces and cortical bone thickness for the placement and initial stability of microimplants in adults. *Am J Orthod Dentofacial Orthop* 2009;136:314.e1-12; discussion 314-5.
 26. Santiago RC, de Paula FO, Fraga MR, Picorelli Assis NM, Vitral RW. Correlation between miniscrew stability and bone mineral density in orthodontic patients. *Am J Orthod Dentofacial Orthop* 2009;136:243-50.
 27. Frost HM. Bone "mass" and the "mechanostat": a proposal. *Anat Rec* 1987;219:1-9.
 28. Frost HM. Skeletal structural adaptations to mechanical usage (SATMU): 1. Redefining Wolff's law: the bone modeling problem. *Anat Rec* 1990;226:403-13.
 29. Frost HM. Skeletal structural adaptations to mechanical usage (SATMU): 2. Redefining Wolff's law: the remodeling problem. *Anat Rec* 1990;226:414-22.
 30. Frost HM. Wolff's Law and bone's structural adaptations to mechanical usage: an overview for clinicians. *Angle Orthod* 1994;64:175-88.
 31. Meredith N, Alleyne D, Cawley P. Quantitative determination of the stability of the implant-tissue interface using resonance frequency analysis. *Clin Oral Implants Res* 1996;7:261-7.
 32. Meredith N. A review of nondestructive test methods and their application to measure the stability and osseointegration of bone anchored endosseous implants. *Crit Rev Biomed Eng* 1998;26:275-91.
 33. Wilmes B, Rademacher C, Olthoff G, Drescher D. Parameters affecting primary stability of orthodontic mini-implants. *J Orofac Orthop* 2006;67:162-74.
 34. Miyamoto I, Tsuboi Y, Wada E, Suwa H, Iizuka T. Influence of cortical bone thickness and implant length on implant stability at the time of surgery-

- clinical, prospective, biomechanical, and imaging study. *Bone* 2005;37:776-80.
35. Burstone CR. Deep overbite correction by intrusion. *Am J Orthod* 1977;72:1-22.
 36. Weiland FJ, Bantleon HP, Droschl H. Evaluation of continuous arch and segmented arch leveling techniques in adult patients--a clinical study. *Am J Orthod Dentofacial Orthop* 1996;110:647-52.
 37. Davies JE. Understanding peri-implant endosseous healing. *J Dent Educ* 2003;67:932-49.
 38. Moon CH, Lee DG, Lee HS, Im JS, Baek SH. Factors associated with the success rate of orthodontic miniscrews placed in the upper and lower posterior buccal region. *Angle Orthod* 2008;78:101-6.
 39. Kuroda S, Sugawara Y, Deguchi T, Kyung HM, Takano-Yamamoto T. Clinical use of miniscrew implants as orthodontic anchorage: success rates and postoperative discomfort. *Am J Orthod Dentofacial Orthop* 2007;131:9-15.
 40. Poggio PM, Incorvati C, Velo S, Carano A. "Safe zones": a guide for miniscrew positioning in the maxillary and mandibular arch. *Angle Orthod* 2006;76:191-7.
 41. Janson G, Gigliotti MP, Estelita S, Chiqueto K. Influence of miniscrew dental root proximity on its degree of late stability. *Int J Oral Maxillofac Surg* 2013;42:527-34.