

# Bronchopulmonary Infection of *Lophomonas blattarum*: A Case and Literature Review

Jian Xue<sup>1</sup>, Ying-Li Li<sup>1</sup>, Xue-Mei Yu<sup>2</sup>, Dai-Kun Li<sup>2</sup>, Ming-Fang Liu<sup>2</sup>, Jing-Fu Qiu<sup>1</sup>, Jian-Jiang Xue<sup>2,\*</sup>

<sup>1</sup>School of Public Health and Management, Chongqing Medical University, Yuzhong District, Chongqing, China; <sup>2</sup>Department of Inspection, University-Town Hospital of Chongqing Medical University, Shapingba District, Chongqing 400016, China

**Abstract:** Human infections with *Lophomonas blattarum* are rare. However, the majority of the infections occurred in China, 94.4% (136 cases) of all cases in the world. This infection is difficult to differentiate from other pulmonary infections with similar symptoms. Here we reported a case of *L. blattarum* infection confirmed by bronchoalveolar lavage fluid smear on the microscopic observations. The patient was a 21-year-old female college student. The previous case which occurred in Chongqing was 20 years ago. We briefly reviewed on this infection reported in the world during the recent 20 years. The epidemiological characteristics, possible diagnostic basis, and treatment of this disease is discussed in order to provide a better understanding of recognition, diagnosis, and treatment of *L. blattarum* infection.

**Key words:** *Lophomonas blattarum*, bronchopulmonary, case report, literature review

## INTRODUCTION

*Lophomonas blattarum* is a protozoan that usually parasitizes in the intestinal tracts of termites and cockroaches; *Lophomonas* belongs to the supergroup Excavata, first rank Parabasalia, and second rank Cristamonadida in protozoa [1]. It can cause infections in a variety of tissues and organs, including the maxillary sinus and other sinuses, lungs, reproductive system, and respiratory tract. This infection is difficult to differentiate from other common infections with similar symptoms (such as pneumonia, bronchitis, or inflammation) from the clinical manifestations and laboratory tests. Drugs for other common infections were almost useless for *L. blattarum* infection [2,3]. Two-thirds of the patients have been diagnosed with *L. blattarum* infection as soon as they were admitted to the hospital, then they were given metronidazole or tinidazole for treatment. The other one-third of patients was treated with antibiotics without effects. Early and correct diagnosis is a key factor for treatment of *L. blattarum* infection.

This protozoan parasite was identified by bronchoscopic

brush smears, bronchoscopic biopsy smears, or bronchoalveolar lavage (BAL), and the patient was treated with metronidazole or tinidazole, with good prognosis. So far, *L. blattarum* human infections occur mainly in China, in addition to 6 cases from Peru in the National Reference Center of Pediatric Diseases of Lima from 2009 to 2010 [4], 2 cases from Spain [5,6], and 1 case of *L. blattarum* isolated from a clinically normal houbara bustard in the United Arab Emirates in 1999 [7].

In China, since the first case of pulmonary *L. blattarum* infection was reported in 1993 [8], 136 cases have been diagnosed during the recent 20 years [2,3,8-39] (Table 1). Among the 136 cases, more than 3 quarters were identified in the southern area of China. There was only 1 case which was reported so far on the basis of available information in Chongqing but checked out in Shanghai in 2000 [31]. Here, a new case of *L. blattarum* infection was found in Chongqing, which was identified in the University-Town Hospital of Chongqing Medical University in 2013. Also, a literature review of *L. blattarum* infection in China during the recent 20 years has been carried out in order to provide a better understanding of recognition and diagnosis of *L. blattarum* infection.

## CASE DESCRIPTION

A 21-year-old female college student was admitted to the University-Town Hospital of Chongqing Medical University,

•Received 30 December 2013, revised 22 July 2014, accepted 6 September 2014.

\*Corresponding author (464046033@qq.com)

© 2014, Korean Society for Parasitology and Tropical Medicine

This is an Open Access article distributed under the terms of the Creative Commons Attribution Non-Commercial License (<http://creativecommons.org/licenses/by-nc/3.0>) which permits unrestricted non-commercial use, distribution, and reproduction in any medium, provided the original work is properly cited.

**Table 1.** Review of human infections with *Lophomonas blattarum* (1993-2013)

Reported case no.	Sex/age of patients	No. of cases	Year	Country (region)	Reference
1	F/35y	1	1993	China (S)	[8]
2	M/38y, F/32y	2	1997	China (S)	[28]
3	F/51y	1	1998	China (S)	[25]
4	F/34y	1	1999	China (S)	[33]
5	M/15y	1	2000	China (S)	[31]
6	F/20y	1	2003	China (S)	[10]
7	M/56y	1	2004	China (S)	[9]
8	M/5y	1	2005	China (N)	[15]
9	M/58y	1	2006	China (S)	[22]
10	M/21y	1	2007	Spain	[5]
11	M/39	1	2007	China (N)	[17]
12	(19M+7F)/(19-95y) <sup>a</sup>	26	2007	China (S)	[23]
13	F/34y	1	2007	China (N)	[18]
14	M/65y, M/55y, F/53y	3	2008	China (S)	[29]
15	M/35y	1	2008	China (N)	[14]
16	M/16y	1	2008	China (S)	[21]
17	F/32y	1	2008	China (N)	[3]
18	(11M+6F)/(19-65y) <sup>a</sup>	17	2009	China (S)	[24]
19	NA	1	2009	China (S)	[35]
20	F/9d	1	2009	China (S)	[16]
21	M/25y	1	2009	China (S)	[32]
22	F/78y	1	2009	China (S)	[27]
23	NA	1	2010	Spain	[6]
24	NA/(4m-15y) <sup>a</sup>	6	2010	Peru	[4]
25	(14M+10F)/(28-84y) <sup>a</sup>	24	2010	China (N)	[19]
26	F/51y, M/73y	2	2010	China (S)	[34]
27	M/41y	1	2010	China (S)	[36]
28	F/54y	1	2010	China (N)	[20]
29	M/21y	1	2011	China (N)	[37]
30	(17M+15F)/(20-86y) <sup>a</sup>	32	2011	China (S)	[39]
31	M/41, M/55	2	2011	China (S)	[2]
32	M/67y	1	2012	China (S)	[30]
33	F/59y, M/77y	2	2012	China (S)	[13]
34	F/47y, F/61y	2	2013	China (S)	[38]
35	M/69y	1	2013	China (S)	[11]
36	F/25y	1	2013	China (N)	[12]

<sup>a</sup>Sex composition/Age range.

NA, not available; S, southern area of China, N, northern area of China.

Chongqing, China, on 21 June 2013, with chief complaints of cough and expectoration for 3 days accompanied with fever for 2 days without any past or family history. Three days ago, she caught a cold followed by expectorating white phlegm along with sore throat, and the body temperature was up to 39°C before 1 day ago. She was diagnosed as pneumonia on the chest X-ray in another hospital.

On 22 June 2013, physical examination of the patient showed both lung breath sounds rough, the bilateral lower lung auscul-

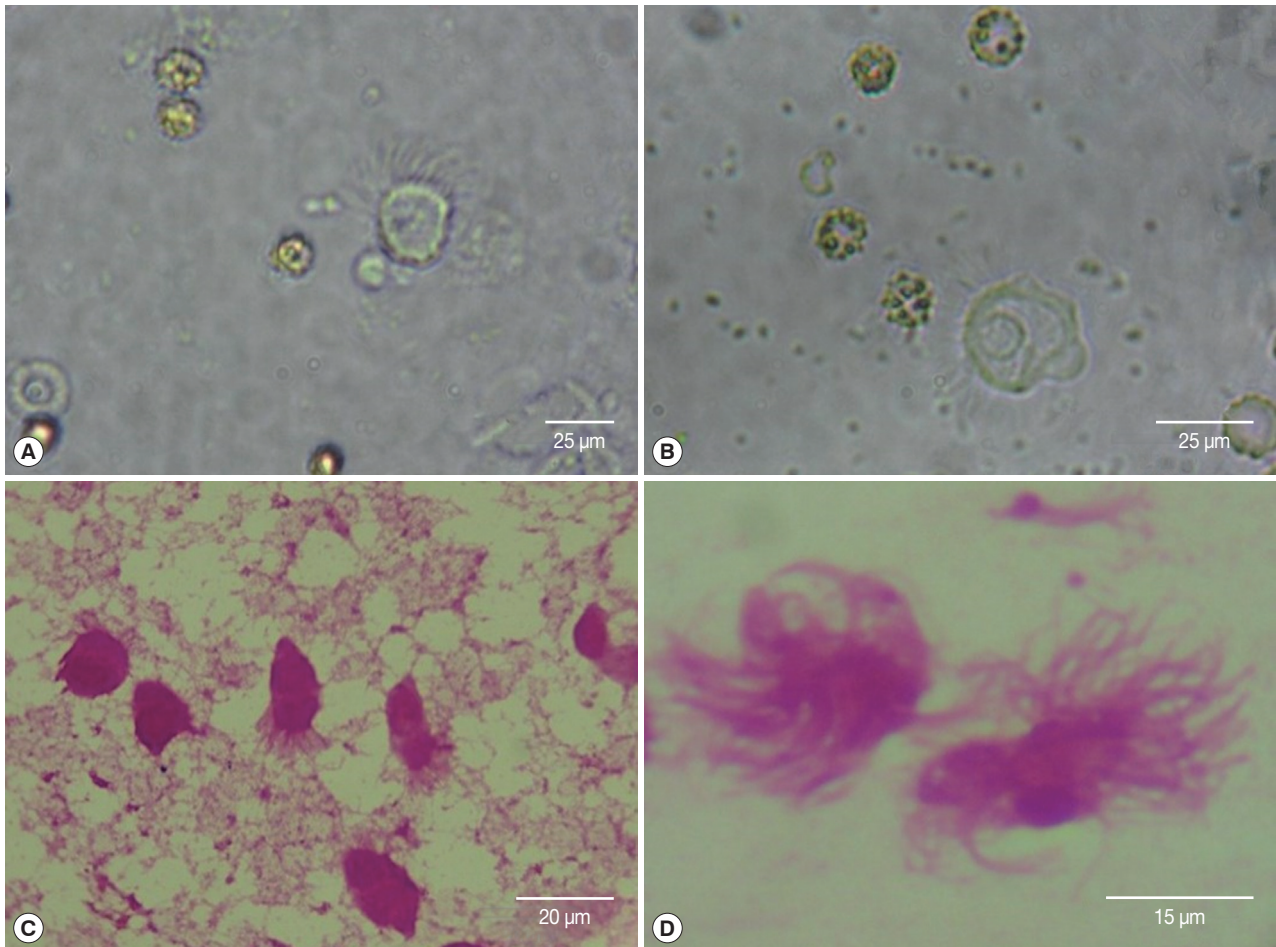
tation with rales or rhonchi and the other vital signs included blood pressure 106/72 mmHg, pulse rate 115 beats/min, respiratory rate 20 breaths/min, and body temperature 36.9°C. The clinical laboratory tests for blood, urine, feces, and hepatic and renal functions were within normal limits. However, the C-reactive protein (CRP) was 32.7 mg/L and the erythrocyte sedimentation rate (ESR) was 22 mm/hr. Chest computed tomography (CT) scan showed right pleural effusions accompanied with pleural adhesions, enlarged mediastinal lymph nodes and the left inferior lobar inflammation. Meanwhile, she was treated with cefoxitin for anti-infection and enhancement of immunity. One day after admission, her body temperature and the pulse rate were within normal limits. However, both the rough lung breath sounds and the bilateral lower lung auscultation with rales or rhonchi were continued. Acid-fast bacilli (AFB) were negative in the sputum smear, and electronic bronchoscopy was done in the left lower lobe basal segment.

The BAL fluid was collected by bronchofiberscope, and the upper frothy sputum was spread on 4 glass slides for Wright-Giemsa stain. The live protozoan, *L. blattarum*, was found on light microscopy of the BAL smear. It was about 20-30 µm in size, with a round or oval-shaped body and 30-40 flagella on one end. *L. blattarum* can swim fast by waving its flagella constantly. After the Wright-Giemsa staining, it changed to pear-shaped, with mauve colored cytoplasm. The flagellum length was from 8 to 18 µm, arranged in bundles on one end (Fig. 1).

## DISCUSSION

After reviewing the literature [2,3,8-39], we found 136 cases of previous reports of *L. blattarum* infections that had occurred in 11 provinces and 2 municipalities in China since 1993. Among the patients, 80 cases were male and 55 cases were female, besides 1 with unknown gender, with ages ranging from 9-days to 95 years-old. It was shown that the infection had no significant differences by gender and age. The occurrence of patients from the southern China area was 76.5% and the others came from the northern area. The southern China refers to Hunan, Anhui, Zhejiang, Jiangsu, Guangdong, Fujian province, and Chongqing municipality. The northern China refers to Shaanxi, Liaoning, Shandong, Hebei, Xinjiang province, and Tianjin municipality). The weather of southern area is warmer and more humid.

As a part of the reported cases was identified without giving the pest species only to families, it could be called 'hypermastigote' in many databases (now called Cristamonadida [1]).



**Fig. 1.** *Lophomonas blattarum* detected from BAL fluid of the patients by microscopic observations: Direct smear (A, B,  $\times 400$ ) and Wright-Giemsa stain (C, D,  $\times 1,000$ ).

We detected the patients infected with 'hypermastigote' or *L. blattarum* as the search keyword in VIP-database, CNKI, Wanfang-database (the 3 major databases in China), PubMed database, Embase database and the Web of Science database retrieved all the reports in recent 20 years. After rechecking and screening, 136 cases were determined. Their clinical features were listed below (Table 2).

The diagnostic clues of *L. blattarum* infection are as follows: First, patients have clinical symptoms of an infection without the effect of anti-infection treatment with a marked peripheral blood eosinophilia. Second, patients have underlying diseases and treated with immunosuppressants for a long time or with the pulmonary infection after surgery. Third, the X-ray and CT imaging features of the patients show ground-glass opacity, patchy consolidation, and patchy or streaky shadows distributed in bilateral lungs. Fourth, the detection of *L. blattarum* can be done in sputum smears, bronchoscopy biopsy smears, or BAL.

All the reported cases in China confirmed that the treatment of the infection depends on metronidazole and tinidazole.

*L. blattarum* was proved to parasitize in the colon of cockroaches [40]. Although *L. blattarum* usually parasitizes in intestinal tracts of termites and cockroaches, it could be discharged being accompanied with the secretion and excrement of the host's digestive tract. The cysts of this protozoa are spread by contaminated food and clothing. Therefore, someone could be infected easily by breathing the dust containing *L. blattarum*. To prevent *L. blattarum* infection, it is needed to control the source of infection, that is, termites and cockroaches. In fact, human infections with *L. blattarum* are relatively rare. In the past 2 decades, 136 cases of *L. blattarum* infection, including 2 disputable cases have been reported in China [41]. The patients reported from southern cities accounted for three-quarters. It is most likely because cockroaches and termites are the hosts of *L. blattarum*, this protozoan can breed easily in the

**Table 2.** Review of clinical and radiological analysis of 136 cases of *Lophomonas blattarum* infection (1993-2013)

Clinical and radiological analysis	No. cases (%)
1. Infection sites	136 (100)
Respiratory tract infection	131 (96.3)
Urinary tract infection	2 (1.5)
Sinusitis	3 (2.2)
2. Diagnostic samples in respiratory tract infection	131 (100)
BAL fluid	101 (77.1)
Sputum	27 (20.6)
Throat swab	1 (0.76)
Bronchial mucosa smear	1 (0.76)
Cystic fluid	1 (0.76)
3. Clinical symptoms and peripheral blood examination	131 (100)
Cough with expectoration	108 (82.4)
Fever	79 (58.1)
Eosinophilia	28 (24.8)
4. X-ray imaging manifestations	30 (100)
Patchy or streaky shadows	23 (76.7)
5. CT imaging manifestations	67 (100)
Ground-glass opacity	22 (32.8)
Patchy consolidation	26 (38.8)
Nodular opacities	11 (16.4)

humid environment.

So far, except for the 136 cases being concentrated in China, *L. blattarum* infection was also reported in humans in Peru in 2010 [4] and Spain in 2007 and 2010 [5,6]. There was 1 case of *L. blattarum* isolated from a houbara bustard that was a clinically normal bird in the United Arab Emirates in 1999 [7]. After all, 95 of 136 clinical cases which account for around two-thirds, occurred within the recent 5 years. The clinical manifestations and signs of *L. blattarum* infection are similar to the other etiologic pneumonia and bronchitis. It is difficult to diagnose correctly.

Two points are worthy of special mentioning: 1) ineffectiveness of antibiotics. Among the 136 patients diagnosed with *L. blattarum* infections, 46 patients were treated with antibiotics for anti-infection and anti-inflammatory before using metronidazole (1 patient took antibiotics for almost 3 months without effects [3]), but all invalid. 2) The influence of the underlying disease was significant. For example, 68 of 136 cases had underlying diseases (it included 3 types of diseases, 1 was the basic metabolic disorders, the other 2 were the weakened immune system and severe chronic wasting disease), mainly with severe chronic obstructive pulmonary disease (COPD) and organ transplantation which accounted for 29.4% and 30.9%, respectively. Above all, it is strongly needed to have knowledge

on *L. blattarum* infection before giving diagnosis and treatment of this protozoan infection.

## ACKNOWLEDGMENT

The research leading to this manuscript has received funding from the National Natural Science Foundation of China (grant no. 31071093, 31170129, and 31200064).

## CONFLICT OF INTEREST

We have no conflict of interest related to this study.

## REFERENCES

- Adl SM, Simpson AGB, Farmer MA, Andersen RA, Andersen OR, Barta JR, Bowser SS, Brugerolle G, Fensome RA, Fredericq S, James TY, Karpov S, Kugrens P, Krug J, Lane CE, Lewis LA, Lodge J, Lynn DH, Mann DG, McCourt RM, Mendoza L, Moestrup Ø, Mozley-Standridge SE, Nerad TA, Shearer CA, Smirnov AV, Spiegel FW, Taylor MFJ. The new higher level classification of eukaryotes with emphasis on the taxonomy of protists. *J Eukaryot Microbiol* 2005; 52: 399-451.
- He Q, Chen X, Lin B, Qu L, Wu J, Chen J. Late onset pulmonary *Lophomonas blattarum* infection in renal transplantation: a report of two cases. *Intern Med* 2011; 50: 1039-1043.
- Zhang CF, Zhang C, Gao HF. A case of bronchopulmonary infection caused by hypermastigote accompanied with tuberculosis and review of the literature. *Chinese J Pract Intern Med* 2008; 28: 1093-1094 (in Chinese).
- Zerpa R, Ore E, Patiño L, Espinoza YA. *Lophomonas* spp. in respiratory tract secretions in hospitalized children with severe lung disease. *Rev Peru Med Exp Salud Publica* 2010; 27: 575-577.
- Martínez-Girón R, Ribas A, Astudillo-González A. Flagellated protozoa in cockroaches and sputum: the unhygienic connection? *Allergy Asthma Proc* 2007; 28: 608-609.
- Martínez-Girón R, Doganci L. *Lophomonas blattarum*: a bronchopulmonary pathogen. *Acta Cytol* 2010; 54 (5 suppl): 1050-1051.
- Silvanose CD, Bailey TA, Samour JH, Naldo JL. Intestinal protozoa and associated bacteria in captive houbara bustards (*Chlamydotis undulata*) in the United Arab Emirates. *Avian Pathol* 1999; 28: 94-97.
- Chen SX, Meng ZX. Report on one case of *Lophomonas blattarum* in the respiratory tract. *Chinese J Parasitol Parasit Dis* 1993; 11: 28 (in Chinese).
- Bai M, Yao X, Li Q. Report on one case of lung infection with hypermastigote. *Chinese J Intern Med* 2004; 43: 868-869 (in Chinese).
- Chen CE, Liu DG. Report on one case of *Lophomonas blattarum* in urine. *Chinese J Lab Diagn* 2003; 7: 131-131 (in Chinese).

11. Chen XR, Zheng R, Zhang TT. Report on one case of *Lophomonas blattarum*-fungi coinfection. *Pract Prevent Med (China)* 2013; 20: 62-64 (in Chinese).
12. Chen Y. Report on one case of pregnancy with reproductive system infection with *Lophomonas blattarum*. *Tianjin Med J* 2013; 41: 93-94 (in Chinese).
13. Feng Y, Ge GX. Report on two cases of lower respiratory tract infection caused by *Lophomonas blattarum*. *Chinese J Clin Infect Dis* 2012; 5: 306-307 (in Chinese).
14. Kang JF, Wu LM, Zhang W, Yu F, Zhao T, Ye LB. Report on one case of *Lophomonas blattarum* in the pulmonary cyst. *Clin Focus (China)* 2008; 23: 63 (in Chinese).
15. Kang SX, Wang M, Zhang LH, Huang NL. Report on one case of *Lophomonas blattarum* in the pharynx. *Hebei Med J* 2005; 27: 812 (in Chinese).
16. Li CM, Zhou HL. Report on one case of sinuses infection with *Lophomonas blattarum* in newborn. *J Qiqihar Med Coll* 2009; 30: 256-257 (in Chinese).
17. Liu B, Jing LY, Lei DL, Chen SM. Report of one case of lung infection with *Lophomonas blattarum*. *Chinese J Intern Med* 2007; 46: 665 (in Chinese).
18. Liu ZJ, Sun JX, Wang DJ, Liu XF, Cao J, Zhang J. Report of one case of *Lophomonas* infection in the sputum of respiratory infection. *J Pathog Biol (China)* 2007; 2: 12 (in Chinese).
19. Liu ZR, Wang X. Discussion and research of respiratory infection with *Lophomonas blattarum* in 24 patients. *Harbin Med J* 2010; 30: 20 (in Chinese).
20. Lu ZM, Lin YT, Zhang XC, Wang Y, Tang HW, Zhang JX. Report of one case of *Lophomonas blattarum* infection in the maxillary sinus. *Chinese J Parasitol Parasit Dis* 2010; 28: 421-422 (in Chinese).
21. Miao M, Wu DP, Sun AN, Liu YJ, Yan LZ, Wu XJ. Report of one case of pulmonary *Lophomonas blattarum* infection in a patient with allogeneic hematopoietic stem cell transplantation. *Chinese J Intern Med* 2008; 47: 837-838 (in Chinese).
22. Nie X, Yao X, Huang Y. Report of a case of amiodarone pneumonitis with hypermastigote lung infection and review of the literature. *Chinese J Intern Tuberc Respir Dis* 2006; 29: 310-312 (in Chinese).
23. Shi YL, Li LH, Liao Y, Li XN, Huang XY, Liu J, Wang Y, Cao C. Diagnosis and treatment of *Lophomonas blattarum* infection in 26 patients with bacterial pneumonia. *Chinese J Parasitol Parasit Dis* 2007; 25: 430-431 (in Chinese).
24. Sun ZY, Lu GM, Wu XS, Huang W, Wang ZQ, Zheng L, Wang JP. Imaging characteristics of pulmonary *Lophomonas blattarum* infection: case report and literature review. *Chinese J Radiol* 2009; 43: 20-22 (in Chinese).
25. Wang HE, Zhang JR, Shu MZ. Report of one case of *Lophomonas blattarum* infection in the maxillary sinuses. *Chinese J Otorhinolaryngol Integ Med* 1998; 6: 170-172 (in Chinese).
26. Wang Y, Tang Z, Ji S, Zhang Z, Chen J, Cheng Z, Cheng D, Liu Z, Li L. Pulmonary *Lophomonas blattarum* infection in patients with kidney allograft transplantation. *Transpl Int* 2006; 19: 1006-1013.
27. Wu W. Hypermastigote in the bronchoalveolar lavage. *Clin Focus (China)* 2009; 24: 3 (in Chinese).
28. Xia YQ. Hypermastigote found in the sputum of a patient with asthma. *Chinese J Parasitol Parasit Dis* 1997; 15: 417 (in Chinese).
29. Xie BY, Feng GH, Zhu LY, Gong ZH: Three cases of lung infections with *Lophomonas blattarum* and review of the literature. *Chinese J Coal Indust Med* 2008; 11: 136-138 (in Chinese).
30. Xue Q, Li SQ, Jiao WK, Deng XY, Wu JH, Cheng Y. One case report and literature review of pulmonary abscess induced by *Lophomonas blattarum*. *Chinese J Lung Dis* 2012; 5: 149-152 (in Chinese).
31. Yang YP, Dong HE, Wang RF. Report of one case of *Lophomonas blattarum* in the sputum. *Lab Med (China)* 2000; 15: 35 (in Chinese).
32. Yao G, Zhou B, Zeng L. Imaging characteristics of bronchopulmonary *Lophomonas blattarum* infection: case report and literature review. *J Thorac Imaging* 2009; 24: 49-51.
33. Yao GZ, Cheng SK, Chang ZS. Report of one case of bronchopulmonary infection with *Lophomonas blattarum*. *Chinese J Intern Tuberc Respir Dis* 1999; 22: 507 (in Chinese).
34. Zhang F, Li RS, Zhang HX, Cai LM, Wu ZX, Qian YX, Tong DS. Report on two cases of bronchopulmonary infection with hypermastigote. *J Clin Med Pract (China)* 2010; 14: 83-84 (in Chinese).
35. Zhang PY, Zhang GQ, Xie GG, Jin XQ, Zhou X. Different pathogens and prognostic factors of renal transplant recipients with lung infection in 46 cases. *J Clin Rehab Tissue Engin Res (China)* 2009; 13: 931-934 (in Chinese).
36. Zhang RS, Lu L, Zhang DH, Wang X, Liu YX. Report of one case of pulmonary *Lophomonas blattarum* infection in a patient with liver allograft transplantation. *Chinese J Organ Transplant* 2010; 31: 767-768 (in Chinese).
37. Zhang X, Xu L, Wang LL, Liu S, Li J, Wang X. Bronchopulmonary infection with *Lophomonas blattarum*: a case report and literature review. *J Int Med Res* 2011; 39: 944-949.
38. Zhou Y, Xie YP, Li YG, Jin XR, Li XL. Pulmonary *Lophomonas blattarum* infection. *Chinese J Nosocomiol* 2013; 23: 2819-2820 (in Chinese).
39. Zhou YP, Chen XK, Liu H, Huang Lie, Lu XD, Chen X. Clinical analysis of 32 cases of hypermastigote in lower respiratory tract infection. *Chinese J Infect Chemother* 2011; 11: 16-18 (in Chinese).
40. Kudo RR. Protozoology. Illinois, USA. Charles C. Thomas. 1966.
41. Martínez-Girón R, van Woerden HC, Doganci L. *Lophomonas* misidentification in bronchoalveolar lavages. *Intern Med* 2011; 50: 2721.