

Successful Removal of Endobronchial Blood Clots Using Bronchoscopic Cryotherapy at Bedside in the Intensive Care Unit

Hongyeul Lee, M.D., Cho Sun Leem, R.N., Jae Ho Lee, M.D., Choon-Taek Lee, M.D. and Young-Jae Cho, M.D., M.P.H.

Division of Pulmonary and Critical Care Medicine, Department of Internal Medicine, Seoul National University College of Medicine, Seoul National University Bundang Hospital, Seongnam, Korea

Acute airway obstruction after hemoptysis occurs due to the presence of blood clots. These conditions may result in life-threatening ventilation impairment. We report a case of obstruction of the large airway by endobronchial blood clots which were removed using bronchoscopic cryotherapy at the bedside of intensive care unit. A 66-year-old female with endometrial cancer who had undergone chemotherapy, was admitted to the intensive care unit due to neutropenic fever. During mechanical ventilation, the minute ventilation dropped to inadequately low levels and chest radiography showed complete opacification of the left hemithorax. Flexible bronchoscopy revealed large blood clots obstructing the proximal left main bronchus. After unsuccessful attempts to remove the clots with bronchial lavage and forceps extraction, blood clots were removed using bronchoscopic cryotherapy. This report shows that cryotherapy via flexible bronchoscopy at the bedside in the intensive of intensive care unit is a simple and effective alternative for the removal of endobronchial blood clots.

Keywords: Bronchi; Bronchoscopy; Cryotherapy; Hemorrhage

Introduction

An endobronchial blood clot is an unusual, albeit not rare cause of airway obstruction¹⁻³. In spontaneously breathing patients, the clinical features of endobronchial blood clots may

resolve rapidly when blood clots are coughed up. Endobronchial blood clot formation is not always preceded by hemoptysis prior to the development of sudden airway obstruction particularly in patients on mechanical ventilation⁴. We report a case of airway obstruction due to endobronchial blood clots during mechanical ventilation. The clots were removed using bronchoscopic cryotherapy at bedside of intensive care unit (ICU).

Address for correspondence: Young-Jae Cho, M.D., M.P.H.

Division of Pulmonary and Critical Care Medicine, Department of Internal Medicine, Seoul National University College of Medicine, Seoul National University Bundang Hospital, 82 Gumi-ro 173beon-gil, Bundang-gu, Seongnam 463-707, Korea

Phone: 82-31-787-7058, **Fax:** 82-31-787-4070

E-mail: lungdrcho@gmail.com

Received: May 27, 2014

Revised: Jun. 10, 2014

Accepted: Jun. 25, 2014

©It is identical to the Creative Commons Attribution Non-Commercial License (<http://creativecommons.org/licenses/by-nc/3.0/>).

Copyright © 2014

The Korean Academy of Tuberculosis and Respiratory Diseases.

All rights reserved.

Case Report

A 66-year-old female with endometrial cancer who had undergone chemotherapy with doxorubicin and cisplatin 8 days previously, presented to the hospital with neutropenic fever and pancytopenia. She was admitted to the hospital and treated with broad-spectrum antibiotics. Three days after admission, she developed hypoxic respiratory failure requiring intubation (endotracheal tube diameter, 8.0 mm) for acute pulmonary edema and septic shock. During mechanical ventilation, the minute ventilation suddenly dropped to

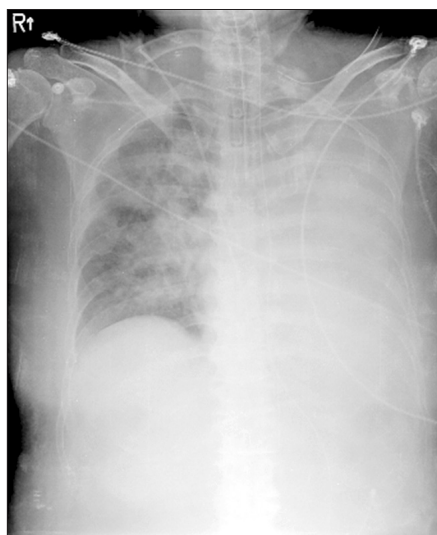


Figure 1. Chest radiography showed a completely opacified left hemithorax.

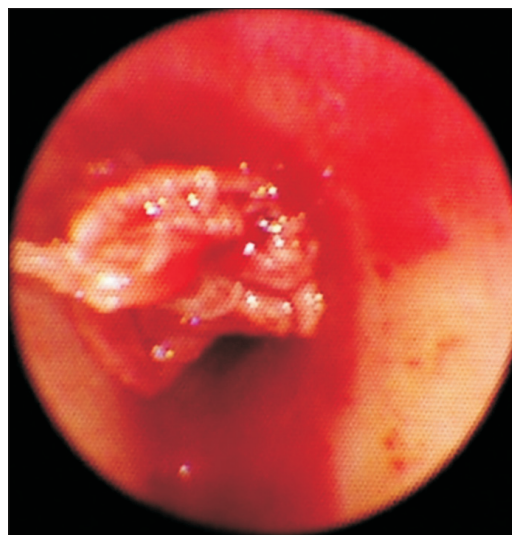


Figure 2. Left main bronchus obstructed by blood clots.

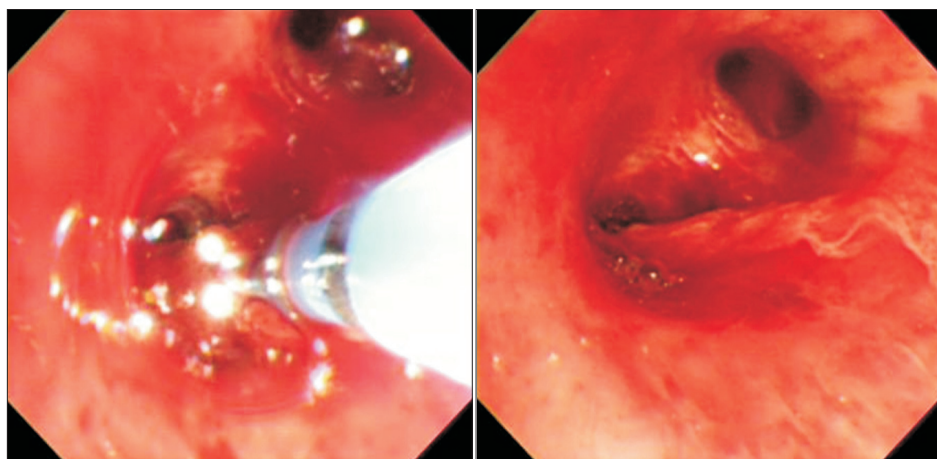


Figure 3. (A, B) Bronchoscopic cryotherapy.

significantly low levels and mildly blood-tinged material was obtained when suctioning the endotracheal tube. Chest radiography revealed no change from previous radiography. Next morning; 12 hours later, chest radiography showed a completely opacified left hemithorax (Figure 1). On auscultation, there were no breath sounds over the left chest. The patient's platelets were 38,000/ μ L. Flexible bronchoscopy (5.9 mm diameter, 2.8 mm channel diameter; BF-1T260; Olympus, Tokyo, Japan) at bedside of ICU revealed a large blood clot obstructing the proximal left main bronchus (Figure 2). Because of the friable structure of the clot, bronchoscopic lavage and forceps extraction were unsuccessful. After repeated attempts to remove the blood clot over one hour, a flexible cryoprobe (2.4 mm diameter; ERBE, Tübingen, Germany) was applied via flexible bronchoscopy to the blood clot and frozen for 10 seconds. The blood clot firmly attached to the probe and was suc-

cessfully removed in four large pieces (Figures 3, 4). A follow-up chest X-ray revealed significant improvement in aeration of the left lung (Figure 5). Fifteen minutes were required to remove the blood clots using bronchoscopic cryotherapy. No further obstructive events occurred. A repeat bronchoscopic evaluation 2 weeks later showed no evidence of the clot and all of the airways were patent. She recovered from septic shock and discharged from hospital on the 24th day.

Discussion

Acute airway obstruction due to the presence of blood clots occurs in a variety of clinical conditions, including complications of respiratory disease, such as tuberculosis, bronchiectasis, bronchial carcinoma, and pulmonary arteriovenous mal-

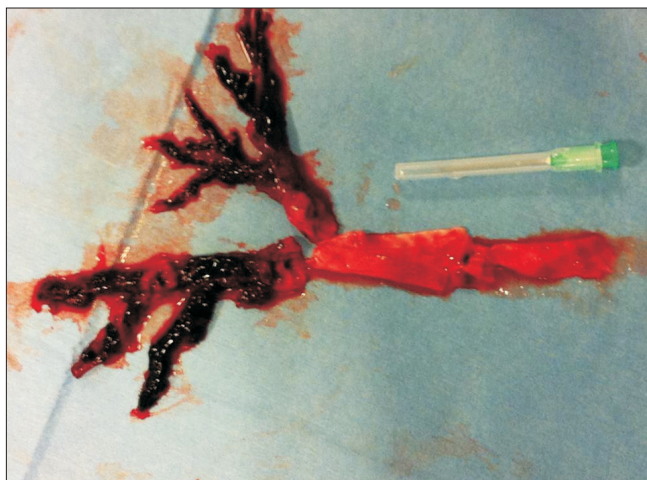

Figure 4. Four large blood clots removed by bronchoscopic cryotherapy.

formations, as well as other causes, such as anticoagulation or pancytopenia¹⁻⁶. These conditions may result in lifethreatening impairment of ventilation. The initial efforts to remove an endobronchial clot should involve flexible bronchoscopic evaluation with saline irrigation and suction⁷. Forceps extraction through the working channel or removal of the clot with the forceps and bronchoscope together may be necessary. If all of the aforementioned methods fail, the next step is rigid bronchoscopy. Rigid bronchoscopy provides greater advantages in terms of direct suctioning and forceps extraction with large rigid bore suction catheters and forceps. However, patients undergoing rigid bronchoscopy need to be extubated before the procedure. Although mechanical ventilation can be performed through a side-port channel, the previously impaired ventilator status may be worse. Furthermore this technique requires the expertise of specialists. Recently, alternative methods for removing endobronchial blood clots have been introduced, such as a Fogarty arterial embolectomy catheter or application of thrombolytics via a flexible bronchoscopy^{8,9}. These methods are only recommended when severe respiratory compromise is present and other alternatives have failed. Bronchoscopic cryotherapy has been used for the biopsy of airway pathology and the ablation of endobronchial lesions, such as a malignant masses or benign tracheal stenosis¹⁰⁻¹². Owing to its freezing characteristics, bronchoscopic cryotherapy can also be used to remove foreign bodies that contain sufficient water, a procedure referred to as cryoextraction¹³. During cryoextraction, tissue or foreign bodies are frozen to the tip of the probe and removed by pulling on the probe together with the bronchoscopy. The development of a thin and flexible cryoprobe has allowed bronchoscopic cryotherapy without the risks associated with general anesthesia and rigid bronchoscopy¹⁴.

In this case of our patient, we removed blood clots that in-

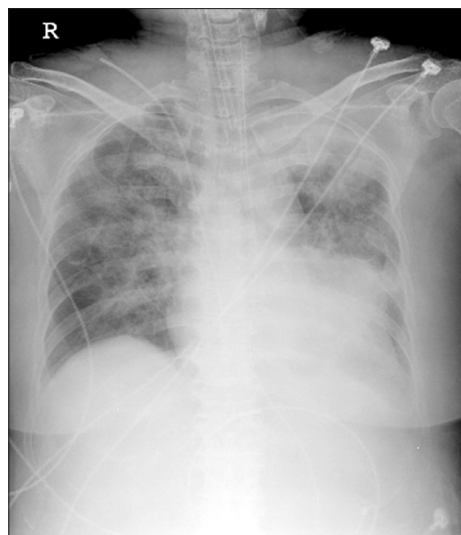

Figure 5. Follow-up chest X-ray revealed significant improvement in the aeration of the left lung.

duced ventilation dysfunction without extubation and general anesthesia, which are both required for rigid bronchoscopy. Furthermore, we conducted bronchoscopic cryotherapy at bedside in ICU. It is foreseeable that removal of blood clots using rigid bronchoscopy may lead to a prolonged procedure time due to the removal of only small pieces of the clot with each forceps bite. In contrast, the bronchoscopic cryotherapy technique allows en-bloc removal of the blood clot. An additional advantage of this technique is that the learning curve to utilize the cryotherapy probe is quite short, and does not require the more extended training needed to master rigid bronchoscopy; something which is not available in many institutions.

Bronchoscopic cryotherapy usually applied after blood clots formation. Previous study described the endoscopic use of cryotherapy to treat actively bleeding diffuse mucosal vascular lesions in gastrointestinal tract¹⁵. Argon plasma coagulation, laser, and other thermal modalities have the potential for deep tissue injury with ulceration and bleeding. Cryotherapy resulted in only superficial tissue damage that usually was completely healed by 3 months in the study. Bronchoscopic cryotherapy could be alternative modality to treat not only blood clots but also active bleeding mucosal lesions in bronchus. One concern about removal endobronchial blood clots using bronchoscopic cryotherapy is that a large blood clot might be difficult to extract through the small sized endotracheal tube.

To our knowledge, this is the first case to report the utilization of bronchoscopic cryotherapy to remove endobronchial blood clots at bed side of ICU. It highlights the utility of cryotherapy probes through flexible bronchoscopy to remove any object, with sufficient water content at bed side of ICU. We

conclude that these properties of the procedure assisted us in the safe and easy removal of endobronchial blood clots at the ICU bedside, and thus, avoided the use of more invasive approaches such as rigid bronchoscopy.

Conflicts of Interest

No potential conflict of interest relevant to this article was reported.

References

1. Mindline J. Massive collapse of the lung complicating haemoptysis. *Br Med J* 1935;2:1201-40.
2. Allen RP, Siefkin AD. Emergency airway clot removal in acute hemorrhagic respiratory failure. *Crit Care Med* 1987;15:985-6.
3. Botnick W, Brown H. Endobronchial urokinase for dissolution of massive clot following transbronchial biopsy. *Chest* 1994;105:953-4.
4. Foucher P, Merati M, Baudouin N, Reybet-Degat O, Camus P, Jeannin L. Fatal ball-valve airway obstruction by an extensive blood clot during mechanical ventilation. *Eur Respir J* 1996;9:2181-2.
5. Sakr L, Dutau H. Massive haemoptysis: an update on the role of bronchoscopy in diagnosis and management. *Respiration* 2010;80:38-58.
6. Manzano-Fernandez S, Pastor FJ, Marin F, Cambronero F, Caro C, Pascual-Figal DA, et al. Increased major bleeding complications related to triple antithrombotic therapy usage in patients with atrial fibrillation undergoing percutaneous coronary artery stenting. *Chest* 2008;134:559-67.
7. Arney KL, Judson MA, Sahn SA. Airway obstruction arising from blood clot: three reports and a review of the literature. *Chest* 1999;115:293-300.
8. Bodenham AR. Removal of obstructing blood clot from the lower airway: an alternative suction technique. *Anaesthesia* 2002;57:40-3.
9. Vajo Z, Parish JM. Endobronchial thrombolysis with streptokinase for airway obstruction due to blood clots. *Mayo Clin Proc* 1996;71:595-6.
10. Roh JH, Park TS, Kim SY, Yoo JW, Park GM, Park SY, et al. Endobronchial hamartoma treated bronchoscopically: report of two cases. *Korean J Med* 2009;77:625-9.
11. Lee SH, Choi WJ, Sung SW, Kim YK, Kim CH, Zo JI, et al. Endoscopic cryotherapy of lung and bronchial tumors: a systematic review. *Korean J Intern Med* 2011;26:137-44.
12. Jung JY, Lee SY, Kim DH, Lee KJ, Lee EJ, Kang EH, et al. Clinical benefits and complications of cryotherapy in advanced lung cancer with central airway obstruction. *Tuberc Respir Dis* 2008;64:272-7.
13. Rubio E, Gupta P, Je S, Boyd M. Cryoextraction: a novel approach to remove aspirated chewing gum. *Ann Thorac Med* 2013;8:58-9.
14. De Weerd S, Noppen M, Remels L, Vanherreweghe R, Meysman M, Vincken W. Successful removal of a massive endobronchial blood clot by means of cryotherapy. *J Bronchol* 2005;12:23-4.
15. Kantsevov SV, Cruz-Correa MR, Vaughn CA, Jagannath SB, Pasricha PJ, Kalloo AN. Endoscopic cryotherapy for the treatment of bleeding mucosal vascular lesions of the GI tract: a pilot study. *Gastrointest Endosc* 2003;57:403-6.