

Management of Recurrent Paravalvular Leakage in a Very High-Risk Patient: A Case Report

Sung Jun Park, M.D., Young Woong Kim, M.D., Jae Suk Yoo, M.D., Ph.D.,
Joon Bum Kim, M.D., Ph.D., Jae Won Lee, M.D., Ph.D.

Interventional device closure has emerged as a less invasive alternative to surgery in the management of paravalvular leakage. However, this procedure involves various problems such as a high probability of residual leakage or hemolysis. Here, we report a case of residual paravalvular leakage despite two attempts at interventional closure in a patient with a history of four previous mitral valve replacements. The fifth operation for the primary repair of paravalvular leakage was performed successfully. Careful evaluation before the procedure and specially designed devices are essential for the interventional treatment of paravalvular leakage. Surgery can be performed adequately in the management of paravalvular leakage even in high-risk patients.

Key words: 1. Mitral valve
2. Mitral valve, replacement
3. Reoperation
4. Recurrence
5. Regurgitation

CASE REPORT

A 71-year-old male was admitted due to progressive dyspnea associated with severe paraprosthesis mitral regurgitation. The patient had previously undergone four mitral valve replacements (MVRs) before this admission. The first two operations had been performed in another hospital at the age of 38 years and 49 years, respectively. Two years before, he had been referred to our hospital for the management of paravalvular leakage 20 years after the second operation, at which he had undergone third MVR using a mechanical prosthesis (ATS, 33 mm; ATS Medical Inc., Minneapolis, MN, USA) through right mini-thoracotomy. Twelve months after the third surgery, the patient again had undergone fourth MVR

using a bioprosthesis (Hancock II, 33 mm; Medtronic Inc.) due to prosthetic valve infective endocarditis (PVIE).

From six weeks following the surgery, the patient experienced progressive dyspnea while receiving postoperative antibiotic treatment for PVIE. Immediate echocardiography reported recurrent severe paraprosthesis regurgitation. Transcatheter device (Amplatzer Vascular Plug II, 10 mm; St. Jude Medical, St. Paul, MN, USA) closure was attempted for the management of paravalvular leakage, but severe remnant leakage was observed in the follow-up echocardiography (Fig. 1A, B). The second attempt at device closure (Amplatzer Vascular Plug II, 12 mm; St. Jude Medical) was made, which successfully eliminated symptoms while leaving only mild paraprosthesis regurgitation (Fig. 1C). After discharge, however, the remnant

Department of Thoracic and Cardiovascular Surgery, Asan Medical Center, University of Ulsan College of Medicine

Received: August 13, 2014, Revised: September 22, 2014, Accepted: September 23, 2014, Published online: February 5, 2015

Corresponding author: Jae Won Lee, Department of Thoracic and Cardiovascular Surgery, Asan Medical Center, University of Ulsan College of Medicine, 88 Olympic-ro 43-gil, Songpa-gu, Seoul 138-736, Korea
(Tel) 82-2-3010-3946 (Fax) 82-2-3010-6966 (E-mail) jwlee@amc.seoul.kr

© The Korean Society for Thoracic and Cardiovascular Surgery. 2015. All right reserved.

© This is an open access article distributed under the terms of the Creative Commons Attribution Non-Commercial License (<http://creativecommons.org/licenses/by-nc/3.0>) which permits unrestricted non-commercial use, distribution, and reproduction in any medium, provided the original work is properly cited.

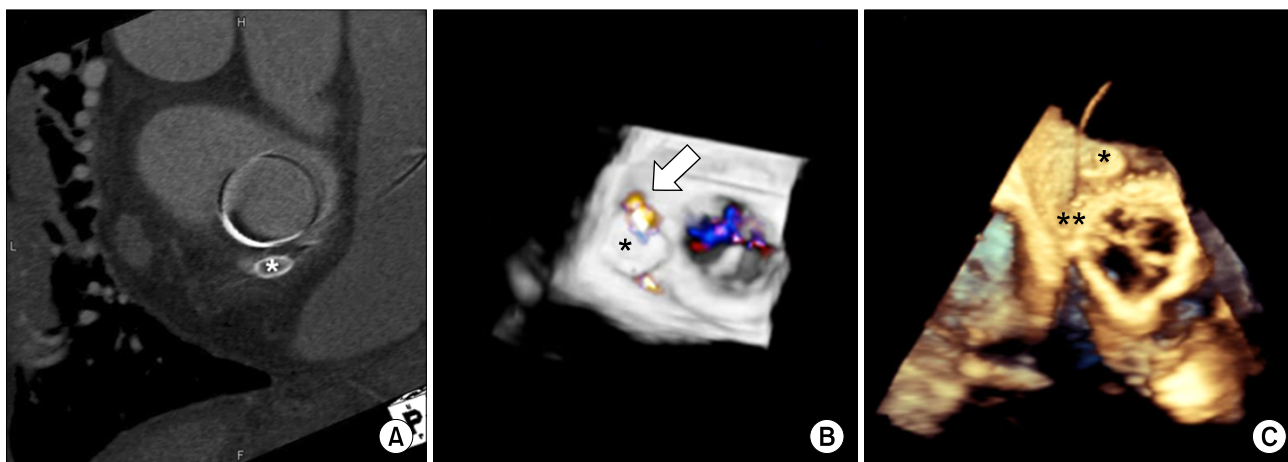


Fig. 1. (A) Enhanced computed tomography findings and (B) three-dimensional transesophageal echocardiography after the first attempt at transcatheter device closure. Remnant paravalvular leakage (arrow) and the vascular plug device (*) that was inserted in the first attempt can be seen. (C) Three-dimensional transesophageal echocardiography shows two vascular plug devices: the first device (*) and the second device (**).

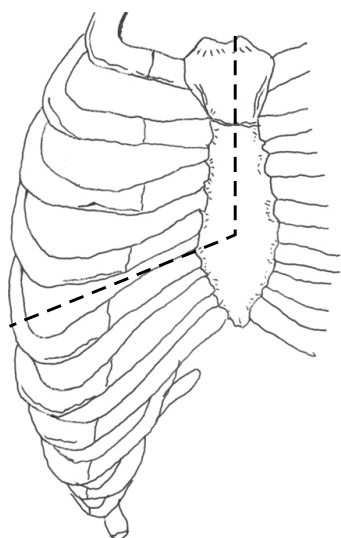


Fig. 2. Right thoracotomy was extended to upper partial sternotomy for aortic cross-clamping.

leakage had progressively increased to a severe degree at the follow-up echocardiography, which was accompanied by the reappearance of severe heart failure symptoms. Furthermore, severe anemia in need of repetitive blood transfusion and development of renal insufficiency related to paraprosthesis hemolysis had gradually aggravated after re-admission. Therefore, the fifth operation was regarded as inevitable, and was finally undertaken 15 months after fourth MVR.

The surgical approach was attempted through a right thoracotomy; however, severe extensive periaortic adhesion precluded aortic clamping by this approach. Then, the incision was extended to an upper partial sternotomy, and the aortic cross-clamping site was finally secured (Fig. 2). Multiple lung lacerations and consequent severe pulmonary hemorrhage occurred during the adhesiolysis, by which the mitral valve (MV) exposure was barely achieved through right atriotomy and atrial septostomy. The sewing ring of the prosthetic MV was partially detached from the posterior annulus, forming a crescent shape defect, and the two vascular plugs were unstably placed on the dehiscence, leaving a residual defect.

After removing the vascular plugs, we decided to repair the defect instead of replacing the prosthetic MV because the rest of the sewing ring was well covered with a neointimal formation and the detached annular calcification was not severe. Primary repair of the paravalvular leakage was performed with multiple pledgeted reinforced sutures on the detached site of the sewing ring. After the closure of interatrial septostomy and right atriotomy, intraoperative transesophageal echocardiography showed no remnant paravalvular leakage.

Although cardiac function was sufficient for weaning from cardiopulmonary bypass (CPB), the actual weaning failed due to respiratory failure attributable to severe lung laceration and massive hemorrhage (Fig. 3). Consequently, venovenous-type

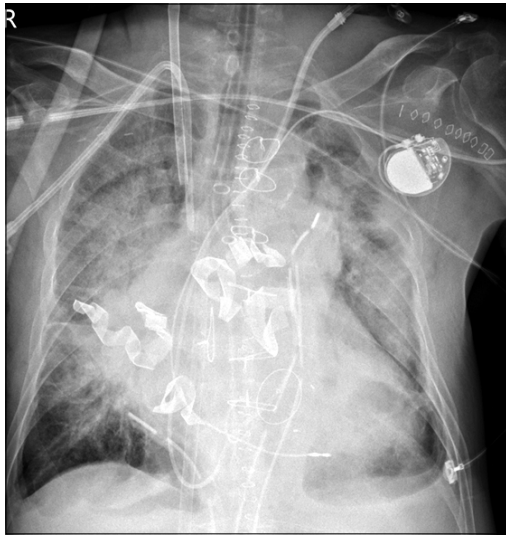


Fig. 3. Immediate postoperative chest radiograph. Venovenous-type extracorporeal membrane oxygenation was applied due to respiratory failure attributable to severe lung laceration and massive hemorrhage.

extracorporeal membrane oxygenation (ECMO) was applied; CPB weaning was then successfully achieved. The patient was successfully weaned off ECMO after 7 days of support. Acute renal failure requiring renal replacement therapy was a complication faced during the ECMO support; this therapy was eventually discontinued after 24 days as the renal function recovered to normal levels. On the echocardiographic follow-ups performed immediately and at 1 month and 2 months after the surgery, neither residual paravalvular leakage nor an abnormal intracardiac flow was observed. The patient was discharged on postoperative day 61 with complete resolution of heart failure symptoms and hemolytic anemia.

DISCUSSION

Paraprosthetic regurgitation is a rare complication after heart valve surgery, but once significant leakage happens, it may result in serious complications such as congestive heart failure, hemolysis, and end-organ damage, ultimately hampering the patient outcomes. Repeated surgical correction has been the traditionally accepted treatment modality for paraprosthetic regurgitation, and the current practice guidelines also recommend surgery for the treatment of this complication

for patients in whom it is feasible [1]. For high-risk patients, however, surgical correction may be associated with serious morbidity and mortality caused by the surgery itself [2]. In this regard, transcatheter device closure has recently emerged as a less-invasive alternative to surgical therapy [3,4].

After the first clinical experience of the transcatheter closure of paravalvular leakage was introduced in 1992 [5], multiple case reports have confirmed its feasibility in selected patients. However, this procedure has been reported to be associated with various problems. For instance, residual leakage was observed in 10 out of 11 sites of device implantation in a series of 11 patients [6]. Furthermore, even when the degree of regurgitation is reduced, there are concerns regarding the significant hemolysis following the procedure [7].

The present case was regarded as technically challenging with a high projected risk of mortality because of multiple previous surgeries and past PVIE. The inflammatory changes and consequent tissue fragility owing to infective endocarditis resulted in recurrent prosthetic valvular detachment. The current recurrence of paravalvular leakage might also be attributable to the sequelae of past PVIE. Therefore, surgical correction of paravalvular regurgitation did not seem to be the best approach at the initial presentation; rather, the other treatment modalities such as heart transplantation or transcatheter device closure were regarded more feasible approaches. Transcatheter closure of paravalvular leakage was attempted twice using the Amplatzer Vascular Plug II, which was not designed for this purpose. This is because the Amplatzer Vascular Plug III (St. Jude Medical), developed for the purpose of paravalvular leakage blockade, has thus far not been commercially available in South Korea. The cylindrical shape of Amplatzer Vascular Plug II appeared to shear the crescent-shaped ring dehiscence by its innate radial expansion force, which gradually enlarged the dehiscence of the sewing ring with the dynamic beating of the heart. As a result, the degree of paraprosthetic regurgitation increased progressively; this was accompanied by the reappearance of severe heart failure symptoms and paraprosthetic hemolysis.

Strict selection of the subject patient and precise understanding of the defect shape and size should precede the transcatheter device closure of paravalvular leakage. Furthermore, specially designed devices are definitely essential for

compactly plugging the defects. In the present case, however, inappropriate application of the closure device and a subsequent mismatch between the defect and the device resulted in procedural failure as well as serious complications. However, the patient was successfully treated with surgical therapy without morbidity. In conclusion, even in high-risk patients, repeated surgical correction may be a feasible and acceptable therapeutic option in the management of paravalvular leakage.

CONFLICT OF INTEREST

No potential conflict of interest relevant to this article was reported.

REFERENCES

1. Nishimura RA, Otto CM, Bonow RO, et al. *2014 AHA/ACC Guideline for the Management of Patients With Valvular Heart Disease: a report of the American College of Cardiology/American Heart Association Task Force on Practice Guidelines*. Circulation 2014;129:e521-643.
2. Akins CW, Bitondo JM, Hilgenberg AD, Vlahakes GJ, Madsen JC, MacGillivray TE. *Early and late results of the surgical correction of cardiac prosthetic paravalvular leaks*. J Heart Valve Dis 2005;14:792-9.
3. Sorajja P, Cabalka AK, Hagler DJ, Rihal CS. *Percutaneous repair of paravalvular prosthetic regurgitation: acute and 30-day outcomes in 115 patients*. Circ Cardiovasc Interv 2011;4:314-21.
4. Nietlispach F, Johnson M, Moss RR, et al. *Transcatheter closure of paravalvular defects using a purpose-specific occluder*. JACC Cardiovasc Interv 2010;3:759-65.
5. Hourihan M, Perry SB, Mandell VS, et al. *Transcatheter umbrella closure of valvular and paravalvular leaks*. J Am Coll Cardiol 1992;20:1371-7.
6. Shapira Y, Hirsch R, Kornowski R, et al. *Percutaneous closure of perivalvular leaks with Amplatzer occluders: feasibility, safety, and shortterm results*. J Heart Valve Dis 2007;16:305-13.
7. Reiss N, Schuett U, Maleszka A, Kleikamp G, Schenk S, Gummert J. *Surgical removal of occluder devices: complications and pitfalls*. Heart Surg Forum 2009;12:E143-6.