ISSN (Print) 0023-4001
ISSN (Online) 1738-0006

**Korean J Parasitol** *Vol. 53, No. 5: 619-625, October 2015*
*http://dx.doi.org/**10.3347/kjp.2015.53.5.619***

▣ ORIGINAL ARTICLE

# Larval *Gnathostoma spinigerum* Detected in Asian Swamp Eels, *Monopterus albus,* Purchased from a Local Market in Yangon, Myanmar

Jong-Yil Chai[1], Woon-Mok Sohn[2,*], Byoung-Kuk Na[2], Jong-Bok Park[3], Hoo-Gn Jeoung[3], Eui-Hyug Hoang[3], Thi Thi Htoon[4], Htay Htay Tin[4]

*[1]Department of Parasitology and Tropical Medicine, Seoul National University College of Medicine, Seoul 03080, Korea; [2]Department of Parasitology and Tropical Medicine, and Institute of Health Sciences, Gyeongsang National University School of Medicine, Jinju 52727, Korea; [3]Korea Association of Health Promotion, Seoul 07649, Korea; [4]National Health Laboratory, Yangon 11191, Myanmar*

**Abstract:** The present study was performed to determine the infection status of swamp eels with *Gnathostoma* sp. larvae in Myanmar. We purchased total 37 Asian swamp eels, *Monopterus albus*, from a local market in Yangon in June and December 2013 and 2014. All collected eels were transferred with ice to our laboratory and each of them was examined by the artificial digestion technique. A total of 401 larval gnathostomes (1-96 larvae/eel) were detected in 33 (89.2%) swamp eels. Most of the larvae (n = 383; 95.5%) were found in the muscle. The remaining 18 larvae were detected in the viscera. The advanced third-stage larvae ($AdL_3$) were 2.3-4.4 mm long and 0.25-0.425 mm wide. The characteristic head bulb (0.093 × 0.221 mm in average size) with 4 rows of hooklets, muscular long esophagus (1.025 mm), and 2 pairs of cervical sacs (0.574 mm) were observed by light microscopy. The average number of hooklets in the 1st, 2nd, 3rd, and 4th rows was 41, 45, 48, and 51, respectively. As scanning electron microscopic findings, the characteristic 4-5 rows of hooklets on the head bulb, a cervical papilla, tegumental spines regularly arranged in the transverse striations, and an anus were well observed. Based on these morphological characters, they were identified as the $AdL_3$ of *Gnathostoma spinigerum*. By the present study, it has been confirmed for the first time that Asian swamp eels, *M. albus*, from Yangon, Myanmar are heavily infected with *G. spinigerum* larvae.

Key words: *Gnathostoma spinigerum*, advanced 3rd-stage larva ($AdL_3$), Asian swamp eel, *Monopterus albus*, Yangon, Myanmar

## INTRODUCTION

Nematodes of the genus *Gnathostoma* are clinically important as etiologic agents of foodborne parasitic zoonoses in humans [1]. More than 20 species have been reported in this genus from various parts of the world; however, about 13 species are currently recognized as valid ones. Among them, 6 species, namely, *G. spinigerum, G. binucleatum, G. doloresi, G. hispidum, G. malaysiae,* and *G. nipponicum* have been reported to infect humans. *G. spinigerum* is the type species and the main cause of human infections, which was first documented in 1836 in Thailand [1,2]. Gnathostomiasis, infection due to *Gnathostoma* spp. larvae, is clinically characterized as creeping eruption in subcutaneous and intermuscular tissues by migrating larvae. Occasionally, the larvae are also known to invade the lungs, eyes, and even the brain [1,2].

In the Union of Myanmar (Myanmar), human gnathostomiasis is rare whereas it is highly prevalent in Thailand, a neighboring country of Myanmar. Only a few reports have been available on human gnathostomiasis in Myanmar since 2 ocular cases were described in 1960 and 1968 [3,4]. Two cases of subcutaneous tissue infections in 2 Japanese men who visited Myanmar were reported; they had eaten raw freshwater shrimps [5]. Subsequently, an outbreak of human gnathostomiasis due to *G. spinigerum* was reported among 60 Korean immigrants who consumed raw freshwater fish in Yangon [6]. In addition, a case of cutaneous gnathostomiasis was described in a French traveler as an imported case from Myanmar to France [7]. On the other hand, studies on larval gnathostome infections in the second intermediate host were undertaken only 2 times in fish hosts in Myanmar [6,8]. Thus, we carried out to know the infection status of *Gnathostoma* larvae

• Received 16 June 2015, revised 23 July 2015, accepted 27 July 2015.
* Corresponding author (wmsohn@gnu.ac.kr)

© 2015, Korean Society for Parasitology and Tropical Medicine
This is an Open Access article distributed under the terms of the Creative Commons Attribution Non-Commercial License (http://creativecommons.org/licenses/by-nc/3.0) which permits unrestricted non-commercial use, distribution, and reproduction in any medium, provided the original work is properly cited.

in Asian swamp eels, which have been known to be a most susceptible fish host, purchased in a local fish market of Yangon, Myanmar.

## MATERIALS AND METHODS

A total of 37 Asian swamp eels, *Monopterus albus*, were purchased in a local fish market of Yangon in June and December 2013 and 2014. They were transferred with ice to the laboratory of the Department of Parasitology and Tropical Medicine, Gyeongsang National University School of Medicine, Jinju, Korea and measured the length and weight of the fish (Tables 1, 2). Individual fish was ground finely with a mortar with a pestle or a grinder, and the ground fish meat was mixed with artificial gastric juice followed by incubation at 36°C for 2 hr. The digested material was filtered through a sieve (5×5 mm of mesh), and washed with 0.85% saline until the supernatant became clear. The sediment was carefully examined under a stereomicroscope, and then gnathostome larvae were collected. Some of the larvae were fixed with 10% hot formalin and mounted with glycerin-jelly after clearing in alcohol-glycerin solution to observe the morphological characteristics.

To observe the surface ultrastructure of gnathostome larvae,

**Table 1.** Infection status with *Gnathostoma spinigerum* larvae in Asian swamp eels (*Monopterus albus*) purchased from a local market in Yangon, Myanmar (2013)[a]

| Swamp eel | Length of eel (cm) | Weight of eel (g) | No. of larvae detected in | | |
|---|---|---|---|---|---|
| | | | Muscle | Viscera | Total |
| 1 | 84 | 451 | 9 | 0 | 9 |
| 2 | 80 | 480 | 6 | 0 | 6 |
| 3 | 75 | 362 | 37 | 0 | 37 |
| 4 | 62 | 284 | 90 | 6 | 96 |
| 5 | 60 | 200 | 3 | 0 | 3 |
| 6 | 59 | 298 | 2 | 0 | 2 |
| 7 | 57 | 204 | 8 | 0 | 8 |
| 8 | 54 | 180 | 1 | 0 | 1 |
| 9 | 54 | 195 | 0 | 0 | 0 |
| 10 | 50 | 127 | 0 | 0 | 0 |
| 11 | 46 | 94 | 1 | 0 | 1 |
| 12 | 45 | 89 | 0 | 0 | 0 |
| 13 | 43 | 95 | 3 | 0 | 3 |
| 14 | 43 | 83 | 3 | 0 | 3 |
| 15 | 41 | 78 | 4 | 0 | 4 |
| 16 | 40 | 77 | 1 | 0 | 1 |
| 17 | 39 | 68 | 3 | 0 | 3 |
| Total | 55 | 198 | 171 | 6 | 177 |

[a]The sum-up data of 2013 and 2014 are presented at the footnote of Table 2.

**Table 2.** Infection status with *G. spinigerum* larvae in Asian swamp eels purchased from a local market of Yangon, Myanmar (2014)[a]

| Swamp eel | Length of eel (cm) | Weight of eel (g) | No. of larvae detected in | | |
|---|---|---|---|---|---|
| | | | Muscle | Viscera | Total |
| 1 | 60 | 177 | 74 | 3 | 77 |
| 2 | 58 | 192 | 22 | 0 | 22 |
| 3 | 55 | 151 | 9 | 0 | 9 |
| 4 | 53 | 157 | 0 | 2 | 2 |
| 5 | 53 | 111 | 2 | 0 | 2 |
| 6 | 51 | 159 | 8 | 0 | 8 |
| 7 | 51 | 146 | 10 | 1 | 11 |
| 8 | 50 | 105 | 1 | 0 | 1 |
| 9 | 50 | 111 | 2 | 0 | 2 |
| 10 | 42 | 86 | 0 | 0 | 0 |
| 11 | 51 | 146 | 1 | 0 | 1 |
| 12 | 50 | 104 | 1 | 0 | 1 |
| 13 | 48 | 109 | 4 | 0 | 4 |
| 14 | 47 | 102 | 30 | 2 | 32 |
| 15 | 46 | 120 | 2 | 0 | 2 |
| 16 | 46 | 100 | 1 | 0 | 1 |
| 17 | 45 | 91 | 16 | 1 | 17 |
| 18 | 45 | 89 | 26 | 3 | 29 |
| 19 | 44 | 89 | 1 | 0 | 1 |
| 20 | 41 | 86 | 2 | 0 | 2 |
| Total | 49 | 122 | 212 | 12 | 224 |

[a]Summing-up the data in 2013 (Table 1) and 2014, a total of 401 gnathostome larvae were detected from 33 infected eels (12.2 larvae/eel); 383 (95.5%) were detected in muscles and 18 (4.5$) were in viscera. The mean length of the eels was 52 cm and the mean weight was 157 g.

**Table 3.** Seasonal tendency of occcurrence of *G. spinigerum* larvae in Asian swamp eels purchased from a local market of Yangon, Myanmar

| Month & year examined | No.of eels examined | No. (%) of eels infected | No. of larvae detected | | |
|---|---|---|---|---|---|
| | | | Total | Range | Average |
| June 2013 | 10 | 7 (70.0) | 160 | 1-96 | 22.9 |
| December 2013 | 7 | 7 (100) | 17 | 1-4 | 2.4 |
| June 2014 | 10 | 9 (90.0) | 134 | 1-77 | 14.9 |
| December 2014 | 10 | 10 (100) | 90 | 1-32 | 9.0 |
| Total | 37 | 33 (89.2) | 401 | 1-96 | 12.2 |

some worms were washed several times in 0.2 M cacodylate buffer (pH 7.2) and fixed in 2.5% glutaraldehyde at 4°C. After washing 3 times with the same buffer, they were dehydrated through a graded alcohol series (50%, 70%, 80%, 90%, 95%, and absolute alcohol), dried in a critical point dryer, coated with gold in the JFC-1100E ion sputtering device (JEOL, Tokyo, Japan), and observed using a scanning electron microscope (SEM) (Philips XL-30S, Amsterdam, Netherlands) with an accelerating voltage of 15 kV.

## RESULTS

A total of 401 larval gnathostomes (1-96 larvae/eel) were detected in 33 (89.2%) of 37 swamp eels examined. Most of them (383 larvae: 95.5%) were found in the muscle. The remaining 18 larvae (4.5%) were detected in the viscera (Tables 1, 2). The average number of larvae was 12.2 per infected eel. The infection status by the surveyed year (season) is shown in Table 3.

The early 3rd-stage larvae ($EL_3$) were 0.85-1.375 mm in

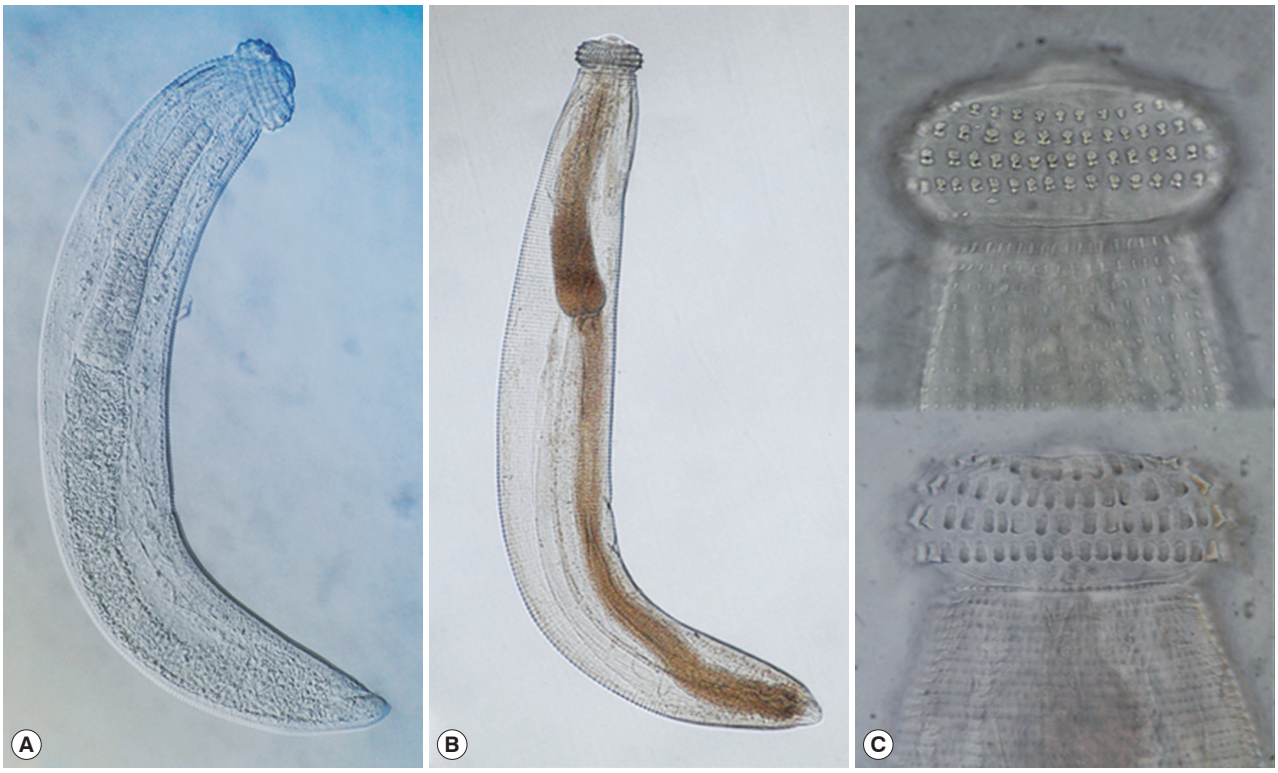


**Fig. 1.** (A) Early 3rd-stage larva ($EL_3$). (B) Advanced third-stage larva ($AdL_3$). (C) Head bulbs of an $AdL_3$ of *G. spinigerum* detected in Asian swamp eels, *Monopterus albus*, from Yangon, Myanmar. They commonly have a characteristic head bulb, muscular esophagus (E), intestine (I), and 4 cervical sacs (arrow mark). Scale bars are 0.3 (A), 1.0 (B), and 0.1 (C) mm, respectively.

**Table 4.** Measurements[a] of *G. spinigerum* larvae detected in Asian swamp eels purchased from a local market of Yangon, Myanmar

| Organs | | $EL_3$ | $AdL_3$ |
|---|---|---|---|
| Body | Length | 0.850-1.375 (1.102) | 2.300-4.400 (3.347) |
| | Width | 0.095-0.150 (0.132) | 0.250-0.425 (0.366) |
| Esophagus | Length | 0.250-0.380 (0.331) | 0.630-1.220 (1.025) |
| Cervical sac | Length | 0.195-0.305 (0.237) | 0.330-0.750 (0.574) |
| Head bulb | Length | 0.035-0.065 (0.050) | 0.075-0.115 (0.093) |
| | Width | 0.085-0.150 (0.115) | 0.165-0.250 (0.221) |
| No. of hooklets on the head bulb | 1st row | 30-34 (32) | 38-44 (41) |
| | 2nd row | 34-38 (35) | 42-50 (45) |
| | 3rd row | 36-42 (39) | 44-52 (48) |
| | 4th row | 38-44 (42) | 48-54 (51) |

[a]Total 8 early 3rd-stage larvae ($EL_3$) and 29 advanced 3rd-stage larvae ($AdL_3$) were measured.




**Fig. 2.** Scanning electron microscopic (SEM) view of an $AdL_3$ of *G. spinigerum* detected in Asian swamp eels, *Monopterus albus*, from Yangon, Myanmar. (A) Whole body showing a head bulb, numerous transverse striations with cuticular spines, a cervical papilla (encircled), and an anus. (B, C) Anterior portion bearing the head bulb with 4 transverse rows of hooklets. Each hooklet with a sharp point somewhat curved posteriorly. A cervical papilla located between 9th and 10th transverse striations (encircled). (D) Tegumental surface at the anterior 1/3 level having transverse striations with numerous cuticular spines. (E) Tegumental surface in the middle portion having transverse striations with cuticular spines more or less sparsely distributed than in the anterior portion. (F) Posterior portion of a larva having smaller cuticular spines sparsely distributed on the transverse striations and an anus.

length and 0.095-0.15 mm in width. They had a characteristic head bulb (0.050×0.115 mm in average size) with 4 rows of hooklets, a muscular long esophagus (0.25-0.38 mm in length), and 2 pairs of cervical sacs (0.195-0.305 mm in length). The average number of hooklets in the 1st, 2nd, 3rd, and 4th rows was 32, 35, 39, and 42, respectively (Fig. 1A) (Table 4).

The advanced 3rd-stage larvae ($AdL_3$) were 2.3-4.4 mm long and 0.25-0.425 mm wide. They had a characteristic head bulb (0.093×0.221 mm in average size) with 4 rows (rarely 5 rows) of hooklets, a muscular long esophagus (0.63-1.22 mm long), and 2 pairs of cervical sacs (0.33-0.75 mm long). The average number of hooklets in the 1st, 2nd, 3rd, and 4th row was 41, 45, 48, and 51, respectively (Fig. 1B, C) (Table 4).

In SEM observations, $AdL_3$ possessed a characteristic head bulb with 4 transverse rows of hooklets and cuticular spines on the transverse striations of body surface (Fig. 2A). A pair of lips was located at the anterior end of the body. The hooklets on the head bulb were somewhat curved posteriorly and had a sharp-pointed end. A cervical papilla was located between the 9th and 10th transverse striations (Fig. 2B, C). Cuticular spines with a sharp point were regularly arranged on the transverse striations, and they were densely distributed on the body surface of the anterior part and gradually decreased in size and number posteriorly (Fig. 2D, E). Near the posterior end of larvae, smaller cuticular spines were more sparsely distributed and an anus was seen (Fig. 2F).

## DISCUSSION

The Asian swamp eel, *M. albus*, has been frequently examined as a susceptible fish host of *G. spinigerum* in Southeast Asian countries such as Thailand and Vietnam, and even in USA [10-15]. Sieu et al. [10] surveyed on the prevalence and intensity of *G. spinigerum* $AdL_3$ in wild swamp eels collected monthly from 2 localities of Vietnam, i.e., Long An Province and Hoc Mon District of Ho Chi Minh City. Saksirisampant and Thanomsub [11] examined total 1,420 livers of swamp eels from a farm (1,037 eels) in Aranyaprathet District, Sa Kaeo Province, Thailand and those (383 wild-caught eels) from Min Buri District, Bangkok, Thailand. Cole et al. [15] investigated 47 imported swamp eels purchased in fish markets and 67 wild-caught specimens in USA. In Myanmar, there has been no study on larval gnathostome infections in swamp eels. Instead, small scale surveys to determine the source of human infections was performed 2 times on other kinds of fish, i.e., catfish, freshwater bream (*Tilapia* sp.), and snakeheads [6,8]. Accordingly, it has been confirmed for the first time in this study that Asian swamp eels, *M. albus*, from Yangon, Myanmar are heavily infected with *G. spinigerum* larvae.

We examined only 37 swamp eels collected in a local fish market of Yangon through 4 different times in June and December 2013 and 2014. Because of limitation in transportation of fish specimens with ice from Myanmar to Korea, we could not investigate an enough number of fish for 2 years. Therefore, we were unable to see the seasonal infection trend of larval gnathostomes in Asian swamp eels in Myanmar. However, we could see that the prevalence was higher in December and the infection intensity was higher in June. In Vietnam, it is known that both the prevalence and infection intensity were higher during the latter part of the rainy season (August-October) in Vietnam [9], and in August in Thailand [11,12]. The discrepancy between the prevalence and infection intensity may have been caused by the small number of fish examined in this study. Further studies should be performed to know the seasonal prevalence and endemicity of gnathostome infections in Asian swamp eels from Myanmar.

The species determination of larval *Gnathostoma* ($AdL_3$) is mainly dependent on the number and distribution of hooklets on the head bulb. In the case of *G. spinigerum*, the number of hooklets in each row is more than 40 and reveals an increasing trend posteriorly [1]. In our specimens, the average number of hooklets on the head bulb was 41, 45, 48, and 51, and the larval gnathostomes were identified as the $AdL_3$ of *G. spinigerum*.

In the present study, 401 (12.2 per fish infected) larval gnathostomes were detected from 33 (89.2%) swamp eels. Sieu et al. [10] detected 1,008 (8.1 per infected fish) larvae in 125 (4.4%) out of 2,830 wild swamp eels collected in 2 localities, i.e., Long An province and Hoc Mon district of Ho Chi Minh City, southern Vietnam. Saksirisampant and Thanomsub [11] harvested 674 (3.7 per infected fish) larvae in 184 (13.0%) out of 1,420 livers of swamp eels from a farm (1,037 eels) in Aranyaprathet District, Sa Kaeo Province and those (383 wild-caught eels) from Min Buri District, Bangkok, Thailand. Cole et al. [15] found 36 live $AdL_3$ of *G. spinigerum* in 13 (27.7%) out of 47 swamp eels which were imported to USA. The prevalence and intensity of infections are much higher in swamp eels from Myanmar than in those from Vietnam and Thailand, and even in imported ones to USA. Based on aforementioned findings, there is a potential risk of human gnathostomiasis in

Myanmar if improperly cooked freshwater fish, especially Asian swamp eels, are consumed.

The predilection site of *G. spinigerum* larvae is known to be the liver of swamp eels. So, some workers in Thailand examined only the livers of swamp eels to evaluate the endemicity of larval *G. spinigerum* infections [11-14]. Rojekittikhun et al. [12] reported the distribution pattern of *G. spinigerum* larvae in the livers and muscles of swamp eels. They recovered 57.0% of the total number of larvae (n=5,532) in the livers of 555 eels infected, and 43.0% in the muscles. Cole et al. [15] recovered total 36 *G. spinigerum* larvae from 47 Asian swamp eels imported to USA. Among them, 21 (58.3%) were collected in the liver, 7 (19.4%) in the muscle, 5 (13.8%) in the gastrointestinal tract, and 3 (8.3%) in kidneys. However, in the present study, most of the larvae (95.5%) were found in the muscles of eels, and the remainder (4.5%) was detected in the viscera. At any rate, although the liver is a predilection site of *G. spinigerum* larvae in swamp eels, it seems less reasonable that epidemiological investigations were performed only on livers for surveys on the infection status of *G. spinigerum* larvae in swamp eels.

As the second intermediate or paratenic hosts (the source of human infection) of *G. spinigerum*, several species of fish including the swamp eel, 3 crab spp., 8 amphibian spp., 5 snake spp., 23 bird spp., and 6 mammalian spp. have been reported in the literature [1]. Regarding larval gnathostome infections in Myanmar, Chai et al. [6] examined 10 freshwater fish, including 6 catfish, 3 *Tilapia* sp., and 1 snakehead to reveal the source of human infections in Yangon, Myanmar. They recovered 2 $AdL_3$ of *G. spinigerum* in 2 of 6 catfish. Jung et al. [8] collected 2 $AdL_3$ of *G. spinigerum* in 1 out of 15 snakeheads, *Channa striatus*, from a local market in a suburban area of Naypyidaw, Myanmar. Accordingly, 3 species of fish, i.e., *Parasilurus* sp. (catfish), *C. striatus* (snakehead), and *M. albus* (Asian swamp eels), have been confirmed to be the second intermediate or paratenic host of *G. spinigerum* in Myanmar. Other possible intermediate or paratenic hosts including susceptible fish should be systematically examined in the near future in Myanmar. People having the food habit to consume raw or undercooked flesh of fish like Korean and Japanese should pay attention to gnathostome infections in Myanmar.

## ACKNOWLEDGMENTS

We thank Jung-A Kim and Hee-Joo Kim, Department of Parasitology and Tropical Medicine, Gyeongsang National University School of Medicine, Jinju, Korea, for their help in the examination of fish. We also thank members of Korea Association of Health Promotion (KAHP) participated in the Korea International Cooperation Agency (KOICA) NGO Project: Health Promotion Project for the Elementary School Children in Yangon, Myanmar (2013-2015).

## CONFLICT OF INTEREST

The authors have no conflicts of interest concerning the work reported in this paper.

## REFERENCES

1. Miyazaki I. Section III. Nematode Zoonoses. 33. Gnathostomiasis. An Illustrated Book of Helminthic Zoonoses. Tokyo, Japan. International Medical Foundation of Japan. 1991, pp. 368-409.
2. Herman JS, Chiodini PL. Gnathostomiasis, another emerging imported disease. Clin Microbiol Rev 2009; 22: 484-492.
3. Gyi K. Intra-ocular gnathostomiasis. Br J Ophthalmol 1960; 44: 42-45.
4. Khin T. Intra-ocular gnathostomiasis. Br J Ophthalmol 1968; 52: 57-60.
5. Nomura Y, Nagakura K, Kagei N, Tsutsumi Y, Araki K, Sugawara. M. Gnathostomiasis possibly caused by *Gnathostoma malaysiae*. Tokai J Exp Clin Med 2000; 25: 1-6.
6. Chai JY, Han ET, Shin EH, Park JH, Chu JP, Hirota M, Nakamura F, Nawa Y. An outbreak of gnathostomiasis among Korean emigrants in Myanmar. Am J Trop Med Hyg 2003; 69: 67-73.
7. Develoux M, Dekumyoy P, Baygon E, Aractingi S. Imported gnathostomiasis acquired in Myanmar. Med Mal Infect 2006; 36: 340-342 (in French).
8. Jung BK, Lee JJ, Pyo KH, Kim HJ, Jeong HG, Yoon CH, Lee SH, Shin EH, Chai JY. Detection of *Gnathostoma spinigerum* third-stage larvae in snakeheads purchased from a central part of Myanmar. Korean J Parasitol 2008; 46: 285-288.
9. Sieu TP, Dung TT, Nga NT, Hien TV, Dalsgaard A, Waikagul J, Murrell KD. Prevalence of *Gnathostoma spinigerum* infection in wild and cultured swamp eels in Vietnam. J Parasitol 2009; 95: 246-248.
10. Le XT, Rojekittikhun W. A survey of infective larvae of *Gnathostoma* in eels sold in Ho Chi Minh City. Southeast Asian J Trop Med Public Health. 2000; 31: 133-137.
11. Saksirisampant W, Thanomsub BW. Positivity and intensity of *Gnathostoma spinigerum* infective larvae in farmed and wild-caught swamp eels in Thailand. Korean J Parasitol 2012; 50: 113-118.
12. Rojekittikhun W, Chaiyasith T, Butraporn P. *Gnathostoma* infection in fish caught for local consumption in Nakhon Nayok

Province, Thailand. II. Seasonal variation in swamp eels. Southeast Asian J Trop Med Public Health 2004; 35: 786-791.
13. Sugaroon S, Wiwanitkit V. *Gnathostoma* infective stage larvae in swamp eels (*Fluta alba*) at a metropolitan market in Bangkok, Thailand. Ann Clin Lab Sci 2003; 33: 94-96.
14. Saksirisampant W, Kulkaew K, Nuchprayoon S, Yentakham S, Wiwanitkit V. A survey of the infective larvae of *Gnathostoma spinigerum* in swamp eels bought in a local market in Bangkok, Thailand. Ann Trop Med Parasitol 2002; 96: 191-195.
15. Cole RA, Choudhury A, Nico LG, Griffin KM. *Gnathostoma spinigerum* in live Asian swamp eels (*Monopterus* spp.) from food markets and wild populations, United States. Emerg Infect Dis 2014; 20: 634-642.