

# Surgical endodontic management of infected lateral canals of maxillary incisors

Ji-Hyun Jang<sup>1a</sup>, Jung-Min Lee<sup>2a</sup>, Jin-Kyu Yi<sup>3</sup>, Sung-Baik Choi<sup>4</sup>, Sang-Hyuk Park<sup>1,5</sup>

<sup>1</sup>Department of Conservative Dentistry, Kyung Hee University Dental Hospital at Gangdong, Seoul, Korea

<sup>2</sup>Department of Conservative Dentistry, Graduate School, Kyung Hee University, Seoul, Korea

<sup>3</sup>Department of Conservative Dentistry, Kyung Hee University Dental Hospital, Seoul, Korea

<sup>4</sup>Pastel Dental Clinic, Seoul, Korea

<sup>5</sup>Oral Biology Research Institute, School of Dentistry, Kyung Hee University, Seoul, Korea

This case report presents surgical endodontic management outcomes of maxillary incisors that were infected via the lateral canals. Two cases are presented in which endodontically-treated maxillary central incisors had sustained lateral canal infections. A surgical endodontic treatment was performed on both teeth. Flap elevation revealed vertical bone destruction along the root surface and infected lateral canals, and microscopy revealed that the lateral canals were the origin of the lesions. After the infected lateral canals were surgically managed, both teeth were asymptomatic and labial fistulas were resolved. There were no clinical or radiographic signs of surgical endodontic management failure at follow-up visits. This case report highlights the clinical significance and surgical endodontic management of infected lateral canal of maxillary incisor. It is important to be aware of root canal anatomy variability in maxillary incisors. Maxillary central incisors infected via the lateral canal can be successfully managed by surgical endodontic treatment. (*Restor Dent Endod* 2015;40(1): 79-84)

**Key words:** Apical ramification; Lateral canal; Root canal anatomy; Surgical endodontic treatment

Received June 11, 2014;  
Accepted August 21, 2014.

<sup>1</sup>Jang JH; Park SH, Department of Conservative Dentistry, Kyung Hee University Dental Hospital at Gangdong, Seoul, Korea

<sup>2</sup>Lee JM, Department of Conservative Dentistry, Graduate School, Kyung Hee University, Seoul, Korea

<sup>3</sup>Yi JK, Department of Conservative Dentistry, Kyung Hee University Dental Hospital, Seoul, Korea

<sup>4</sup>Choi SB, Pastel Dental Clinic, Seoul, Korea

<sup>5</sup>Park SH, Oral Biology Research Institute, School of Dentistry, Kyung Hee University, Seoul, Korea

\*Correspondence to  
Sang-Hyuk Park, DMD, MSD, PhD.  
Professor, Department of Conservative Dentistry, School of Dentistry, Kyung Hee University, 1 Hoegi-dong, Dongdaemoon-gu, Seoul, Korea 130-701  
TEL, +82-2-440-7500; FAX, +82-2-440-7549; E-mail, shpark94@khu.ac.kr

<sup>a</sup>Ji-Hyun Jang and Jung-Min Lee contributed equally to this work as first authors.

This is an Open Access article distributed under the terms of the Creative Commons Attribution Non-Commercial License (<http://creativecommons.org/licenses/by-nc/3.0>) which permits unrestricted non-commercial use, distribution, and reproduction in any medium, provided the original work is properly cited.

©Copyrights 2015. The Korean Academy of Conservative Dentistry.

## Introduction

The goal of apical periodontitis treatment has been to eliminate or substantially reduce microbial infection and to prevent re-infection by creating a tight seal of the root canal system.<sup>1,2</sup> Bacteria involved in persistent infections may sometimes colonize the dentinal tubules of the main canal or the apical third of the canal near the apical foramen.<sup>3-5</sup> In these areas, root canal instrumentation, including canal enlargement and shaping, could improve the canal disinfection. Nevertheless, in most clinical failures in which the root canals were properly managed, the bacteria are still present in the root canal system including in the dentinal tubules, isthmi, lateral canals, and apical ramifications.<sup>3-9</sup>

Lateral canals and apical ramifications of the main root canal are formed after a localized fragmentation of the epithelial root sheath develops, leaving a small gap, or when blood vessels that run from the dental sac through the dental papilla persist.<sup>10,11</sup> Lateral canals are located in the coronal or middle third of the root, and usually extend horizontally from the main canal. Apical ramifications refer to the branching of the main canal into multiple accessory canals at or near the apex.<sup>3</sup> A study reported that 70% of the root apex of teeth with refractory apical periodontitis that did not respond

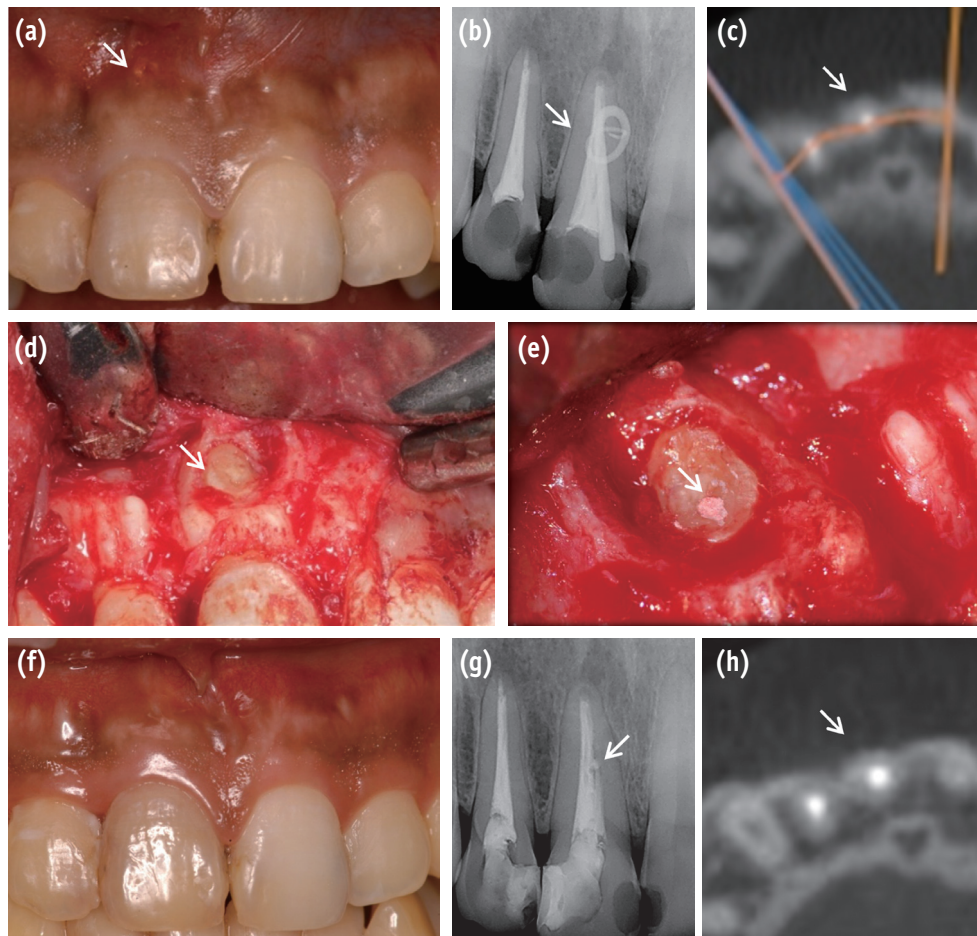
to root canal treatment had significant apical ramifications within their root canal systems.<sup>12</sup> With maxillary central incisors, the incidences of anatomical complexity including lateral canals and apical ramifications have been reported in a wide range from 24 to 60%.<sup>3,5</sup> Although there has been continuous debate about the correlation between harbored bacteria in the root canal system and the outcome of root canal treatment, it is obvious that open and large lateral canals could create a two-way passage of bacteria and tissue degradation products between the root canal space and periodontal tissue.<sup>13-16</sup>

This case report presents surgical endodontic management outcomes of maxillary incisors which were infected via the lateral canals.

## Case Reports

### Case 1

A 28 year-old man reported to the Department of Conservative Dentistry at Kyung Hee University Dental Hospital at Gangdong with the chief complaint of sinus tract that was adjacent to tooth #11 (Figure 1a). Due to the extensive caries, the patient had received an endodontic treatment and resin restoration 10 years ago. The patient did not report any spontaneous pain, and the tooth was asymptomatic to percussion and palpation. The sinus tract was traced with a gutta percha cone, which indicated that it was not toward the apical third



**Figure 1.** Preoperative clinical and radiographic appearances. (a) Intraoral view of buccal sinus tract (arrow); (b) Periapical radiograph of the maxillary right central incisor with a gutta-percha cone tracing the sinus tract; (c) CBCT image of the labial bone resorption (arrow). Intraoperative photographs; (d) Loss of bone adjacent to the lateral canal (arrow); (e) Obturated canal with IRM (arrow). Postoperative clinical and radiographic appearances at follow-up; (f) At the 1 month follow-up, the labial fistula was resolved; (g) A 12 month follow-up periapical radiograph. Obturated lateral canal (arrow); (h) 18 month follow-up CBCT image showing formation of the alveolar bone (arrow) in the labial area of the maxillary right central incisor.

but toward the middle third of tooth #11 (Figure 1b). A crack or anatomic variation was suspected and cone-beam computed tomography (CBCT, i-CAT, Imaging Sciences International Inc., Hatfield, PA, USA) was performed as a complementary examination. The CBCT image showed paradicular radiolucency which was located in the middle root surface of tooth #11, and a crack or vertical root fracture was not observed (Figure 1c). Based on the clinical and radiographic findings, the tooth was diagnosed with a chronic apical abscess and surgical endodontic treatment was planned.

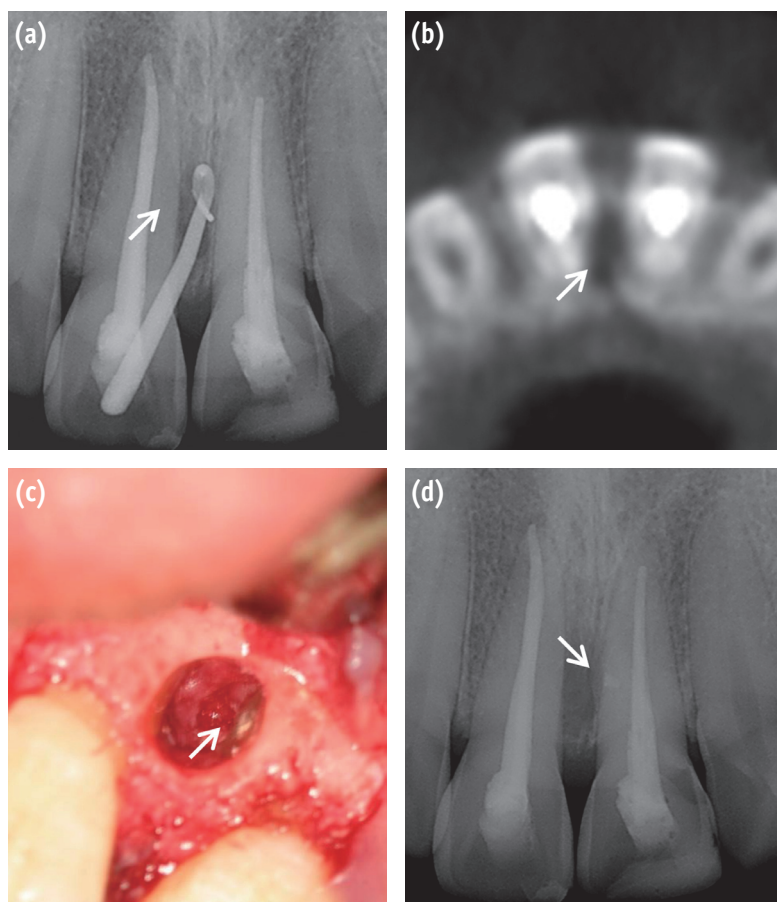
Under local anesthesia, mucoperiosteal flaps were raised. Upon elevation of the flap, vertical root fracture was observed along the root surface of the tooth #11 (Figure 1d). Examination of the root surface under the microscope confirmed that the lateral canal was the origin of the persistent paradicular lesion. The granulation tissue was removed and the lateral canal which was located in the middle one third of root was prepared using an ultrasonic tip (KiS-1D, Obtura Spartan, Fenton, MO, USA). The prepared lateral canal was filled with IRM (Dentsply DeTrey GmbH, Konstanz, Germany) and the flap was sutured with 4-0 blue nylon (AILEE CO., Busan, Korea) (Figure 1e).

Additional curettage was not performed in paradicular area.

The sutures were removed 1 week later, and the patient did not report any postoperative pain or discomfort. At the 1 month follow-up visit, the labial sinus tract was resolved (Figure 1f) and coronal re-restoration was performed. Twelve months after the procedure, paradicular radiograph revealed healthy paradicular tissues (Figure 1g). The CBCT was taken 18 months after treatment and formation of the alveolar bone in the labial surface of tooth #8 was observed (Figure 1h).

## Case 2

A 23 year-old man presented to the Department of Conservative Dentistry at Kyung Hee University Dental Hospital at Gangdong for treatment of a draining sinus tract, which the clinician found to be associated with tooth #21. The tooth had received endodontic treatment several years ago. Clinical examination revealed a sinus tract in the labial attached gingiva adjacent to tooth #21, as well as tenderness to palpation in the mesial paradicular region (Figure 2a). Radiographic examination revealed alveolar bone resorption on the mesial surface of the root. There



**Figure 2.** (a) Preoperative radiograph showing a maxillary left central incisor with a gutta-percha cone tracing the sinus tract; (b) Axial view of CBCT image showing the mesial bone loss in the middle third of the root (arrow); (c) Surgical confirmation of the lateral canal (arrow); (d) 1 month follow-up paradicular radiograph. The obturated lateral canal was visualized (arrow).

was no periapical lesion but gutta percha traced the lateral lesion of tooth #21 (Figure 2a). A CBCT image confirmed the mid-root mesial bone loss in tooth #21 (Figure 2b). Based on the clinical and radiographic findings, chronic apical abscess was diagnosed and surgical endodontic treatment of a tooth #21 was planned.

Under local anesthesia, mucoperiosteal flaps were raised in the area of tooth #21. An osseous defect over the mesial surface of the root was observed. The defect was degranulated, exposing the mesial root surface. Under a microscope, a large lateral canal in the cervical one third of the root was detected. A lateral canal was retro-prepared with an ultrasonic tip (KiS-1D) and sealed with IRM (Figure 2c).

One month after the surgery, the patient did not present with a sinus tract. At the six month follow-up visit, there were no clinical or radiographic signs of apical surgery failure (Figure 2d).

## Discussion

Nonsurgical endodontic treatment is a predictable and reliable treatment with high success rates that range from 86 to 98%.<sup>15,16</sup> Nevertheless, there are some cases in which the treatment has followed the highest technical standards and yet the treatments are unsuccessful.<sup>17</sup> Some factors may be associated with the unsatisfactory outcome of well-treated cases. Song *et al.* examined the clinical causes of failure and the limitation of a previous endodontic treatment by examining the root apex and resected root surface at x26 magnification during the endodontic microsurgery of failed teeth that had undergone a previous endodontic treatment.<sup>18</sup> The most common possible cause of failure was perceived leakage around the canal filling material (30.4%), followed by a missing canal (19.7%), underfilling (14.2%), anatomical complexity (8.7%), and other factors (8.8%). In the large majority of teeth with apical periodontitis, microbial infection was present not only in the main root canal but also propagated to anatomical complexities including dentinal tubules, recesses, isthmi, lateral canals, furcal canals, and apical ramifications.<sup>19</sup> In this present case report, bacteria that persisted after treatment were arranged in biofilm structures located in an intricate network of the lateral canal that remained apparently unaffected by treatment.

Previously treated teeth with persistent periapical lesion(s) might be preserved with nonsurgical retreatment or endodontic surgery. However, it appears that the recommendations are often subjective and inconsistent, and there is a lack of consensus among dental professionals when making decisions related to retreatment or endodontic surgery.<sup>20-23</sup> Torabinejad *et al.* reported that endodontic surgery offers more favorable initial success, but nonsurgical retreatment offers a more favorable long-

term outcome.<sup>24</sup> In first case, incomplete root canal filling and coronal restoration was observed. Therefore, the best treatment plan should have been nonsurgical endodontic re-treatment prior endodontic surgery.

Lateral canals, with few exceptions, are not visible in preoperative radiographs.<sup>10,25</sup> The occurrence of lateral canals are usually suspected only when there is a localized thickening of the periodontal ligament on the lateral surface of the root or when a lateral periodontitis lesion is present.<sup>10</sup> After root canal obturation, lateral canals can also be visualized on radiographs when a consistent amount of filling material is forced into the ramifications by compaction.<sup>6</sup>

Currently, there is debate among clinicians about how lateral canals should be filled. Previous studies investigated root filled teeth in humans and reported no relationship between unfilled lateral canals and the inflammation at the periradicular tissues.<sup>8,26</sup> However, lateral canals and apical ramifications have been implicated in endodontic treatment failure when they are sufficiently large enough to harbor significant numbers of bacteria and to provide these bacteria with access to the periradicular tissues.<sup>10</sup> The infection could be related to the size and patency of the lateral canals and apical ramifications as well as the microbiological conditions.<sup>11</sup> A morphological study of 100 permanent molars revealed that 79% had lateral/accessory foramina with diameters that ranged from 10 - 200  $\mu\text{m}$ .<sup>11</sup> The largest diameter of lateral/accessory foramina was nearly two to three times smaller than the mean diameters reported for the main apical foramen.<sup>27,28</sup> These differences in diameters between the main apical foramen and lateral/accessory foramina could explain why apical periodontitis is observed far more than lateral periodontitis.

Vieira *et al.* reported that a persistent intraradicular infection can be caused by bacteria located within dentinal tubules.<sup>29</sup> Even though the lateral canal may appear to be "filled" on radiography, the histologic findings revealed that the filling material was intermixed with necrotic tissue and adequate filling of the lateral canal did not occur. Despite the radiographic normal periradicular conditions, histologic sections demonstrated that the lateral canal was actually not filled and that there were varying degrees of inflammation in residual tissue islands.<sup>10</sup>

Kim and Kratchman suggested that at least 3 mm of the root-end must be removed in root-end resection because 98% of the apical ramifications and 93% of the lateral canals exist in 3 mm of the root-end.<sup>30</sup> The incidence of accessory canals located in the apical 3 mm was reported as 46%, 29% and 38% for the maxillary central incisors, lateral incisors and canines, respectively.<sup>7</sup> The accessory canals in the maxillary central incisor were observed mainly on the labial side of the root. These could still be treated with surgical endodontic treatment even if they remain after the 3 mm resection. In this present case report, the

infected lateral canals of the maxillary central incisors were located in the middle or cervical one third of the root and those were labially presented so that infected lateral canals could be successfully managed by surgical endodontic treatment without the root end resection.

## Conclusions

This case report highlights the clinical significance and management of maxillary incisor lateral canals. It is important to be aware of root canal anatomic variability such as lateral canals and apical ramifications to determine proper surgical root canal treatment. Based on follow-up observations presented in this study, maxillary incisors infected via lateral canals can be successfully managed by surgical endodontic treatment.

## Acknowledgment

This research was supported by the Basic Science Program through the National Research Foundation of Korea (NRF) funded by the Ministry of Education, Science and Technology (KRF-20100023448).

### Orcid numbers:

Ji-Hyun Jang, 0000-0002-4672-3381

Jung-Min Lee, 0000-0002-3664-2967

Jin-Kyu Yi, 0000-0002-2015-191x

Sung-Baik Choi, 0000-0002-6538-0687

Sang-Hyuk Park, 0000-0002-0518-6938

Conflict of Interest: No potential conflict of interest relevant to this article was reported.

## References

1. Ida RD, Gutmann JL. Importance of anatomic variables in endodontic treatment outcomes: case report. *Endod Dent Traumatol* 1995;11:199-203.
2. Nair PN, Henry S, Cano V, Vera J. Microbial status of apical root canal system of human mandibular first molars with primary apical periodontitis after "one-visit" endodontic treatment. *Oral Surg Oral Med Oral Pathol Oral Radiol Endod* 2005;99:231-252.
3. Adorno CG, Yoshioka T, Suda H. Incidence of accessory canals in Japanese anterior maxillary teeth following root canal filling *ex vivo*. *Int Endod J* 2010;43:370-376.
4. De Deus QD. Frequency, location, and direction of the lateral, secondary, and accessory canals. *J Endod* 1975;1:361-366.
5. Vertucci FJ. Root canal anatomy of the human permanent teeth. *Oral Surg Oral Med Oral Path* 1984;58:589-599.
6. Weine FS. The enigma of the lateral canal. *Dent Clin North Am* 1984;28:833-852.
7. Iqbal MK, Gartenberg J, Kratchman SI, Karabucak B, Bui B. The clinical significance and management of apical accessory canals in maxillary central incisors. *J Am Dent Assoc* 2005;136:331-335.
8. Barthel CR, Zimmer S, Trope M. Relationship of radiologic and histologic signs of inflammation in human root-filled teeth. *J Endod* 2004;30:75-79.
9. Ricucci D, Langeland K. Apical limit of root canal instrumentation and obturation, part 2. A histological study. *Int Endod J* 1998;31:394-409.
10. Ricucci D, Siqueira JF Jr. Fate of the tissue in lateral canals and apical ramifications in response to pathologic conditions and treatment procedures. *J Endod* 2010;36:1-15.
11. Dammaschke T, Witt M, Ott K, Schäfer E. Scanning electron microscopic investigation of incidence, location, and size of accessory foramina in primary and permanent molars. *Quintessence Int* 2004;35:699-705.
12. Wada M, Takase T, Nakanuma K, Arisue K, Naqahama F, Yamazaki M. Clinical study of refractory apical periodontitis treated by apicectomy. Part 1. Root canal morphology of resected apex. *Int Endod J* 1998;31:53-56.
13. Rubach WC, Mitchell DF. Periodontal disease, accessory canals and pulp pathosis. *J Periodontol* 1965;36:34-38.
14. Harrington GW. The perio-endo question: differential diagnosis. *Dent Clin North Am* 1979;23:673-690.
15. Friedman S, Abitbol S, Lawrence HP. Treatment outcome in endodontics: the Toronto Study. Phase 1: initial treatment. *J Endod* 2003;29:787-793.
16. Setzer FC, Boyer KR, Jeppson JR, Karabucak B, Kim S. Long-term prognosis of endodontically treated teeth: a retrospective analysis of preoperative factors in molars. *J Endod* 2011;37:21-25.
17. Siqueira JF Jr. Aetiology of root canal treatment failure: why well-treated teeth can fail. *Int Endod J* 2001;34:1-10.
18. Song M, Kim HC, Lee W, Kim E. Analysis of the cause of failure in nonsurgical endodontic treatment by microscopic inspection during endodontic microsurgery. *J Endod* 2011;37:1516-1519.
19. Arnold M, Ricucci D, Siqueira JF Jr. Infection in a complex network of apical ramifications as the cause of persistent apical periodontitis: a case report. *J Endod* 2013;39:1179-1184.
20. Aryanpour S, Van Nieuwenhuysen JP, D'Hoore W. Endodontic retreatment decisions: no consensus. *Int Endod J* 2000;33:208-218.
21. Bell GW. A study of suitability of referrals for periradicular surgery. *Br Dent J* 1998;184:183-186.
22. Reit C, Gröndahl HG. Management of periapical lesions in endodontically treated teeth. A study on clinical decision making. *Swed Dent J* 1984;8:1-7.

23. Kvist T, Reit C. The perceived benefit of endodontic retreatment. *Int Endod J* 2002;35:359-365.
24. Torabinejad M, Corr R, Handysides R, Shabahang S. Outcomes of nonsurgical retreatment and endodontic surgery: a systematic review. *J Endod* 2009;35:930-937.
25. Kim HH, Min JB, Hwang HK. Apical foramen morphology according to the length of merged canal at the apex. *Restor Dent Endod* 2013;38:26-30.
26. Kim S. Prognostic factors influencing clinical outcome of nonsurgical endodontic treatment. *J Korean Acad Conserv Dent* 2010;35:436-444.
27. Ponce EH, Vilar Fernández JA. The cemento-dentino-canal junction, the apical foramen, and the apical constriction: evaluation by optical microscopy. *J Endod* 2003;29:214-219.
28. Green D. A stereomicroscopic study of the root apices of 400 maxillary and mandibular anterior teeth. *Oral Surg Oral Med Oral Pathol* 1956;9:1224-1232.
29. Vieira AR, Siqueira JF Jr., Ricucci D, Lopes WS. Dentinal tubule infection as the cause of recurrent disease and late endodontic treatment failure: a case report. *J Endod* 2012;38:250-254.
30. Kim S, Kratchman S. Modern endodontic surgery concepts and practice: a review. *J Endod* 2006;32:601-623.