

Comparative evaluation of molar distalization therapy using pendulum and distal screw appliances

Alberto Caprioglio^a
Alessandra Cafagna^b
Mattia Fontana^c
Mauro Cozzani^d

^aPostgraduate Programme in Orthodontics, School of Medicine, University of Insubria, Varese, Italy

^bPostgraduate Programme in Orthodontics, University of Insubria, Varese, Italy

^cDepartment of Orthodontics, University of Insubria, Varese, Italy

^dDepartment of Orthodontics, School of Dental Medicine, University of Cagliari, Italy

Objective: To compare dentoalveolar and skeletal changes produced by the pendulum appliance (PA) and the distal screw appliance (DS) in Class II patients.

Methods: Forty-three patients (19 men, 24 women) with Class II malocclusion were retrospectively selected for the study. Twenty-four patients (mean age, 12.2 ± 1.5 years) were treated with the PA, and 19 patients (mean age, 11.3 ± 1.9 years) were treated with the DS. The mean distalization time was 7 months for the PA group and 9 months for the DS group. Lateral cephalograms were obtained at T1, before treatment, and at T2, the end of distalization. A Mann-Whitney *U* test was used for statistical comparisons of the two groups between T1 and T2. **Results:** PA and DS were equally effective in distalizing maxillary molars (4.7 mm and 4.2 mm, respectively) between T1 and T2; however, the maxillary first molars showed less distal tipping in the DS group than in the PA group (3.2° vs. 9.0° , respectively). Moreover, significant premolar anchorage loss (2.7 mm) and incisor proclination (5.0°) were noted in the PA group, whereas premolar distal movement (1.9 mm) and no significant changes at the incisor (0.1°) were observed in the DS group. No significant sagittal or vertical skeletal changes were detected between the two groups during the distalization phase.

Conclusions: PA and DS seem to be equally effective in distalizing maxillary molars; however, greater distal molar tipping and premolar anchorage loss can be expected using PA.

[Korean J Orthod 2015;45(4):171-179]

Key words: Class II malocclusion, Molar distalization, Non-compliance, Intraoral distalizing devices, Skeletal anchorage

Received August 17, 2014; Revised December 7, 2014; Accepted December 27, 2014.

Corresponding author: Alberto Caprioglio.

Associate Professor, Postgraduate Programme in Orthodontics, School of Medicine, University of Insubria, Via San Zeno, 1, Varese 27100, Italy.

Tel +39-038232132 e-mail mattiafontana16@gmail.com

The authors report no commercial, proprietary, or financial interest in the products or companies described in this article.

© 2015 The Korean Association of Orthodontists.

This is an Open Access article distributed under the terms of the Creative Commons Attribution Non-Commercial License (<http://creativecommons.org/licenses/by-nc/4.0>) which permits unrestricted non-commercial use, distribution, and reproduction in any medium, provided the original work is properly cited.

INTRODUCTION

The pendulum device is one of the most commonly used conventional distalizing devices.^{1,2} However, despite its efficacy in molar distalization, premolar mesial movement and anterior anchorage loss³⁻⁷ continue to represent an unpleasant problem and require additional treatment time for correction during fixed appliance therapy.

In order to reduce anchorage loss, the use of mini-implants or miniscrews was introduced.⁸ Based on their low cost, reduced invasiveness, ease of insertion and removal, possibility for immediate loading, and versatility, these devices have become increasingly popular, even in combination with distalizing devices. Paramedian and midpalatal insertions appear to be most suitable for this purpose,⁹⁻¹⁰ because placing miniscrews in interradicular sites may require additional radiographic examinations, complex surgical protocols to avoid root damage, and prevent spontaneous retraction of premolars during distalization until the screws are inserted.^{11,12} A recent meta-analysis¹³ evaluated the efficacy of conventional versus bone-anchored anchorage, showing that both systems were effective for molar distalization but that there were differences in anchorage loss. Conventional and indirect skeletal anchorage showed a certain amount of anchorage loss at the premolars and incisors, whereas these side effects were not seen with direct skeletal anchorage.

For this reason, various modifications of distalizing appliances used in combination with paramedian miniscrews have been developed in recent years.^{11,14-21} Many authors¹⁴⁻¹⁶ have described the effects of a bone-anchored pendulum appliance (BAPA), a modified pendulum in which the palatal arms on the premolar are eliminated. The distal jet appliance was modified into a skeletonized distal Jet appliance,¹⁷ in which the Nance

button was eliminated but the arms on the premolar were retained; it was later modified into the distal screw appliance (Micerium S.p.A., Avegno, Italy),^{11,18} in which the metallic palatal arms on the premolar were eliminated. Similar devices were the skeletal frog,¹⁹ a modified frog appliance without arms on the premolar and without the acrylic palatal button; the intraoral miniscrew implant-supported distalization system (MISDS)²⁰ and the Beneslider,²¹ which is characterized by midpalatal miniscrews and compressed palatal coils.

Dentoskeletal changes produced by these appliances have been described in the literature. However, there have been few comparisons between skeletal-anchored and conventional distalizing devices.²² Moreover, a comparison between distal jet and implant-supported distal jet devices has recently been published.²³ Therefore, the aim of this study was to compare the dentoalveolar and skeletal changes produced by the pendulum appliance (conventional anchorage) and distal screw appliance (skeletal anchorage) in Class II patients. The null hypothesis was that the two appliances would produce similar dental and skeletal changes.

MATERIALS AND METHODS

A sample of 75 patients was retrospectively obtained from two orthodontic dental offices. All patients were selected according to the following criteria:

- Skeletal Class I or mild Class II malocclusion and a bilateral full cusp or end-to-end Class II molar relationship
- Absence of protrusive profile or mandibular retrusion²⁴
- Nonextraction treatment
- Mandibular inclination (sella-nasion-gonion-gnathion [SN-GoGn] angle) less than 37°
- Use of pendulum appliance (Figure 1) or distal screw

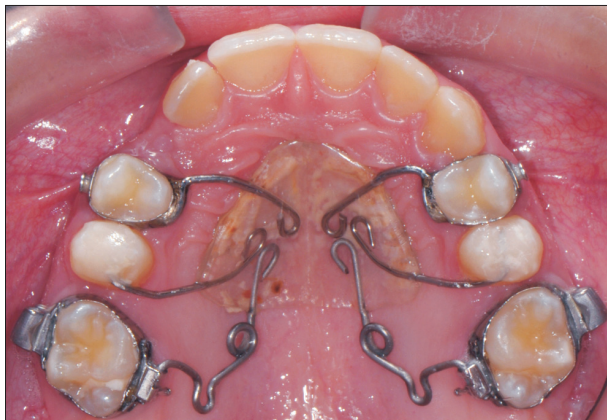

Figure 1. Pendulum appliance.

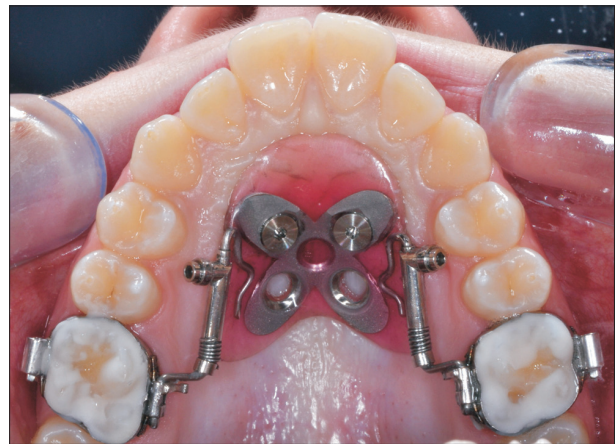

Figure 2. Distal screw appliance.

(Figure 2) during the distalization phase

- Good-quality radiographs with adequate landmark visualization and minimal or no rotation of the head

From the initial sample, the records of 5 patients in the pendulum group (PA) and 4 patients in the distal screw group (DS) were excluded because their mandibular plane was greater than 37°. An additional 3 patients in the PA group and 3 patients in the DS group were excluded because extraoral traction was used after the distalization phase, either as anchorage support or because of miniscrew failure. Nine patients in the PA group and 8 patients in the DS group were excluded due to poor radiograph quality or incomplete records (Table 1). Thus, the final sample consisted of 43 white patients divided in 2 groups: 24 (10 men, 14 women) with a mean age of 12.2 ± 1.5 years (range, 10 years 5 months to 14 years 2 months) in the PA group, and 19 (9 men, 10 women) with a mean age of 11.3 ± 1.9 years (range, 10 years 4 months to 13 years 7 months) in the DS group. Initial cephalometric characteristics of the patients in the two groups were considered comparable (Table 2). The average amount of Class II

molar relationship was 3.5 mm in the PA group and 3.8 mm in the DS group, with mean overjets of 3.9 mm and 4.2 mm, respectively, at the beginning of treatment. Two serial cephalograms for all patients were available at 2 observation times: before treatment (T1) and after distalization (T2). Demographics of observation periods and observation intervals are reported in Table 3.

Table 1. Sample selection and exclusion criteria for the pendulum and distal screw groups

Sample selection	Pendulum group	Distal screw group
Patient sample	41	34
Mandibular inclination (S-N/ Go-Gn) > 37°	5	4
Use of other molar distalization methods	3	3
Poor film quality	4	3
Incomplete records	5	5
Final sample	24	19

Table 2. Comparison of cephalometric measurements between Pendulum group and distal screw group at T1

Cephalometric measurement	Pendulum group (n=24)		Distal screw group (n=19)		p-value
Sagittal skeletal relations					
Maxillary position S-N-A (°)	81.2	2.5	81.5	3.8	0.750
Mandibular position S-N-B (°)	77.4	2.9	77	3.2	0.712
Sagittal jaw relation A-N-B (°)	3.6	1.8	4.5	1.4	0.043*
Vertical skeletal relations					
Maxillary inclination S-N/ ANS-PNS (°)	7.7	3.0	8.2	2.6	0.747
Mandibular inclination S-N/ Go-Gn (°)	30.6	3.8	31.6	6.3	0.541
Occlusal plane inclination S-N/OCL (°)	19.8	4.3	18.0	4.0	0.270
Vertical Jaw Relation ANS-PNS/Go-Gn (°)	22.9	2.6	23.4	3.6	0.632
Dento-basal relations					
Maxillary incisor inclination U1-SN (°)	103.2	8.3	101.7	7.3	0.327
Mandibular incisor inclination L1-Go-Gn (°)	93.4	5.4	95.5	5.9	0.025*
Mandibular incisor compensation L1-A-Pg (°)	1.7	0.5	2.4	0.7	0.307
Dental relations					
Overjet (mm)	3.9	1.6	4.2	1.5	0.493
Overbite (mm)	4.1	1.9	3.2	2.1	0.250
Molar relationship (mm)	3.5	0.7	3.8	0.6	0.841
Interincisal angle U1-L1 (°)	132.6	3.4	130.3	4.2	0.670
Soft tissue					
Upper lip to E-plane (mm)	-3.2	1.8	-2.2	2.4	0.113
Lower lip to E-plane (mm)	-2.0	2.3	-1.3	2.6	0.276

Values are presented as mean ± standard deviation.

*p < 0.05.

Table 3. Demographics of observation periods and observation intervals

Observation period/interval	Pendulum group (n=24)	Distal screw group (n=19)
T1	12 y 2 mo ± 1 y 5 mo (10 y 5 mo – 14 y 2 mo)	11 y 3 mo ± 1 y 9 mo (10 y 4 mo – 13 y 7 mo)
T2	13 y 1 mo ± 1 y 4 mo (11 y 6 mo – 15 y 1 mo)	12 y 2 mo ± 1 y 2 mo (11 y 1 mo – 14 y 6 mo)
T1-T2	7 mo ± 2 mo (5 mo – 11 mo)	9 mo ± 2 mo (4 mo – 12 mo)

Values are presented as mean ± standard deviation (minimum-maximum).

T1 and T2 represent the mean age in which radiographs were taken, whereas T1-T2 interval represents the mean period of active distalization.

y, year; mo, months.

Clinical management

All patients underwent maxillary molar distalization therapy with either a pendulum or a distal screw appliance.

Dental and skeletal changes during fixed appliance therapy were not taken into consideration in order to highlight the differences between the two appliances during the distalization phase.

Pendulum appliance

The pendulum appliance used in this study was similar to that described by Hilgers.² The 0.032-inches [in] titanium-molybdenum alloy (TMA) springs were bent parallel to the palatal midline and placed in the lingual sheaths on maxillary first molar bands, exerting approximately 230 g of distalizing force per side, as measured with a dynamometer (Correx; Dentaorium GmbH & Co., Ispringen, Germany). A Nance button was placed on the anterior vault of the palate as anchorage, adding arms on the first premolars and occlusal rests on the second premolars. Palatal TMA arms were removed from the palatal molar sheaths and intraorally reactivated every 6 weeks on average. As recommended by Byloff and Darendeliler,⁵ uprighting bends were added to the ends of the TMA wire to prevent excessive molar tipping. The appliance was left *in situ* until a super Class I molar relationship was achieved.

The mean treatment time for distalization was 7 ± 2 months (Table 3).

Distal screw appliance

The distal screw appliance is a modified distal jet in which the metallic palatal arms on the premolars, normally used for dental anchorage, are eliminated and the Nance button includes a moldable metal plaque which is used as a guide to insert two miniscrews (Titanium V, 11 mm long, 2.2 mm diameter; Micerium S.p.A., Avegno, Italy) in the palatal vault. The shank was 1.0 mm in diameter, the threaded part had a length of 8.0 mm, and the head featured a hexagonal slot to house the head of the screwdriver or contra-angle handpiece. The two miniscrews (one for each side) were placed in the

paramedian region of the anterior palatal vault along a line connecting the first premolars. The head had a flat shape completely included in the Nance button, minimizing the possibility of tongue loadings and reducing the risk of compromising the primary stability. The arms on the first molars were activated as a distal jet, completely compressing the superelastic springs until a force of 240 g was obtained; reactivation was carried out at 4-week intervals.²⁵ Distalization continued until the Class II molar relationship was corrected to a Class I molar relationship.

The mean treatment time for distalization was 9 ± 2 months (Table 3).

Cephalometric analysis

Lateral cephalograms for each patient at T1 and T2 in each treatment group were standardized at the same magnification factor (6% enlargement). Lateral cephalograms were hand traced in random order by one investigator with verification of anatomic outlines and landmark position by a second investigator. In cases of disagreement, the structures in question were retraced to the satisfaction of both. In instances of bilateral structures (e.g., gonial angle and teeth), a single averaged tracing was made. The centroid points of the maxillary first and second molars and the maxillary first premolars were obtained as the midpoint between the greatest mesial and distal convexity of the crowns, as seen on the cephalometric radiographs.³ Table 2 shows the measurements and summary statistics of the pooled sample before initiation of treatment.

A conventional analysis, including soft tissue, skeletal, and dental measurements (Figure 3), was done.³ Sagittal skeletal measurements were added in order to complete the cephalometric analysis. The Frankfort-mandibular plane angle was not used because of the difficulty of detecting the Porion point; SN-GoGn was used as an indicator of vertical facial dimension. The SN plane and palatal plane (PP) were used as the horizontal reference planes, and the pterygoid vertical (PTV) line, as described by Enlow et al.,^{26,27} was used as the vertical reference plane. The PTV line extends inferiorly from a

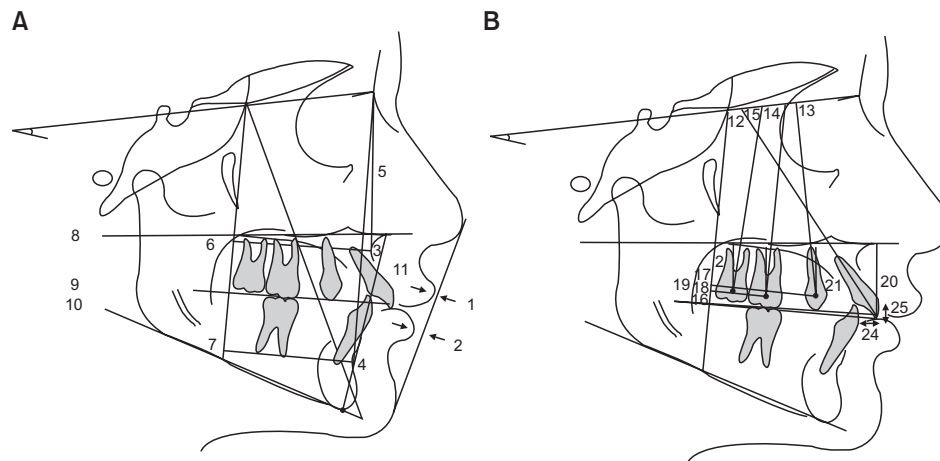


Figure 3. The measurements used in present study. A, Cephalometric measurements of skeletal tissues and soft tissues used in the study: 1, Upper lip to E-plane; 2, lower lip to E-plane; 3, SNA, Sella-Nasion-A-point; 4, SNB, Sella-Nasion-B-point; 5, ANB, A-point-Nasion-B-point; 6, PTV-A point; 7, PTV-B point; 8, SN-palatal plane angle; 9, SN-anatomic occlusal plane; 10, SN-mandibular plane angle; 11, lower anterior facial height (LAFH). B, Dental angular cephalometric measurements used in the study: 12, SN-maxillary incisor; 13, SN-maxillary first premolar; 14, SN-maxillary first molar; 15, SN-maxillary second molar. Dental linear cephalometric measurements: 16, PTV-maxillary incisor; 17, PTV-maxillary first premolar; 18, PTV-maxillary first molar; 19, PTV-maxillary second molar; 20, PP-maxillary incisor; 21, PP-maxillary first premolar; 22, PP-maxillary first molar; 23, PP-maxillary second molar; 24, overjet; 25, overbite. SN, Sella-nasion; A, A point; B, B point; PTV, pterygoid vertical; PP, palatal plane.

point (the sphenothmoidal) located by the intersection of the shadows of the great wings of the sphenoid with the floor of the anterior cranial fossa (representing the boundary between the anterior and posterior portions of the anterior cranial base as well as the boundary between the anterior and middle endocranial fossae) through the inferior point of the pterygomaxillary fissure (Figure 3).

The cephalometric analysis consisted of 25 landmarks, 10 angular measurements, and 15 linear measurements for each tracing (Figure 3). To assess the sagittal changes in jaw relationships, measurements were made from points A and B to the PTV. The PTV line was used to assess the amount of linear horizontal movement, whereas the linear vertical movement was measured on PP. The long axes of the premolar and molar teeth were obtained by drawing a perpendicular line to the mid-point of a line connecting the most convex points on the crowns of these teeth. Angular differences in tooth position were then determined by the inclination of the long axes to the SN plane.³

Statistical analysis

Statistical analysis was performed using SPSS software, version 13.0 (SPSS® Inc., Chicago, IL, USA). Descriptive statistics were calculated for age, duration of treatment, and cephalometric measurements at T1 for the 2 groups. Mean differences and standard deviations were

also calculated for the treatment changes between T1 and T2. A Shapiro-Wilk test did not reveal a normal distribution of the tested variables, and nonparametric tests were used for the inferential statistics. In order to compare pre-treatment cephalometric data, an independent sample Mann-Whitney *U* test was performed between the two groups at T1. No significant differences were found. A paired-data Wilcoxon test was used to identify significant differences in each group between T1 and T2, and a Mann-Whitney *U* test was used to identify significant differences between groups ($\Delta = T2 - T1$) for each cephalometric variable. Statistical significance was tested at $p < 0.05$, $p < 0.01$, and $p < 0.001$.

Method error

Fifteen randomly selected cephalograms were retraced by the same author after a period of 2 months. No significant differences between the 2 series of records were found using paired *t*-tests. Dahlberg's²⁸ formula was used to establish the method error. A range of 0.5 to 0.8 mm for linear measurements and 0.6° to 0.9° for angular measurements was found. The reliability coefficient (*r*)²⁹ ranged from 0.94 to 0.98 and from 0.92 to 0.97, respectively.

RESULTS

The mean, standard deviation, and statistical signif-

Table 4. Comparison of changes during distalization period (T1 to T2)

Cephalometric measurement	Pendulum group (n=24)	Distal screw group (n=19)	p-value
Soft tissue			
Upper lip to E-plane (mm)	0.7 ± 1.3	0.1 ± 1.7	0.069
Lower lip to E-plane (mm)	0.6 ± 1.5	-0.1 ± 1.2	0.079
Sagittal skeletal relations			
Maxillary position S-N-A (°)	-0.4 ± 2.1	0.4 ± 0.6	0.106
Mandibular position S-N-B (°)	0.4 ± 2.1	0.3 ± 0.7	0.775
Sagittal jaw relation A-N-B (°)	-0.5 ± 1.3	-0.5 ± 0.1	0.683
PTV-A point (mm)	0.1 ± 2.1	0.6 ± 0.8	0.278
PTV-B point (mm)	0.7 ± 2.8	-0.1 ± 1.6	0.594
Vertical skeletal relations			
Maxillary inclination S-N / ANS-PNS (°)	0.1 ± 2.3	-0.3 ± 1.6	0.688
Occlusal plane inclination SN-OCL (°)	0.5 ± 2.3	0.7 ± 2.2	0.634
Mandibular inclination S-N / Go-Gn (°)	0.8 ± 3.0	0.5 ± 2.1	0.864
LAFH ANS-Menton (mm)	1.8 ± 1.8	1.7 ± 1.2	0.713
Dental relations			
Overjet (mm)	1.3 ± 1.2	0.9 ± 1.1	0.096
Overbite (mm)	0.4 ± 1.9	0.1 ± 1.3	0.704
Maxillary dentoalveolar			
SN-U1 (°)	5.0 ± 3.6	0.1 ± 3.5	<0.001***
SN-U4 (°)	3.6 ± 1.6	5.1 ± 2.0	<0.001***
SN-U6 (°)	9.0 ± 4.1	3.2 ± 3.0	<0.01**
SN-U7 (°)	10.2 ± 5.9	5.2 ± 3.6	<0.01**
PTV-U1 (mm)	1.7 ± 2.7	0.1 ± 1.5	0.279
PTV-U4 (mm)	2.7 ± 3.3	1.9 ± 1.7	<0.001***
PTV-U6 (mm)	4.7 ± 2.0	4.2 ± 1.4	0.591
PTV-U7 (mm)	4.0 ± 2.0	3.9 ± 1.7	0.177
PP-U1 (mm)	0.5 ± 1.4	0.5 ± 0.6	0.584
PP-U4 (mm)	1.4 ± 1.9	1.3 ± 2.0	0.193
PP-U6 (mm)	0.1 ± 1.6	0.3 ± 0.8	0.167
PP-U7 (mm)	0.1 ± 2.4	0.7 ± 1.3	0.340

Values are presented as mean ± standard deviation.

p* < 0.01; *p* < 0.001.

importance of the dentoskeletal changes relative to T1-T2 are summarized in Table 4. Graphic representations of maxillary superimposition for the PA and DS groups describing dentoalveolar changes during the distalization phase (T1-T2) are shown in Figures 4 and 5.

Pretreatment to post-distalization (T1-T2)

No significant sagittal or vertical skeletal change was detected between the two groups during the distalization phase. There was a slight opening of the mandibular plane angle in both groups (0.8° ± 3.0° in

PA and 0.5° ± 2.1° in DS), with an increase of lower anterior facial height (1.8 ± 1.8 mm in PA and 1.7 ± 1.2 mm in DS). However, these differences were not statistically significant.

The maxillary first molar showed a mean distal movement of 4.7 ± 2.0 mm in the PA group and 4.2 ± 1.4 mm in the DS group, but these changes were not statistically significant. However, the maxillary first molar showed greater distal tipping in the PA group than in the DS group (U6 to SN: -9.0° ± 4.1° vs. -3.2° ± 3.0°; *p* < 0.01). Moreover, the first molar slightly intruded in

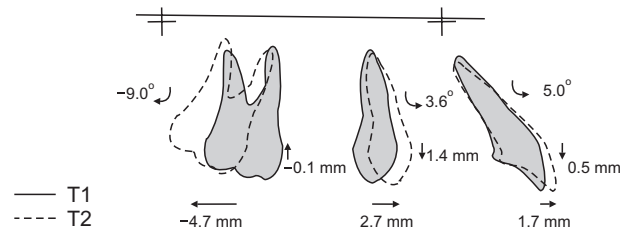


Figure 4. Graphic representation of maxillary superimposition for the pendulum group, showing dentoalveolar changes during the distalization phase (T1-T2).

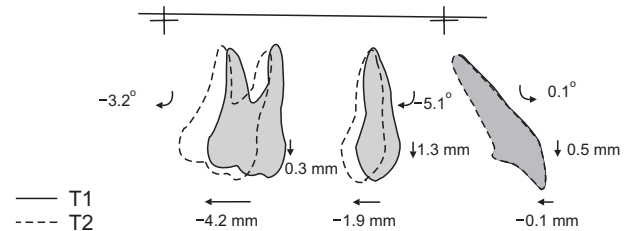


Figure 5. Graphic representation of maxillary superimposition for distal screw group, showing dentoalveolar changes during the distalization phase (T1-T2).

the PA group (-0.1 ± 1.6 mm) and extruded in the DS group (0.3 ± 0.8 mm). The mean treatment time for distalization was 7 ± 2 months in the PA group and 9 ± 2 months in the DS group.

A significant difference was found in the anchorage loss. The first premolar showed a mesial movement (2.7 ± 3.3 mm) and a mesial tipping ($3.6^\circ \pm 1.6^\circ$) in the PA group, whereas a slight distal movement (-1.9 ± 1.7 mm) and distal tipping ($-5.1^\circ \pm 2.0^\circ$) was noted in the DS group. Accordingly, no significant change was described at the maxillary incisor in the DS group ($0.1^\circ \pm 3.5^\circ$ and -0.1 ± 1.5 mm), whereas a significant proclination ($5.0^\circ \pm 3.6^\circ$) was reported in the PA group ($p < 0.001$). The first premolar and maxillary incisor also slightly extruded relative to the palatal plane in both groups (1.4 ± 1.9 mm and 0.5 ± 1.4 mm, respectively, in the PA group; 1.3 ± 2.0 mm and 0.5 ± 0.6 mm, respectively, in the DS group), but these changes were not statistically significant.

The overjet increased more in the PA group than in the DS group (1.3 ± 1.2 mm vs. 0.9 ± 1.1 mm) and the overbite decreased more in the PA group than in the DS group (-0.4 ± 1.9 mm vs. -0.1 ± 1.3 mm), but neither of these changes was statistically significant.

The soft tissues showed no significant change in either group. The upper lip moved slightly forward relative to the esthetic plane (E-plane) in both groups, whereas the lower lip was insignificantly protruded in the PA group and retruded in the DS group.

DISCUSSION

Cephalograms at the beginning of treatment revealed that patients in the 2 groups were in general not substantially different, confirming that this study had a low susceptibility bias (Table 3).

The appliances were equally effective in molar distalization (4.7 mm in the PA group and 4.2 mm in the DS group), even if the pendulum appliance required less distalization time (2 months less than distal screw). As previously reported by a recent meta-analysis,¹³ the amount of molar distalization did not seem to be the

main difference between conventional and skeletal-anchored distalizing devices, because it seemed mainly related to the molar movement required before treatment to correct the Class II molar relationship. A confounding factor might be simply the tendency to treat patients with more severe Class II malocclusions using skeletal anchorage, where greater anchorage is desired.

Despite a slight molar intrusion in the PA group and extrusion in the DS group during the distalization phase, both appliances showed similar findings in the vertical facial dimension (SN-GoGn, 0.8° and 0.5° , respectively), but none of these differences was statistically and clinically significant.

However, differences were noted in molar distal tipping (9.0° in the PA group and 3.2° in the DS group), probably due to the intrinsic characteristics of the two appliances. Molar tipping could be related to the rigidity of the distalizing arms and the point of force application with respect to the center of resistance of the molar.³ The greater elasticity and flexibility of the TMA arms in addition to a coronal point of force application in the pendulum could cause greater distal molar tipping, which could be partially reduced by adding uprighting bends.⁵ Conversely, the distal screw acted as a distal jet,²⁵ using telescopic rigid arms acting in proximity to the center of resistance of the first molar and providing more bodily distal movement.

Bodily movement could require longer treatment time during the distalization phase, probably because of the increased resistance to the movement. However, greater molar distal tipping could involve a longer treatment time after the distalization phase, requiring subsequent mechanics for root uprighting and producing an additional burden on molar anchorage.⁶

The anchorage loss at incisors and premolars was the main difference between the two appliances (Figures 4 and 5). In the PA group, the maxillary incisor showed a buccal inclination of 5.0° , similar to the finding of 4.0° described by Angelieri et al.³⁰ The first premolar showed a mesial movement of 2.7 mm, and premolar anchorage loss was calculated at 36.5% in our study, in accordance with other studies in which mean percentage ranged

between 24%⁴ to 43%.³ Mesial movement of the anchor unit was an unavoidable side effect that could occur with any conventional intraoral distalizing appliance. Unfortunately, the increase of anchoring teeth might not be sufficient to overcome this problem⁶; in addition, most of the mechanotherapy used to contrast such forces (e.g., headgear or Class II elastics) is compliance-dependent.¹ Consequently, the combination between intraoral distalizing appliances and skeletal anchorage could be a reasonable approach to minimize anchorage loss during the distalization phase.¹³ In the present study, the maxillary incisor was almost stable in the distal screw (0.1°), and the first premolar showed distal movement of 1.9 mm.

A recent meta-analysis¹³ revealed that only with direct skeletal anchorage, a spontaneous distal premolar movement with no anchorage loss could be observed, probably due to the stretching of the interseptal fibers. Conversely, indirect skeletal-anchored devices showed a certain amount of anchorage loss at the premolar and incisor, even though they are smaller than conventional distalizing devices. This difference can be easily noted by comparing the findings relative to two modifications of the distal jet appliance in conjunction with paramedian miniscrews: the skeletonized distal jet (arms on the premolar) showed a premolar mesial movement of 0.72 mm, while in our study, the distal screw (no arm on the premolar) showed a premolar distal movement of 1.9 mm. This phenomenon had previously been described by Sar et al.¹⁶ and Polat-Ozsoy et al.,²² who reported premolar distalizations of 1.7 mm and 2.7 mm, respectively, using a BAPA; and by Cozzani et al.,²³ who reported distalization of 2.1 mm using a distal screw appliance.

Moreover, our results revealed that the maxillary premolar showed a consistent distal tipping (5.1°) rather than a true bodily distal movement, possibly indicating that transeptal fibers acted on the premolar crown more than on the root (Figure 5). Our findings confirmed the results described by Cozzani et al.²³ using the distal screw (−3°), Sar et al.¹⁶ using BAPA (−4.93°), and Polat-Ozsoy²² using MISDS (−6.85°).

These phenomena might facilitate the retraction of premolars and canines, reduce round tripping of the anchor teeth, and decrease total treatment time by the early stages.¹¹

The retrospective nature of this study and the analysis focusing primarily on the changes before and after the distalization phase could be considered weaknesses. However, all patients treated with these mechanics were included in the study, in order to avoid selection bias and the possibility of choosing some patients and screening out others. This reduced the risk of influencing the final outcomes.

Further long-term prospective studies should be conducted to confirm our results and report data at the end of orthodontic treatment or long-term follow-up.

CONCLUSION

- The null hypothesis that pendulum and distal screw appliances would produce similar dental and skeletal changes was disproved.
- Pendulum and distal screw appliances are equally effective in distalizing the maxillary molars, although treatment time was shorter in the pendulum group.
- Greater molar distal tipping, premolar mesial movement, and incisor proclination were noted with the pendulum appliance than with the distal screw during the distalization phase.
- The distal screw caused premolar distal movement during the distalization phase, possibly positively influencing the total treatment time.

REFERENCES

1. Fontana M, Cozzani M, Caprioglio A. Non-compliance maxillary molar distalizing appliances: an overview of the last decade. *Prog Orthod* 2012; 13:173-84.
2. Hilgers JJ. The pendulum appliance for Class II non-compliance therapy. *J Clin Orthod* 1992;26:706-14.
3. Ghosh J, Nanda RS. Evaluation of an intraoral maxillary molar distalization technique. *Am J Orthod Dentofacial Orthop* 1996;110:639-46.
4. Byloff FK, Darendeliler MA. Distal molar movement using the pendulum appliance. Part 1: Clinical and radiological evaluation. *Angle Orthod* 1997;67:249-60.
5. Byloff FK, Darendeliler MA, Clar E, Darendeliler A. Distal molar movement using the pendulum appliance. Part 2: The effects of maxillary molar root uprighting bends. *Angle Orthod* 1997;67:261-70.
6. Chiu PP, McNamara JA Jr, Franchi L. A comparison of two intraoral molar distalization appliances: distal jet versus pendulum. *Am J Orthod Dentofacial Orthop* 2005;128:353-65.
7. Caprioglio A, Beretta M, Lanteri C. Maxillary molar distalization: Pendulum and Fast-Back, comparison between two approaches for Class II malocclusion. *Prog Orthod* 2011;12:8-16.
8. Cheng SJ, Tseng IY, Lee JJ, Kok SH. A prospective study of the risk factors associated with failure of mini-implants used for orthodontic anchorage. *Int J Oral Maxillofac Implants* 2004;19:100-6.
9. Gracco A, Lombardo L, Cozzani M, Siciliani G. Quantitative cone-beam computed tomography evaluation of palatal bone thickness for orthodontic

- miniscrew placement. *Am J Orthod Dentofacial Orthop* 2008;134:361-9.
10. King KS, Lam EW, Faulkner MG, Heo G, Major PW. Vertical bone volume in the paramedian palate of adolescents: a computed tomography study. *Am J Orthod Dentofacial Orthop* 2007;132:783-8.
 11. Cozzani M, Gracco A, Lombardo L, Siciliani G. Why, when and how distalizing maxillary molars. *Ortodontologia Ital* 2007;14:21-7.
 12. Poggio PM, Incorvati C, Velo S, Carano A. "Safe zones": a guide for miniscrew positioning in the maxillary and mandibular arch. *Angle Orthod* 2006;76:191-7.
 13. Grec RH, Janson G, Branco NC, Moura-Grec PG, Patel MP, Castanha Henriques JF. Intraoral distalizer effects with conventional and skeletal anchorage: a meta-analysis. *Am J Orthod Dentofacial Orthop* 2013;143:602-15.
 14. Kircelli BH, Pektaş ZO, Kircelli C. Maxillary molar distalization with a bone-anchored pendulum appliance. *Angle Orthod* 2006;76:650-9.
 15. Escobar SA, Tellez PA, Moncada CA, Villegas CA, Latorre CM, Oberti G. Distalization of maxillary molars with the bone-supported pendulum: a clinical study. *Am J Orthod Dentofacial Orthop* 2007;131:545-9.
 16. Sar C, Kaya B, Ozsoy O, Özçirpici AA. Comparison of two implant-supported molar distalization systems. *Angle Orthod* 2013;83:460-7.
 17. Kinzinger GS, Gül den N, Yildizhan F, Diedrich PR. Efficiency of a skeletonized distal jet appliance supported by miniscrew anchorage for non-compliance maxillary molar distalization. *Am J Orthod Dentofacial Orthop* 2009;136:578-86.
 18. Cozzani M, Zallio F, Lombardo L, Gracco A. Efficiency of the distal screw in the distal movement of maxillary molars. *World J Orthod* 2010;11:341-5.
 19. Ludwig B, Glasl B, Kinzinger GS, Walde KC, Lisson JA. The skeletal frog appliance for maxillary molar distalization. *J Clin Orthod* 2011;45:77-84.
 20. Papadopoulos MA. Orthodontic treatment of Class II malocclusion with miniscrew implants. *Am J Orthod Dentofacial Orthop* 2008;134:604.e1-16.
 21. Wilmes B, Nienkemper M, Ludwig B, Kau CH, Pauls A, Drescher D. Esthetic Class II treatment with the Beneslider and aligners. *J Clin Orthod* 2012;46:390-8.
 22. Polat-Ozsoy O, Kircelli BH, Arman-Ozçirpici A, Pektaş ZO, Uçkan S. Pendulum appliances with 2 anchorage designs: conventional anchorage vs bone anchorage. *Am J Orthod Dentofacial Orthop* 2008;133:339.e9-339.e17.
 23. Cozzani M, Pasini M, Zallio F, Ritucci R, Mutinelli S, Mazzotta L, et al. Comparison of maxillary molar distalization with an implant-supported distal jet and a traditional tooth-supported distal jet appliance. *Int J Dent* 2014;2014:937059.
 24. Arnett GW, Gunson MJ. Facial planning for orthodontists and oral surgeons. *Am J Orthod Dentofacial Orthop* 2004;126:290-5.
 25. Bolla E, Muratore F, Carano A, Bowman SJ. Evaluation of maxillary molar distalization with the distal jet: a comparison with other contemporary methods. *Angle Orthod* 2002;72:481-94.
 26. Enlow DH, Kuroda T, Lewis AB. The morphological and morphogenetic basis for craniofacial form and pattern. *Angle Orthod* 1971;41:161-88.
 27. Caprioglio A, Fontana M, Longoni E, Cozzani M. Long-term evaluation of the molar movements following Pendulum and fixed appliances. *Angle Orthod* 2013;83:447-54.
 28. Dahlberg G. *Statistical methods for medical and biological students*. London, UK: Allen and Unwin; 1940. p. 122-32.
 29. Houston WJ. The analysis of errors in orthodontic measurements. *Am J Orthod* 1983;83:382-90.
 30. Angelieri F, Almeida RR, Almeida MR, Fuziy A. Dentoalveolar and skeletal changes associated with the pendulum appliance followed by fixed orthodontic treatment. *Am J Orthod Dentofacial Orthop* 2006;129:520-7.