

Pseudoaneurysm with Arteriovenous Fistula after Arthroscopic Procedure: A Rare Complication of Arthroscopy

Moran Jin, M.D., Yang-Haeng Lee, M.D., Young Chul Yoon, M.D., Il-Yong Han, M.D.,
Kyung-Taek Park, M.D., Jin Hong Wi, M.D.

Pseudoaneurysm with arteriovenous fistula is a rare complication of arthroscopy, and can be diagnosed by ultrasonography, computed tomography, magnetic resonance imaging, or angiography. This condition can be treated with open surgical repair or endovascular repair. We report our experience with the open surgical repair of a pseudoaneurysm with an arteriovenous fistula in a young male patient who underwent arthroscopy five months previously.

Key words: 1. Arteries
2. Aneurysm, false
3. Surgery, complications
4. Arthroscopy
5. Knee

CASE REPORT

A 23-year-old male with no significant prior medical history underwent arthroscopic surgery due to a cruciate ligament injury five months before being referred to the Department of Thoracic & Cardiovascular Surgery in Busan Paik Hospital. After surgery, a pulsatile mass was palpable around the previous surgical wound in the superomedial part of the right knee, and was observed to be growing continuously. He was therefore referred to our department. On physical examination, a 6×4-cm pulsatile oval-shaped mass was detected. On auscultation, we could detect bruits over the mass. The mass was clinically suspected to be an aneurysm, and computed tomography (CT) angiogram of the lower extremities was therefore performed. The angiogram revealed a 2.2-cm pseudoaneurysm of the descending genicular artery and a fistula with

the superficial vein of the right vastus medialis (Figs. 1, 2). We did not consider endovascular treatment because the patient was young and the mass was near the knee joint, leading to the possibility of stent-related and coil-related complications during his lifetime. We performed pseudoaneurysmectomy and ligation of the arteriovenous fistula (AVF). During the operation, we dissected and resected the pseudoaneurysm after ligating the AVF (Fig. 3). After surgery, we confirmed the flow of the right popliteal artery using Doppler imaging. The patient's postoperative course was unremarkable, and he was discharged on the seventh postoperative day.

DISCUSSION

Pseudoaneurysm has been reported as a complication after arthroscopy, arthroplasty, ligament repair, synovectomy, pene-

Department of Thoracic and Cardiovascular Surgery, Busan Paik Hospital, Inje University College of Medicine

Received: August 18, 2014, Revised: October 27, 2014, Accepted: October 28, 2014, Published online: August 5, 2015

Corresponding author: Yang-Haeng Lee, Department of Thoracic and Cardiovascular Surgery, Busan Paik Hospital, Inje University College of Medicine, 75 Bokji-ro, Busanjin-gu, Busan 614-735, Korea
(Tel) 82-51-890-6834 (Fax) 82-51-891-1297 (E-mail) ctslee@inje.ac.kr

© The Korean Society for Thoracic and Cardiovascular Surgery. 2015. All rights reserved.

© This is an open access article distributed under the terms of the Creative Commons Attribution Non-Commercial License (<http://creativecommons.org/licenses/by-nc/4.0>) which permits unrestricted non-commercial use, distribution, and reproduction in any medium, provided the original work is properly cited.

trating knee trauma, and intramedullary nailing of the tibia. The most common cause of pseudoaneurysm has been found to be total knee replacement, and the most common site of pseudoaneurysm has been found to be the popliteal artery [1]. However, pseudoaneurysms of the descending genicular artery, sural artery, and arterial branches to the vastus medialis muscle and the medial head of the gastrocnemius muscle have also been reported [2]. Wilson et al. [3] found that the incidence of vascular lesions among patients undergoing elective orthopedic surgery was 0.005%. In 1986, Committee on Complications of the Arthroscopy Association of North America [4] reported that nine patients out of 375,000 cases developed pseudoaneurysms after knee arthroscopy. Nonetheless, no case of pseudoaneurysm combined with an AVF of the descending genicular artery has yet been reported. Most

cases of pseudoaneurysm have been reported to occur in the popliteal artery [5].

Pseudoaneurysm generally occurs after acute trauma, which may or may not be surgical, or after chronic repeated trauma. Theoretically, an injury to the arterial wall appears to be necessary for a pseudoaneurysm to develop. In some cases, pseudoaneurysms have been observed to form after knee arthroscopy without penetration of the knee capsule or direct injury to the vessel wall. One possible explanation for this is the shear stress on the knee structures and arteries during surgery [1].

Pseudoaneurysm can be diagnosed by physical examination, ultrasonography (USG) with vascular Doppler imaging, CT, magnetic resonance imaging, and angiography. Symptoms and signs may include a range of pain from no discomfort to aggravated pain, the presence of a pulsating mass or a large hematoma with audible bruit or thrill, and space-occupying effects such as nerve compression, neuralgia, venous compression, and thrombosis [1,2]. If a pseudoaneurysm presents subcutaneously or grows to the point of being palpable, as occurred in our case, it can be suspected clinically. USG with Doppler imaging is a non-invasive technique that can confirm the abnormal anatomical relationship of the artery. Moreover, small pseudoaneurysms can be treated by USG-guided compression or USG-guided thrombin injection. CT angiography with three-dimensional reconstruction is now relatively easy to perform in Korea. It is helpful for confirming the anatomic structures around the pseudoaneurysm, and it takes less time than other methods such as sonogram, conventional angiography, magnetic resonance imaging. However, contrast enhancement

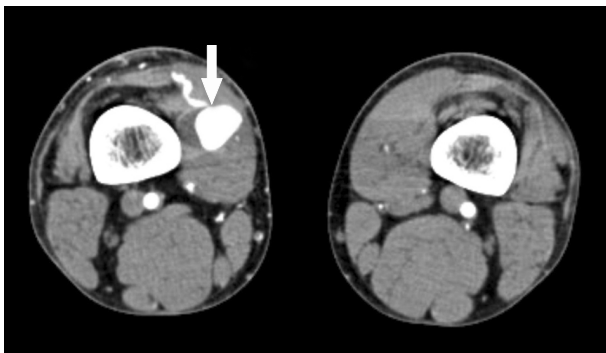


Fig. 1. Transverse view of computed tomography angiography showing a pseudoaneurysm and fistula of the superficial vein (solid arrow).

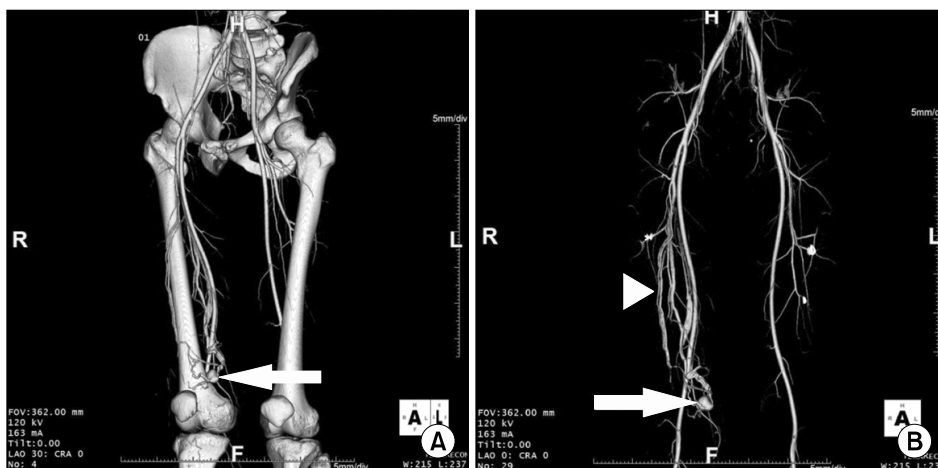


Fig. 2. Computed tomographic angiogram with three-dimensional reconstruction. (A) A pseudoaneurysm (solid arrow) above the right knee is shown. (B) A pseudoaneurysm (solid arrow) with venous enhancement (arrowhead) in the arterial phase. The arterio-venous fistula was accompanied on the pseudoaneurysm in this case.

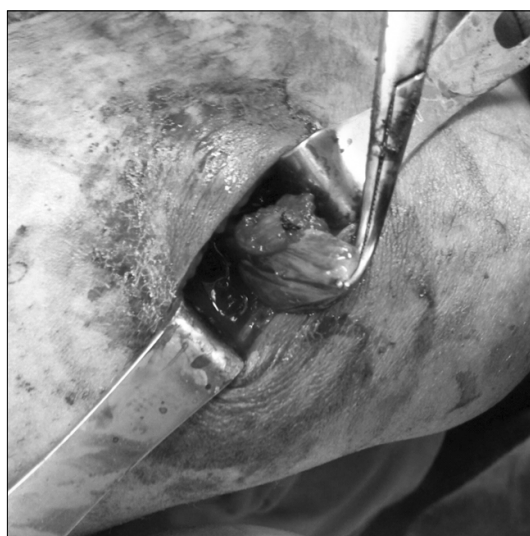

Fig. 3. Intraoperative finding of a pseudoaneurysm after ligation of the feeding arteries.

is necessary and exposure to radiation cannot be avoided. MRI has similar characteristics to CT, but has the advantage of avoiding radiation exposure. Angiography was historically considered the gold standard, but it was also considered to be more invasive than other imaging modalities. Angiography is currently used in the treatment of pseudoaneurysm for embolization and stent insertion [1,2,5,6].

No consensus yet exists on the optimal management of pseudoaneurysms. Some researchers have reported successful results by observing small aneurysms until spontaneous thrombosis, as well as the use of thrombin injection or USG-guided compression therapy [1]. Open surgical repair with excision, ligation of the pseudoaneurysm, inverted saphenous interposition grafting or bypass, and primary repair of the defect have been reported [5]. Some studies have reported the use of endovascular repair with embolization and stent insertion to treat popliteal pseudoaneurysms or AVF [1,2,5,6]. The studies that reported the endovascular repair of popliteal pseudoaneurysms showed that stent implantation has the advantage of avoiding the complications of open repair, such as wound infection, the need for general anesthesia, and a hospital stay [1]. Endovascular repair can lead to complications such as displacement, fracture, occlusion of the stent, or endoleak; however, the above studies did not report stent-related complications over the course of 24 months of follow-up.

Hilborn et al. [7] reported that thrombosis can occur spontaneously or be induced by compression from the echography probe in aneurysms smaller than 2 cm. For aneurysms less than 5 cm, it may be sufficient to ligate the defect in the arterial wall or to administer a percutaneous injection of thrombin into the aneurysmal sac along with therapeutic embolization by means of coils or thrombin injection. For bigger lesions, surgical exclusion of the aneurysm should be performed and blood flow should be restored via bypass surgery [7]. In our case, the pseudoaneurysm was too close to the knee joint and was accompanied by an AVF; therefore, we chose surgical treatment in order to avoid the possible complications of endovascular treatment.

In conclusion, pseudoaneurysm is a rare complication after arthroscopy that may lead to serious complications. If a pseudoaneurysm is suspected clinically, USG, CT, or magnetic resonance imaging are helpful imaging modalities for arriving at a diagnosis. Once the diagnosis of pseudoaneurysm is confirmed, a choice must be made between endovascular repair and surgical repair.

CONFLICT OF INTEREST

No potential conflict of interest relevant to this article was reported.

REFERENCES

1. Audenaert E, Vuylsteke M, Lissens P, Verhelst M, Verdonk R. *Pseudoaneurysm complicating knee arthroscopy: a case report.* Acta Orthop Belg 2003;69:382-4.
2. Mufty S Jr, Smits P, Feyen J. *Pseudoaneurysm of the superior medial genicular artery following knee arthroscopy.* Knee Surg Sports Traumatol Arthrosc 2011;19:1314-5.
3. Wilson JS, Miranda A, Johnson BL, Shames ML, Back MR, Bandyk DF. *Vascular injuries associated with elective orthopedic procedures.* Ann Vasc Surg 2003;17:641-4.
4. Committee on Complications of the Arthroscopy Association of North America. *Complications in arthroscopy: the knee and other joints.* Arthroscopy 1986;2:253-8.
5. Alserr AH, Antonopoulos CN, Papapetrou A, Kakisis JD, Brountzos E, Liapis CD. *Endovascular repair of popliteal artery pseudoaneurysm with arteriovenous fistula after knee arthroscopy: case report and literature review.* Vasc Endovascular Surg 2014;48:166-70.

6. Mello W, de Brito WE, Migon EZ, Borges A. *Pseudoaneurysm of the medial inferior genicular artery after anterior cruciate ligament reconstruction*. Arthroscopy 2011;27:442-5.
7. Hilborn M, Munk PL, Miniaci A, MacDonald SJ, Rankin RN, Fowler PJ. *Pseudoaneurysm after therapeutic knee arthroscopy: imaging findings*. AJR Am J Roentgenol 1994; 163:637-9.