

Gastric Dilatation and Volvulus in Shih-tzu

Joon Ho Moon^{*†}, Hyun Ah Kim^{*†}, Minok Ryu^{*†}, Min Jang^{*}, Seoyeon Ji^{*}, Inhyung Lee^{*},
Junghee Yoon^{*}, Mincheol Choi^{*}, Hwayoung Youn^{*}, Byeong Chun Lee^{*} and Goo Jang^{***†}

**Department of Veterinary Clinical Sciences, College of Veterinary Medicine, Seoul National University, Seoul 151-742, Korea*

***Emergence Center for Food-Medicine Personalized Therapy System, Advanced Institutes of Convergence Technology, Seoul National University, Gyeonggi-do 443-270, Korea*

(Accepted: April 09, 2015)

Abstract: Gastric dilatation and volvulus (GDV) is an acute and life-threatening disease most commonly affecting large- and giant-breed dogs. However a 17-year-old Shih-tzu (4 kg, spayed female) was hospitalized for acute GDV. Repeated unproductive retching, lethargy, and excessively enlarged abdomen were observed. Physical examination indicated that the patient had suffered from hypothermia (36.5°C), tachycardia (240 bpm), slowed capillary refill time (> 2 sec.), and pale mucous membrane. Grade III murmur with normal lung sound was auscultated. Abdominal palpation revealed that tympanic regions existed in both the left and right sides. Systolic blood pressure decreased gradually from 220 to 40 mmHg within 4 hours. In blood analysis, slight azotemia was observed by blood urea nitrogen (BUN; 29.1 mg/dl) and creatinine (1.6 mg/dl). Blood lactate concentration (8.13 mmol/l) was severely elevated. Additionally, dilatation and volvulus of the stomach was observed by radiograph. Supportive oxygen, heat, fluid, and drugs were administered with gastric decompressions (e.g., gastrocentesis and nasogastric tube). However the patient entered into comatose status with uncontrollable systolic blood pressure, despite the administration of dobutamine intravenously. The case was closed by euthanasia, considering welfare and age. We finally diagnosed the patient as a GDV, thus this is the first GDV case report in small-breed dog such as Shih-tzu.

Key words: Gastric dilatation and volvulus (GDV), Small breed dog, Shih-tzu.

Introduction

Gastric dilatation and volvulus (GDV) is an acute and life-threatening medical condition that most commonly occurs in large- or giant-breed dogs (14). Those affected animals are characterized by distention of the stomach that is filled with gas and fluid (7). Also, foreign bodies in the stomach cause GDV in dogs. The enlarged stomach tends to translocate to various degrees and increases pressure in the abdomen.

The etiology of GDV is unknown although several risk factors, including age, gender, exercise intensity, body weight, feed, and temperature (4-6,9,10,13) have been identified (12). It mostly occurs in purebred, large or giant breeds (especially with a deep and narrow thoracic cavity). The mortality rate of GDV is approximately 10-43% (1-3,6,8, 11).

In this report, a previously managed patient in Animal Hospital at Seoul National University for a heart problem came to aid by emergency with a severely dilated abdomen. A dilated stomach was observed by radiograph. The substances in the stomach were removed immediately by transcatheter gastrocentesis and nasogastric tube with supportive oxygen, heat, fluid, and drugs. However, despite the addition of dobutamine intravenously (IV), the patient entered into comatose status with uncontrollable systolic blood pressure.

This case was closed by euthanasia, as was decided by the owner out of consideration of welfare and age of patient. We may have experienced GDV in a small-breed dog, which was not commonly reported by veterinarians. The purpose of this case report was to describe that GDV also occurred in a small-breed dog, such as Shih-tzu.

Case

Medical history

A Shih-tzu (spayed female, 4 kg, and 17 years old) had been treated for three years in our animal hospital. Anamneses were mucocele in gallbladder, regenerative mass in liver, pulmonary regurgitation, tricuspid valve regurgitation, and right adrenal gland enlargement. This patient was rushed to the emergency room with severe abdominal distention. Repeated unproductive retching, lethargy, and excessively enlarged abdomen were observed. The patient's general status (body condition score: 2/9, body temperature: 36.5°C, heart rate: 240 bpm, respiratory rate: 30 times/min., capillary refill time: > 2 sec., mucous membrane color: pale and dry) was determined by physical examination. A grade III murmur with normal lung sound was found by auscultation. Abdominal palpation revealed that tympanic regions existed in both the left and right sides. Systolic blood pressure measured using a Doppler system was 220 mmHg at the first time of evaluation. Patient showed severe hypertension at the time of coming to aid. However, systolic blood pressure gradually decreased

[†]These authors contribute equally to this work

[†]Corresponding author.

E-mail : snujang@snu.ac.kr

Table 1. Hematological and biochemical evaluation values of a Shih-tzu with putative gastric dilatation and volvulus

Parameters	Results	Norms
WBC (m/mm ³)	14,850	6,000-17,000
Platelet (m/mm ³)	281	120-600
RBC (m/mm ³)	443*	550-850
Hct (%)	29.9*	35.0-55.0
Hb (g/dl)	9.7*	10.0-18.0
BUN (mg/dl)	29.1	9.2-29.2
Creatinine (mg/dl)	1.6**	0.2-1.4
Na ⁺ (mEq/l)	148	141-152
K ⁺ (mEq/l)	4.4	3.8-5.0
Cl ⁻ (mEq/l)	105	102-117

WBC = white blood cell; RBC = red blood cell; Hct = hematocrit; Hb = hemoglobin; BUN = blood urea nitrogen; Na⁺ = sodium; K⁺ = potassium; Cl⁻ = chloride.

* = lower than reference range, ** = higher than reference range.

to 40 mmHg within 4 hours.

Blood collection and analysis

Blood was collected from the jugular vein. A complete blood-cell count (CBC), serum chemistry, and blood-gas analysis were performed using a cell counter analyzer (MS9-5V; Melet schloosing laboratories, Osny, France), automated clinical chemistry analyzer (Fuji Dri-chem 4000i; Fujifilm co., Tokyo, Japan), and blood-gas analyzer (OSMETECH OPTI CCA Blood Gas Analyzer; OPTI Medical Systems, Inc., Georgia, USA), respectively.

In the CBC results, white blood cell (WBC) and platelets were in normal ranges: 14,850 m/mm³ and 281 m/mm³, respectively (Table 1). However, the value of red blood cells (RBC), hematocrit (Hct), and hemoglobin (Hb) were depressed: 443 m/mm³, 29.9%, and 9.7 g/dl, respectively (Table 1). All electrolytes were within normal ranges, but slight azotemia was observed in blood urea nitrogen (BUN) and creatinine results: 29.1 mg/dl and 1.6 mg/dl, respectively.

Table 2. Values from blood gas analysis in vein of a Shih-tzu with putative gastric dilatation and volvulus

Parameters	Results	Norms
pH	7.27*	7.35-7.45
PvCO ₂ (mmHg)	69**	29-45
PvO ₂ (mmHg)	32*	40-50
BE (mmol/l)	3.2	-5-+5
HCO ₃ ⁻ (mmol/l)	31.4**	24-28
Lactate (mmol/l)	8.13**	0.5-2.5

PvCO₂ = partial pressure of carbon dioxide in venous blood; PvO₂ = partial pressure of oxygen in venous blood; BE = base excess; HCO₃⁻ = bicarbonate.

* = lower than reference range, ** = higher than reference range.

Abnormal results of blood gas for evaluating the patient's metabolic status were observed in pH 7.27, partial pressure of carbon dioxide in vein (PvCO₂) 68 mmHg, partial pressure of oxygen in vein (PvO₂) 32 mmHg, and bicarbonate (HCO₃⁻) 31.4 mmol/l (Table 2). Hypercarpnia and hypoxia were diagnosed with hypoventilation. Additionally, blood lactate concentration was elevated to 8.13 mmol/l for which the normal range is from 0.5 to 2.5 mmol/l.

Imaging Diagnosis

Radiographs of the right lateral and ventrodorsal views were obtained (EVA-HF525; Toshiba co., Tokyo, Japan). The stomach was highly dilated by gas in the right lateral view. Enlarged pylorus and duodenum were located in the dorsal direction of the abdominal cavity. Typical Popeye's arm was observed in the abdominal part of the patient. In the ventrodorsal view, the pylorus and duodenum were translocated to the left. Moreover, decreased serosal detail indicated peritonitis or a small amount of ascites (Fig 1).

Discussion

GDV commonly affects large- and giant-breed dogs and is an acute and life-threatening situation in veterinary science.

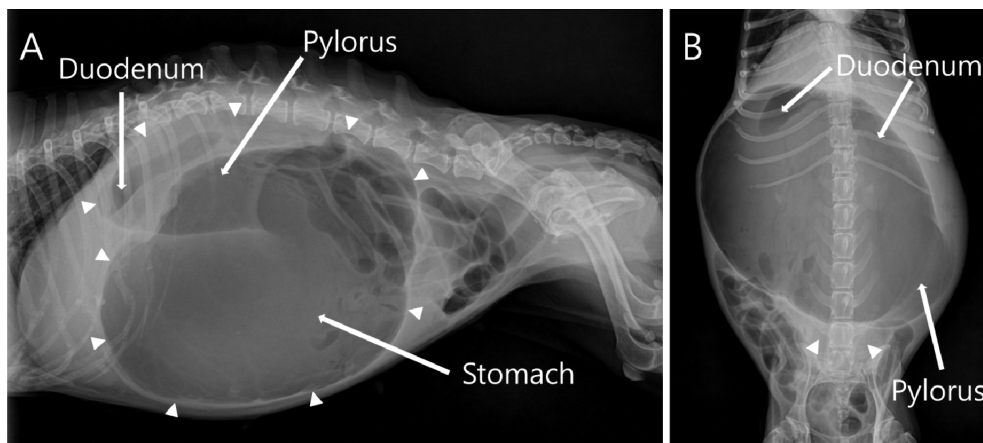


Fig 1. Radiographs of gastric dilatation and volvulus in Shih-tzu. (A) Right lateral view. The stomach was highly dilated by gas. Enlarged pylorus and duodenum were displaced to dorsal direction. A typical 'Popeye's arm' was observed in the abdominal part of the patient (arrowheads). (B) Ventrodorsal view. The pylorus and duodenum were translocated to the left. Decreased serosal detail indicated peritonitis or a small amount of ascites (arrowheads).

The mortality rate of GDV is 10-43% (1-3,6,8,11). However GDV in small-breed dogs is hardly reported.

GDV normally occurs after heavy exercise and recent feeding. Repeated unproductive retching, restlessness, abdominal distension, hypersalivation, and tachycardia are common features of GDV. The predominant method for definite diagnosis in GDV cases is radiography with supportive blood analysis. To treat GDV patients, blood analysis with a pre-treatment sample is necessary. Subsequently, aggressive fluid therapy, with oxygen and heat, must be administered with constant observation of systolic blood pressure (more than 100 mmHg) and urine output (at least 1 to 2 ml/kg/hr). In severe GDV cases, transcutaneous gastrocentesis has to be applied immediately. The site of gastrocentesis is commonly chosen as the left side of the abdomen in order to avoid puncture of spleen. Surgical fixation of a turned stomach has to be started as soon as possible. In case of surgery delays, the largest available diameter of orogastric tube has to be administered followed by gastric lavage. Applications of narcotic analgesics are recommended.

In this case, surgical fixation was delayed owing to patient age (17 years old) and many anamneses (e.g., mucocele in gallbladder, regenerative mass in liver, pulmonary regurgitation, tricuspid valve regurgitation, and right adrenal gland enlargement). Thus, supportive oxygen and heat therapies were administered continuously. Aggressive fluid therapy was essential to this patient, but crackle sounds were auscultated on both sides of the lung field, even at 15 ml/kg/hr of infusion speed. Thus the infusion speed was reduced to 10 ml/kg/hr. A subsequent radiograph showed a markedly dilated stomach (Fig 1). For gastric decompression, gastrocentesis was accomplished on both the left and right part of abdomen with consideration of splenic puncture during left side transcutaneous gastrocentesis. After removing gas and fluid by gastrocentesis, the abdomen was rapidly bloated again. A nasogastric tube was applied immediately then additional fluid was removed through that tube. Several drugs-cephradine (30 mg/kg; to control bacterial infection), tramadol (4 mg/kg; to reduce pain), and famotidine (0.5 mg/kg; to protect stomach)-were administered via IV. In order to affect a timely reduction of systolic blood pressure, the dobutamine infusion rate was also increased. Despite these clinical efforts, the patient entered into a comatose condition, followed by euthanasia as per the owner's decision with consideration of welfare and age.

Conclusion

Gastric dilatation and volvulus (GDV) is an emergency condition that requires rapid surgical fixation. Moreover, GDV can occur even in small animal breeds. GDV can be one unanticipated diagnosis when small animal breeds are suffering from dilated abdomen.

Acknowledgement

This study was financially supported by the Research Institute of Veterinary Science, Biogreen (PJ0090962012), Korea

IPET (#114059-3) and BK21 PLUS Program for Creative Veterinary Science Research.

References

1. Brockman DJ, Washabau RJ, Drobatz KJ. Canine gastric dilatation/volvulus syndrome in a veterinary critical care unit: 295 cases (1986-1992). *J Am Vet Med Assoc* 1995; 207: 460-464.
2. Brouman JD, Schertel ER, Allen DA, Birchard SJ, DeHoff WD. Factors associated with perioperative mortality in dogs with surgically managed gastric dilatation-volvulus: 137 cases (1988-1993). *J Am Vet Med Assoc* 1996; 208: 1855-1858.
3. de Papp E, Drobatz KJ, Hughes D. Plasma lactate concentration as a predictor of gastric necrosis and survival among dogs with gastric dilatation-volvulus: 102 cases (1995-1998). *J Am Vet Med Assoc* 1999; 215: 49-52.
4. Denler R, Koch D, Hassig M, Howard J, Montavon PM. Climatic conditions as a risk factor in canine gastric dilatation-volvulus. *Vet J* 2005; 169: 97-101.
5. Evans KM, Adams VJ. Mortality and morbidity due to gastric dilatation-volvulus syndrome in pedigree dogs in the UK. *J Small Anim Pract* 2010; 51: 376-381.
6. Glickman LT, Glickman NW, Perez CM, Schellenberg DB, Lantz GC. Analysis of risk factors for gastric dilatation and dilatation-volvulus in dogs. *J Am Vet Med Assoc* 1994; 204: 1465-1471.
7. Glickman LT, Glickman NW, Schellenberg DB, Raghavan M, Lee TL. Incidence of and breed-related risk factors for gastric dilatation-volvulus in dogs. *J Am Vet Med Assoc* 2000; 216: 40-45.
8. Glickman LT, Lantz GC, Schellenberg DB, Glickman NW. A prospective study of survival and recurrence following the acute gastric dilatation-volvulus syndrome in 136 dogs. *J Am Anim Hosp Assoc* 1998; 34: 253-259.
9. Green TI, Tonozzi CC, Kirby R, Rudloff E. Evaluation of initial plasma lactate values as a predictor of gastric necrosis and initial and subsequent plasma lactate values as a predictor of survival in dogs with gastric dilatation-volvulus: 84 dogs (2003-2007). *J Vet Emerg Crit Care* 2011; 21: 36-44.
10. Hendriks MM, Hill KE, Cogger N, Jones BR, Cave NJ. A retrospective study of gastric dilatation and gastric dilatation and volvulus in working farm dogs in New Zealand. *N Z Vet J* 2012; 60: 165-170.
11. Mackenzie G, Barnhart M, Kennedy S, DeHoff W, Schertel E. A retrospective study of factors influencing survival following surgery for gastric dilatation-volvulus syndrome in 306 dogs. *J Am Anim Hosp Assoc* 2010; 46: 97-102.
12. Monnet E. Gastric dilatation-volvulus syndrome in dogs. *Vet Clin North Am Small Anim Pract* 2003; 33: 987-1005.
13. Van Kruiningen HJ, Gargamelli C, Javier J, Frueh S, Jin L, Suib S. Stomach gas analyses in canine acute gastric dilatation with volvulus. *J Vet Intern Med* 2013; 27: 1260-1261.
14. Ward MP, Patronek GJ, Glickman LT. Benefits of prophylactic gastropexy for dogs at risk of gastric dilatation-volvulus. *Prev Vet Med* 2003; 60: 319-329.

시츄에서 발견된 위확대염전

문준호*† · 김현아*† · 류민욱*† · 장민* · 지서연* · 이인형* · 윤정희* · 최민철* · 윤화영* · 이병천* · 장구***1

*서울대학교 수의과대학 수의임상학, **서울대학교 차세대융합기술연구원 식의약맞춤치료시스템개발센터

요 약 : 위확대염전 (gastric dilatation and volvulus; GDV)는 위급하고 생명을 위협하는 질병으로 보통 대형견에서 호발한다. 하지만 17살 Shih-tzu (4 kg, 중성화 암컷)가 급성 위확대염전으로 응급내원한 경우가 있었다. 내원했을 당시 지속적인 헛구역질, 무기력, 그리고 과도하게 확장된 복부가 관찰되었다. 신체검사상 환자는 저체온증 (36.5°C), 심박수 향진 (240 bpm), 느려진 모세혈관 재충만 시간 (> 2초)였고 점막은 창백한 색이었다. 폐음은 정상적이었지만 3단계의 murmur를 청진상 확인하였다. 복부타진을 통해서 복부 양쪽으로 공명하는 부위의 존재가 확인되었다. 수축기혈압은 220에서 시작해서 40 mmHg까지 4시간동안 점진적으로 감소하였다. 혈액검사상, blood urea nitrogen (BUN; 29.1 mg/dl)과 creatinine (1.6 mg/dl)의 값을 토대로 미약한 질소혈증 상태였다. 혈중 젖산 농도는 (8.13 mmol/l)로 심각하게 증가해 있었다. 추가적인 방사선 검사를 통해서 위확대염전을 확인하였다. 위내 압력을 줄이기 위해, 위천공과 비위삽관을 통한 기체와 액체 제거를 실시하는 동안 보조적으로 산소, 열, 수액, 그리고 약물들을 처치하였다. 또한 dobutamine의 정맥내투여에도 불구하고 수축기혈압이 일정하게 유지되지 않았고, 이에 따라 혼수상태에 빠지고 말았다. 환자의 나이와 복지를 고려하여 안락사가 결정되어 생을 마감하였다. 이번 경우는 최종적으로 위확대염전으로 진단되었으며, 이는 Shih-tzu와 같은 소형견에서 보고되는 첫 위확대염전 case라는 점에서 의의가 있다.

주요어 : 위확대염전, 소형견, Shih-tzu