

## Postoperative Outcomes of Mitral Valve Repair for Mitral Restenosis after Percutaneous Balloon Mitral Valvotomy

Ji Seong Lee, M.D., Hyun Keun Chee, M.D., Jun Seok Kim, M.D., Myong Gun Song, M.D.,  
Jae Bum Park, M.D., Je Kyoum Shin, M.D.

**Background:** There have been a number of studies on mitral valve replacement and repeated percutaneous mitral balloon valvotomy for mitral valve restenosis after percutaneous mitral balloon valvotomy. However, studies on mitral valve repair for these patients are rare. In this study, we analyzed postoperative outcomes of mitral valve repair for mitral valve restenosis after percutaneous mitral balloon valvotomy. **Methods:** In this study, we assessed 15 patients (mean age, 47.7±9.7 years; 11 female and 4 male) who underwent mitral valve repair between August 2008 and March 2013 for symptomatic mitral valve restenosis after percutaneous mitral balloon valvotomy. The mean interval between the initial percutaneous mitral balloon valvotomy and the mitral valve repair was 13.5±7 years. The mean preoperative Wilkins score was 9.4±2.6. **Results:** The mean mitral valve area obtained using planimetry increased from 1.16±0.16 cm<sup>2</sup> to 1.62±0.34 cm<sup>2</sup> (p=0.0001). The mean pressure half time obtained using Doppler ultrasound decreased from 202.4±58.6 ms to 152±50.2 ms (p=0.0001). The mean pressure gradient obtained using Doppler ultrasound decreased from 9.4±4.0 mmHg to 5.8±1.5 mmHg (p=0.0021). There were no early or late deaths. Thromboembolic events or infective endocarditis did not occur. Reoperations such as mitral valve repair or mitral valve replacement were not performed during the follow-up period (39±16 months). The 5-year event-free survival was 56.16% (95% confidence interval, 47.467–64.866). **Conclusion:** On the basis of these results, we could not conclude that mitral valve repair could be an alternative for patients with mitral valve restenosis after percutaneous balloon mitral valvotomy. However, some patients presented with results similar to those of mitral valve replacement. Further studies including more patients with long-term follow-up are necessary to determine the possibility of this application of mitral valve repair.

Key words: 1. Restenosis  
2. Mitral valve, repair  
3. Percutaneous mitral balloon valvotomy  
4. Complication

### INTRODUCTION

Percutaneous mitral balloon valvotomy (PMV) has been used widely for mitral stenosis since it was introduced in 1984 by Inoue et al. [1]. Further, symptomatic mitral valve restenosis after PMV occurs at the rate of 7% to 23% [2,3].

Treatment modalities in these cases include mitral valve replacement and repeated PMV. With respect to repeated PMV, recent studies have presented good intermediate and long-term outcomes [4,5]. Nevertheless, mitral valve replacement is usually preferred [6,7]. A number of studies have demonstrated the possibility of mitral valve repair for rheumatic mitral

Department of Thoracic and Cardiovascular Surgery, Konkuk University Medical Center, Konkuk University School of Medicine

Received: September 16, 2014, Revised: October 28, 2014, Accepted: November 7, 2014, Published online: October 5, 2015

Corresponding author: Je Kyoum Shin, Konkuk University Medical Center, 120-1 Neungdong-ro, Gwangjin-gu, Seoul 05030, Korea

(Tel) 82-2-2030-7595 (Fax) 82-2-2030-5009 (E-mail) jekshin@kuh.ac.kr

© The Korean Society for Thoracic and Cardiovascular Surgery. 2015. All right reserved.

© This is an open access article distributed under the terms of the Creative Commons Attribution Non-Commercial License (<http://creativecommons.org/licenses/by-nc/4.0>) which permits unrestricted non-commercial use, distribution, and reproduction in any medium, provided the original work is properly cited.

**Table 1.** Preoperative baseline characteristics of patients

Variable	Value
Age (yr)	47±10 (31–64)
Sex (male/female)	4/11
Interval time (yr) between PMV and mitral valvuloplasty	13±7 (3–25)
Functional class (New York Heart Association)	
I	0
II	6 (40)
III	8 (53.3)
IV	1 (6.7)
Rhythm	
Atrial fibrillation	9 (60)
Previous thromboembolism	2 (13.3)
Left atrial thrombosis	2 (13.3)
Second PMV	4 (26.7)
Echocardiographic score (Wilkins score)	9.4±2.6
Left atrial dimension (mm)	56.9±12.3
Mitral regurgitation	
Grade 1	3 (20)
Grade 2	2 (13.3)
Grade 3	0
Grade 4	0
Tricuspid regurgitation	
Grade 1	5 (33.3)
Grade 2	3 (20)
Grade 3	0
Grade 4	0

Values are presented as mean±standard deviation (range), number (%), or mean±standard deviation.

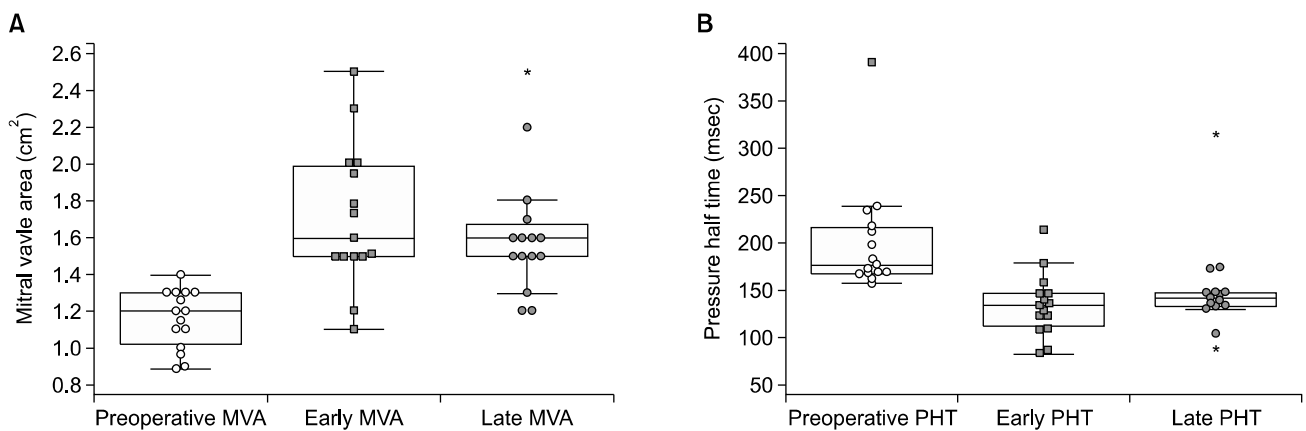
PMV, percutaneous balloon mitral valvotomy.

valve diseases, which were mostly mixed with stenosis and regurgitation [8-14]. However, mitral valve repair for rheumatic mitral valve stenosis is still uncommon. Accordingly, few reports on mitral valve repair for mitral valve restenosis after PMV have been published. In this study, we assessed postoperative outcomes of mitral valve repair for symptomatic mitral valve restenosis after PMV.

## METHODS

Between August 2008 and March 2013, 22 patients underwent mitral valve surgery for mitral valve disease at our center after they had undergone PMV for rheumatic mitral valve stenosis at different hospitals. Patients were excluded if they had significant (>grade 2) mitral regurgitation because this factor could affect the analyses by confounding variables and we were concerned about mitral valve restenosis after PMV. Three patients did not undergo follow-up echocardiography. In the end, 15 patients formed the subject population of this study. Preoperative baseline characteristics are given in Table 1. Mitral valve replacement was recommended to eight patients (53.3%) at different centers before visits to our center. The mean preoperative left ventricular ejection fraction was 59.5% ±7.9%. The mean mitral valve area was 1.15±0.16 cm<sup>2</sup> (Fig. 1A), and the mean pressure half time was 202.4±58.6 ms (Fig. 1B).

Right anterolateral thoracotomy was performed in 13 patients as a standard approach of surgery for mitral valve dis-



**Fig. 1.** (A) Comparison of preoperative and postoperative mitral valve area. (B) Comparison of preoperative and postoperative pressure half time. MVA, mitral valve area; PHT, pressure half time.

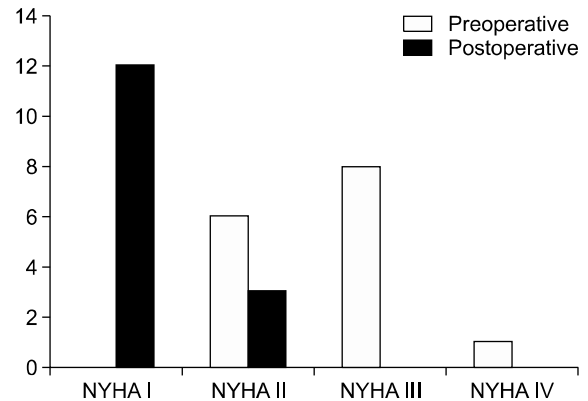
**Table 2.** Surgical technique for mitral valve repair and concomitant procedures

Variable	No. of patients (%)
Commissurotomy	14 (93.3)
Leaflet slicing	12 (80.0)
Decalcification	10 (66.7)
Posterior leaflet extension	14 (93.3)
Lifting mitral annuloplasty	15 (100.0)
Tricuspid annuloplasty	3 (20.0)
Maze	9 (60.0)
Left atrial appendage obliteration	2 (13.3)
Thrombectomy	2 (13.3)

ease or tricuspid valve disease at our center. Median sternotomy was performed in two patients who had very moderate forced expiratory volume to achieve one-lung ventilation. Each valve was assessed in direct vision and via intraoperative transesophageal echocardiography. All operations were performed by the same surgeon. Surgical techniques utilized for mitral valve repair and concomitant procedures are listed in Table 2. Posterior leaflet extension was performed with bovine pericardium (Supple Peri-Guard Repair Patch, 6×8 cm Synovis; Jisang International Inc., Seoul, Korea). Lifting mitral annuloplasty was performed with a mitral strip (Mitracon, Mitral Annuloplasty Ring, Mitracon Strip; Sciencity Co. Ltd., Seoul, Korea). Tricuspid annuloplasty was performed with a Carpentier- Edward ring.

Demographic clinical variables were collected retrospectively with a review of medical records. The optimal echocardiographic outcome was defined as a mitral valve area of more than 1.5 cm<sup>2</sup> and a pressure half time of less than 150 ms. Event-free survival means that in addition to these hemodynamic parameters, the New York Heart Association functional class (NYHA Fc) was less than III without reoperation events such as mitral valve repair and mitral valve replacement [4,5].

Statistical analyses were performed with PASW SPSS ver. 18.0 (SPSS Inc., Chicago, IL, USA). Categorical variables are expressed as percentages or numbers, and continuous variables are expressed as means with standard deviations. After testing for the normality of distribution, continuous variables were compared using the paired samples t-test or the Wilcoxon signed-rank test. The cumulative event-free survival curve



**Fig. 2.** Comparison of preoperative and postoperative New York Heart Association (NYHA) functional class.

was determined according to the Kaplan–Meier method. All p-values of less than 0.05 were considered statistically significant.

## RESULTS

All patients underwent follow-up for a mean duration of 39±16 months. There were no early or late deaths. One patient suffered from postoperative bleeding due to intercostal artery injury. There were no morbidities such as thromboembolic events, infective endocarditis, reoperations, or complications with respect to the use of warfarin during the follow-up period. Atrial fibrillation persisted in two of the nine patients who underwent the maze procedure. Thirteen patients presented with a sinus rhythm. The functional capacity of 12 patients (80%) improved from NYHA Fc II to NYHA Fc I. Three patients (20%) improved from NYHA Fc III or IV to NYHA Fc II (Fig. 2). Postoperatively, 13 patients were treated with warfarin for 2 months. Two patients with persistent atrial fibrillation were treated with aspirin alone after cessation of warfarin treatment. Two patients who had atrial thrombosis preoperatively were treated with warfarin for 6 months. When echocardiography revealed no atrial thrombosis 6 months later, these two patients were treated with aspirin alone. The range of the target international normalized ratio was 2.0 to 3.0.

### 1) Early postoperative echocardiographic results

In a comparison of early postoperative echocardiographic results with preoperative echocardiographic results, we found

**Table 3.** Comparison of preoperative with early echocardiographic results after MVP

Variable	Before MVP	Early after MVP	p-value
Left ventricular ejection fraction (%)	59.5±7.9	62.7±6.7	0.2529 <sup>a)</sup>
Valve area (cm <sup>2</sup> ) (planimetry)	1.16±0.16	1.71±0.4	0.0001 <sup>a)</sup>
Pressure half time (msec) (Doppler)	202.4±58.6	135.7±33.3	0.0001 <sup>b)</sup>
Mean pressure gradient (mmHg) (Doppler)	9.4±4.0	5.4±1.9	0.001 <sup>a)</sup>

Values are presented as mean±standard deviation.

MVP, mitral valve repair.

<sup>a)</sup>By paired samples t-test. <sup>b)</sup>By Wilcoxon signed-rank test.

**Table 4.** Comparison of preoperative with late echocardiographic results after MVP

Variable	Before MVP	Late after MVP	p-value
Left ventricular ejection fraction (%)	59.5±7.9	64.5±4.9	0.0276 <sup>a)</sup>
Valve area (cm <sup>2</sup> ) (planimetry)	1.16±0.16	1.62±0.34	0.0001 <sup>b)</sup>
Pressure half time (msec) (Doppler)	202.4±58.6	152±50.2	0.0001 <sup>b)</sup>
Mean pressure gradient (mmHg) (Doppler)	9.4±4.0	5.8±1.5	0.0021 <sup>a)</sup>

Values are presented as mean±standard deviation.

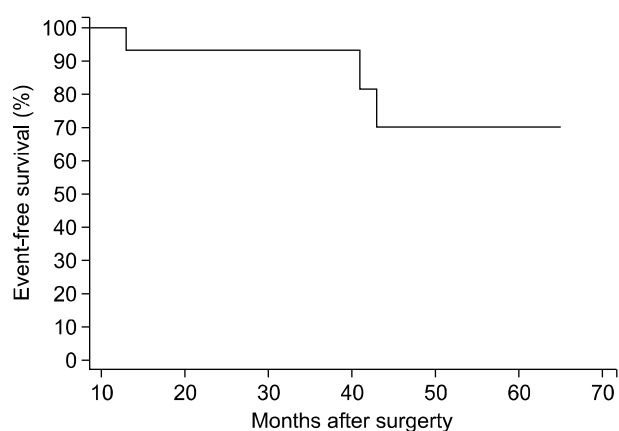
MVP, mitral valve repair.

<sup>a)</sup>By paired samples t-test. <sup>b)</sup>By Wilcoxon signed-rank test.

that the mean left ventricular ejection fraction increased from 59.5%±7.9% to 62.7%±6.7% ( $p=0.2529$ ), the mean mitral valve area increased from 1.16±0.16 cm<sup>2</sup> to 1.71±0.4 cm<sup>2</sup> ( $p<0.0001$ ), the mean pressure half time decreased from 202.4±58.6 ms to 135.7±33.3 ms ( $p=0.0001$ ), and the mean diastolic transmitral pressure gradient decreased from 9.4±4.0 mmHg to 5.4±1.9 mmHg ( $p=0.001$ ) (Table 3, Fig. 1). The mitral valve area in 13 patients was larger than 1.5 cm<sup>2</sup>. In the remaining two patients, the mitral valve area was smaller than 1.5 cm<sup>2</sup>. The mitral valve area increased slightly from 0.9 cm<sup>2</sup> to 1.1 cm<sup>2</sup> and 1.2 cm<sup>2</sup> in these two patients, respectively. Thirteen patients had no or trivial mitral regurgitation and the other two patients had mild mitral regurgitation (grade 1). Meanwhile, 13 patients presented no or trivial tricuspid regurgitation, and two patients had mild tricuspid regurgitation (grade 1).

## 2) Late postoperative echocardiographic results

In a comparison of the late postoperative echocardiographic results with the preoperative echocardiographic results, we found that the mean left ventricular ejection fraction increased from 59.5%±7.9% to 64.55%±4.9% ( $p=0.0276$ ), the mean mitral valve area increased from 1.16±0.16 cm<sup>2</sup> to 1.62±0.34 cm<sup>2</sup>



**Fig. 3.** Kaplan-Meier curves for 5-year event-free survival rate fulfilling with mitral valve area  $\geq 1.5$  cm<sup>2</sup> and New York Heart Association functional class I or II without reoperation (mitral valvuloplasty or mitral valve replacement; 95% confidence interval, 47.467 to 64.866).

( $p=0.0001$ ), the mean pressure half time decreased from 202.4±58.6 ms to 152±50.2 ms ( $p=0.001$ ), and the mean diastolic transmitral pressure gradient decreased from 9.4±4.0 mmHg to 5.8±1.5 mmHg ( $p=0.0021$ ) (Table 4, Fig. 1). In 12 patients (80%), the mitral valve area was larger than 1.5 cm<sup>2</sup>.

In the remaining three patients (20%), the mitral valve area was smaller than 1.5 cm<sup>2</sup>. In two of these three patients, the mitral valve area increased slightly from 0.9 cm<sup>2</sup> to 1.2 cm<sup>2</sup>. The remaining patient showed no changes in the mitral valve area (1.3 cm<sup>2</sup>). The degree of mitral regurgitation was less than grade 1 in all patients. Tricuspid regurgitation was less than grade 1 in 14 patients. One patient presented with grade 2 tricuspid regurgitation; she had not undergone tricuspid annuloplasty. The 5-year event-free survival rate was 56.16% (95% confidence interval, 47.467 to 64.866) (Fig. 3).

## DISCUSSION

Since PMV is commonly used worldwide for mitral valve stenosis, mitral valve restenosis is a frequent cause of late deterioration after PMV. Because of the severity of the valve disease in most of these patients, mitral valve replacement is usually performed. However, recent studies on repeated PMV for these patients reported good intermediate and long-term outcomes. Bouletti et al. [4,5] noted that repeated PMV enabled one out of three patients to remain free from any other surgery at 20 years and one out of five patients to exhibit good functional results at 20 years. Nevertheless, PMV is contraindicated in patients with left atrial thrombus or concomitant heart disease. Mitral valve replacement is preferred for these patients with symptomatic mitral restenosis after PMV, particularly in cases with unfavorable anatomy [6,7]. Song et al. [6] reported a better long-term outcome of mitral valve replacement; they considered patients who had an echocardiographic score of more than 8 with atrial fibrillation and suggested mitral valve replacement as the initial treatment for mitral valve stenosis. In a comparison of the long-term event-free survival rate between repeated PMV and mitral valve replacement for mitral restenosis after PMV, Kim et al. [7] demonstrated that the 3-year event-free survival rate was 96.6% for mitral valve replacement and 90% for repeated PMV. The 9-year event-free survival rate was 90.4% for mitral valve replacement and 36% for repeated PMV.

However, mitral valve replacement leads to life-long anti-coagulation therapy, increased hemolysis, and a long-term risk of prosthesis-related complications. The incidence rates of thromboembolic complications after bileaflet mechanical mitral

valve replacement despite oral anticoagulation therapy can be between 2.2% and 4.1% per year. Furthermore, in patients who have undergone mitral valve replacement, a relatively high target international normalized ratio (2.0–3.0) is recommended; this can result in a 2.5% annual risk of important bleeding events [10,15]. Although Kim et al. [14] demonstrated that a lower incidence rate of thromboembolic complications could be achieved by following a strict anticoagulation protocol, there are the inconveniences of oral anticoagulation therapy that include variability in dosing, the need for blood sampling, activity restrictions, and minor hemorrhagic complications [10].

Mitral valve repair allows for the avoidance of long-term anticoagulation therapy and preservation of left ventricular function, while yielding decreased thromboembolic complications, low perioperative mortality rates, a low risk of native valve endocarditis, and long-term freedom from reoperation [16]. In the case of degenerative mitral valve regurgitation, mitral valve repair is known to be better than mitral valve replacement [17-19]. However, in the case of rheumatic mitral valve disease, mitral valve repair is more technically challenging and has the disadvantage of more frequent reoperations than the repair for degenerative diseases [8,9,20]. Nevertheless, recent studies have suggested that mitral valve repair could be considered optimal treatment in selected patients [10-14]. These studies included patients who had predominant regurgitation and mixed stenosis with regurgitation and who underwent mitral valve repair as initial surgery without previous intervention. Our study excluded predominant mitral regurgitation in order to focus on mitral valve repair for mitral restenosis after PMV. Then, 13 of 15 patients had predominant mitral valve stenosis and the remaining two had mixed stenosis with regurgitation. In all the patients, the mean mitral valve area was 1.16±0.16 cm<sup>2</sup>, the mean preoperative Wilkins score was 9.4±2.6, and the mean mitral valve regurgitation grade was 0.53±0.9. From a technical perspective, the currently known techniques were used. Early outcomes were similar to those of repeated PMV [4,5] and mitral valve repair for rheumatic mitral disease [10-14]. In a comparison with mitral valve replacement, however, we found that a smaller mitral valve area was achieved, higher pressure half time was presented, and the durability of the repaired valve

was less than in the case of mitral valve replacement [6,7]. The early favorable outcomes worsened, and it was thought that rheumatic inflammatory processes would be affected. Some patients may have to undergo a reoperation soon. However, some patients presented with results similar to those of mitral valve replacement (Fig. 1A, B).

Because this study is limited in terms of the number of patients and the follow-up period, and does not consider a control group, further studies including more patients with a long-term follow-up and a comparison with a control group are necessary to determine the possibility of mitral valve repair in such cases.

In conclusion, on the basis of the study results, we cannot suggest mitral valve repair as an alternative for most patients with mitral valve restenosis after percutaneous mitral balloon valvotomy. However, in some patients with mitral restenosis after PMV, the mitral valve may be repairable. Therefore, a thorough and systematic assessment of the valve should be performed.

## CONFLICT OF INTEREST

No potential conflict of interest relevant to this article was reported.

## ACKNOWLEDGMENTS

This study was supported by a Grant of the Samsung Vein Clinic Network (Daejeon, Anyang, Cheongju, Cheonan; Fund No. KTCS04-031).

## REFERENCES

- Inoue K, Owaki T, Nakamura T, Kitamura F, Miyamoto N. *Clinical application of transvenous mitral commissurotomy by a new balloon catheter*. J Thorac Cardiovasc Surg 1984; 87:394-402.
- Iung B, Cormier B, Ducimetiere P, et al. *Functional results 5 years after successful percutaneous mitral commissurotomy in a series of 528 patients and analysis of predictive factors*. J Am Coll Cardiol 1996;27:407-14.
- Desideri A, Vanderperren O, Serra A, et al. *Long-term (9 to 33 months) echocardiographic follow-up after successful percutaneous mitral commissurotomy*. Am J Cardiol 1992;69:1602-6.
- Bouleti C, Iung B, Himbert D, et al. *Reinterventions after percutaneous mitral commissurotomy during long-term follow-up, up to 20 years: the role of repeat percutaneous mitral commissurotomy*. Eur Heart J 2013;34:1923-30.
- Bouleti C, Iung B, Himbert D, et al. *Long-term efficacy of percutaneous mitral commissurotomy for restenosis after previous mitral commissurotomy*. Heart 2013;99:1336-41.
- Song JK, Kim MJ, Yun SC, et al. *Long-term outcomes of percutaneous mitral balloon valvuloplasty versus open cardiac surgery*. J Thorac Cardiovasc Surg 2010;139:103-10.
- Kim JB, Ha JW, Kim JS, et al. *Comparison of long-term outcome after mitral valve replacement or repeated balloon mitral valvotomy in patients with restenosis after previous balloon valvotomy*. Am J Cardiol 2007;99:1571-4.
- Yau TM, El-Ghoneimi YA, Armstrong S, Ivanov J, David TE. *Mitral valve repair and replacement for rheumatic disease*. J Thorac Cardiovasc Surg 2000;119:53-60.
- Choudhary SK, Talwar S, Dubey B, Chopra A, Saxena A, Kumar AS. *Mitral valve repair in a predominantly rheumatic population: long-term results*. Tex Heart Inst J 2001; 28:8-15.
- El Oumeiri B, Boodhwani M, Glineur D, et al. *Extending the scope of mitral valve repair in rheumatic disease*. Ann Thorac Surg 2009;87:1735-40.
- Omeroglu SN, Kirali K, Mansuroglu D, et al. *Is posterior leaflet extension and associated commissurotomy effective in rheumatic mitral valve disease?: long-term outcome*. Tex Heart Inst J 2004;31:240-5.
- Bakir I, Onan B, Onan IS, Gul M, Uslu N. *Is rheumatic mitral valve repair still a feasible alternative?: indications, technique, and results*. Tex Heart Inst J 2013;40:163-9.
- Chan PG, Hayanga AJ, Badhwar V. *Repair of rheumatic mitral stenosis with bicommissural release, anterior leaflet augmentation and oversized annuloplasty*. Multimed Man Cardiothorac Surg 2014;2014:mmt020.
- Kim JB, Kim HJ, Moon DH, et al. *Long-term outcomes after surgery for rheumatic mitral valve disease: valve repair versus mechanical valve replacement*. Eur J Cardiothorac Surg 2010;37:1039-46.
- Salem DN, Stein PD, Al-Ahmad A, et al. *Antithrombotic therapy in valvular heart disease: native and prosthetic: the Seventh ACCP Conference on Antithrombotic and Thrombolytic Therapy*. Chest 2004;126(3 Suppl):457S-482S.
- DiBardino DJ, ElBardissi AW, McClure RS, Razo-Vasquez OA, Kelly NE, Cohn LH. *Four decades of experience with mitral valve repair: analysis of differential indications, technical evolution, and long-term outcome*. J Thorac Cardiovasc Surg 2010;139:76-83.
- Suri RM, Schaff HV, Dearani JA, et al. *Survival advantage and improved durability of mitral repair for leaflet prolapse subsets in the current era*. Ann Thorac Surg 2006;82:819-26.

Ji Seong Lee, et al

18. Enriquez-Sarano M, Schaff HV, Orszulak TA, Tajik AJ, Bailey KR, Frye RL. *Valve repair improves the outcome of surgery for mitral regurgitation: a multivariate analysis.* Circulation 1995;91:1022-8.
19. Gillinov AM, Cosgrove DM, Blackstone EH, et al. *Durability of mitral valve repair for degenerative disease.* J Thorac Cardiovasc Surg 1998;116:734-43.
20. Duran CM, Gometza B, Saad E. *Valve repair in rheumatic mitral disease: an unsolved problem.* J Card Surg 1994;9(2 Suppl):282-5.