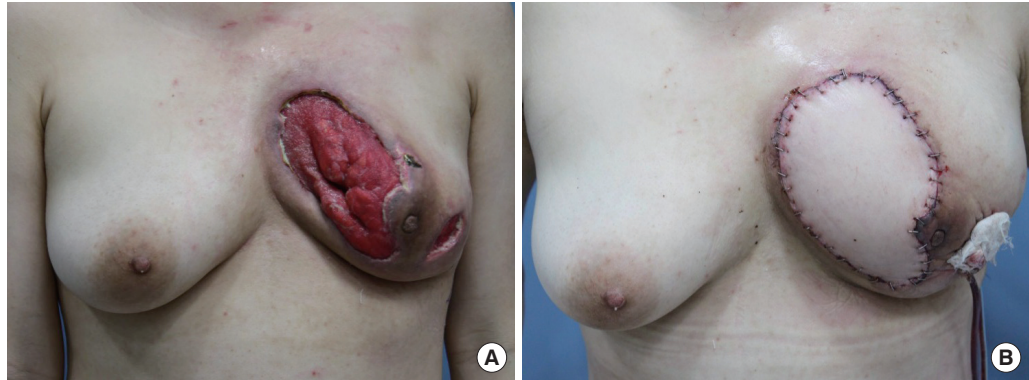


**Fig. 3.**

Preoperative and postoperative photos of the patient. (A) After several debridements, extended defects remained through the skin and soft tissue in the left breast. (B) The defects were covered with a latissimus dorsi musculocutaneous flap and a full-thickness skin graft.



## References

1. Edlich RF, Cross CL, Dahlstrom JJ, et al. Modern concepts of the diagnosis and treatment of necrotizing fasciitis. *J Emerg Med* 2010;39:261-5.
2. Yang B, Connolly S, Ball W. Necrotising fasciitis of the breast: a rare primary case with conservation of the nipple and literature review. *JPRAS Open* 2015;6:15-9.

## A Band-Like Neck Scar Contracture after Bilateral Axillo-Breast Approach Robotic Thyroidectomy

Do Hoon Kwak, Woo Seob Kim, Han Koo Kim, Tae Hui Bae

Department of Plastic and Reconstructive Surgery, Chung-Ang University Medical School, Seoul, Korea

**Correspondence:** Woo Seob Kim  
Department of Plastic and Reconstructive Surgery, Chung-Ang University Medical School, 102 Heukseok-ro, Dongjak-gu, Seoul 06973, Korea  
Tel: +82-2-6299-1615, Fax: +82-2-6298-1866  
E-mail: kimws@cau.ac.kr

No potential conflict of interest relevant to this article was reported.

Received: 17 Mar 2016 • Revised: 7 Jul 2016 • Accepted: 12 Jul 2016  
pISSN: 2234-6163 • eISSN: 2234-6171  
<https://doi.org/10.5999/aps.2016.43.6.614>  
*Arch Plast Surg* 2016;43:614-615

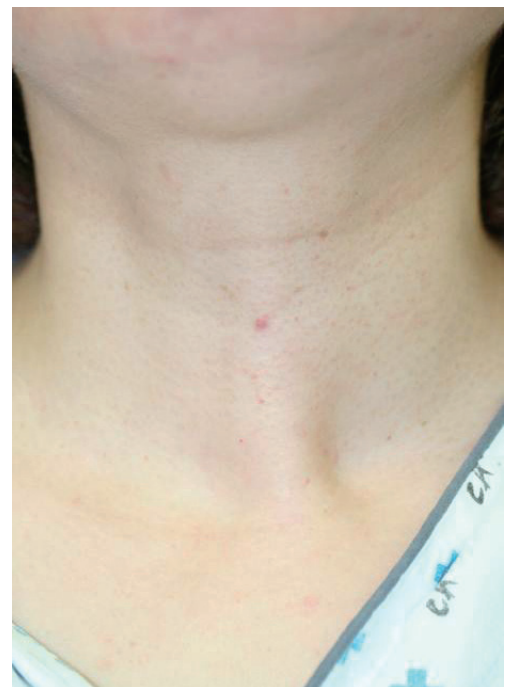

Copyright © 2016 The Korean Society of Plastic and Reconstructive Surgeons  
This is an Open Access article distributed under the terms of the Creative Commons Attribution Non-Commercial License (<http://creativecommons.org/licenses/by-nc/4.0/>) which permits unrestricted non-commercial use, distribution, and reproduction in any medium, provided the original work is properly cited.

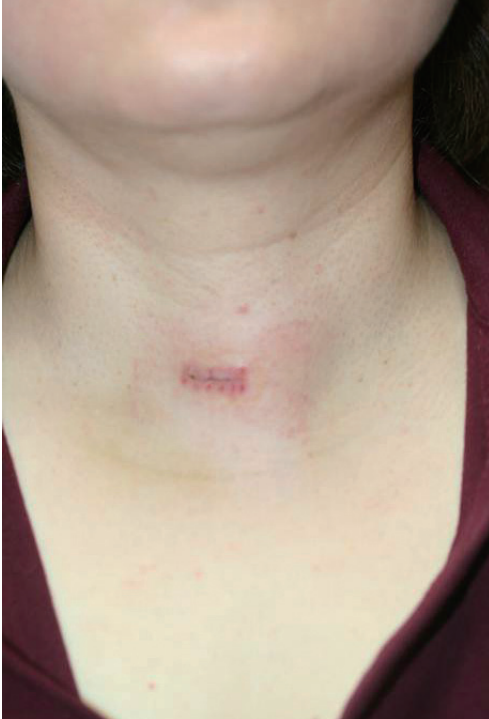Recently, robotic surgical operations have been performed in many surgical areas because the oncologic results are almost the same as conventional surgery but robotic surgery requires an incision of only a few centimeters to approach the surgical site

[1]. Thus, many patients with thyroid cancer choose robotic surgery because of reduced scarring [2].

A 39-year-old female patient with thyroid cancer of the right lobe underwent robotic thyroidectomy via a bilateral axillo-breast approach, both axillary and mammillary [3]. After 7 months, she felt tightness in her chest and neck. She was diagnosed with major depressive disorder and panic disorder in relation to these symptoms. A band-like lesion appeared 1 year after thyroidectomy (Fig. 1). The chest and neck were connected with band-like scar tissue. During swallowing, the chest and neck moved simultaneously.

**Fig. 1.**

One year after thyroidectomy, band-like scar tissue appeared and the patient experienced discomfort of the neck and chest. The neck and chest moved simultaneously during swallowing.



**Fig. 2.** The band-like scar tissue disappeared after surgery. The neck and chest moved separately.

Tracheal and soft tissue involving the dermis layer had adhered from the neck to the chest along the left approach track. After removing the scar tissue, the adhered site was covered with deep cervical fascia and subcutaneous fat tissue using an anti-adhesive agent. After surgery, the band-like scar tissue disappeared and symptoms improved (Fig. 2).

This case involved a rare complication from a bilateral axillo-breast approach robotic thyroidectomy. Although robotic surgery has advantages in terms of scar appearance, it can also cause internal scarring under the surgical site. In this case, a scar formed beneath the skin layer. Approaches close to the skin may lead to band-like scar formation. Therefore, especially in dynamic areas like the neck and joint, surgeons should ensure that the surgical approach is not too shallow.

## References

1. Kandil E, Hammad AY, Walvekar RR, et al. Robotic thyroidectomy versus nonrobotic approaches: a meta-analysis examining surgical outcomes. *Surg Innov* 2016;23:317-25.
2. Koo DH, Kim DM, Choi JY, et al. In-depth survey of scarring and distress in patients undergoing bilateral

axillo-breast approach robotic thyroidectomy or conventional open thyroidectomy. *Surg Laparosc Endosc Percutan Tech* 2015;25:436-9.

3. Lee KE, Choi JY, Youn YK. Bilateral axillo-breast approach robotic thyroidectomy. *Surg Laparosc Endosc Percutan Tech* 2011;21:230-6.

## Soft Tissue Reconstruction for Basaloid Squamous Cell Carcinoma on the Hemiface

Jae-Ho Chung, Hi-Jin You, Na-Hyun Hwang, Deok-Woo Kim

*Department of Plastic and Reconstructive Surgery, Korea University Medical Center, Korea University College of Medicine, Ansan, Korea*

**Correspondence:** Deok-Woo Kim  
Department of Plastic and Reconstructive Surgery, Korea University Ansan Hospital, Korea University College of Medicine, 123 Jeokeum-ro, Danwon-gu, Ansan 15355, Korea  
Tel: +82-31-412-4817, Fax: +82-31-475-5074  
E-mail: deokwookim@gmail.com

This material was presented, in part, at the 72nd International Congress of the Korean Society of Plastic and Reconstructive Surgeons on November 7-9, 2014 in Seoul, Korea

No potential conflict of interest relevant to this article was reported.

Received: 19 Feb 2016 • Revised: 28 Mar 2016 • Accepted: 4 Apr 2016  
pISSN: 2234-6163 • eISSN: 2234-6171  
<https://doi.org/10.5999/aps.2016.43.6.615>  
*Arch Plast Surg* 2016;43:615-618



Copyright © 2016 The Korean Society of Plastic and Reconstructive Surgeons  
This is an Open Access article distributed under the terms of the Creative Commons Attribution Non-Commercial License (<http://creativecommons.org/licenses/by-nc/4.0/>) which permits unrestricted non-commercial use, distribution, and reproduction in any medium, provided the original work is properly cited.

Basaloid squamous cell carcinoma (BSCC), a rare variant of squamous cell carcinoma, has rarely been reported and is poorly understood. It was first described as a distinct form of carcinoma in 1986 by Wain et al. [1] BSCC is believed to arise from a totipotent primitive cell in the basal layer of the surface epithelium or from the salivary duct lining epithelium. This uncommon malignancy usually appears in the head and neck region, especially in the supraglottic larynx, tongue base, and piriform sinus. However, extensive BSCC involving the whole hemiface is extremely rare.

Although numerous reconstruction techniques for the facial defect including orbital, nasal, labial, and maxillary have been described in the literature, reconstruction of large defects in this area continues to be challenging, as it is difficult to obtain satisfactory results. This case concerns an unusual