

## Fourth Recurrence of Cardiac Myxoma in a Patient with the Carney Complex

O Young Kwon, M.D., Gun Jik Kim, M.D., Woo Sung Jang, M.D., Ph.D.,  
Young Ok Lee, M.D., Jun Yong Cho, M.D., Jong Tae Lee, M.D.

Although cardiac myxoma is the most commonly encountered benign cardiac tumor in cardiac surgery practice, recurrent cardiac myxoma is very rare, is most commonly related to the Carney complex, and usually requires multiple cardiac operations with specific requirements in terms of perioperative management. In this report, we describe a patient who experienced the fourth recurrence of cardiac myxoma and review the diagnostic criteria of the Carney complex. This is the first report of such a case in Korea.

Key words: 1. Heart neoplasms  
2. Myxoma

### CASE REPORT

A 46-year-old woman presented to Kyungpook National University Hospital with a one-year history of chest discomfort and dyspnea, as well as a history of three operations for cardiac myxoma, including biatrial cardiac tumor resection in 1984, followed 10 years later by the resection of a recurrent left atrial and ventricular cardiac myxoma attached to the interatrial and interventricular septa. The first surgery, in 1984, was performed in our medical center. The myxoma and its pedicle attached to the fossa ovalis were excised via right atriotomy and left atriotomy with enclosure of the interatrial defect. The second surgery, in 1994, was also performed in our medical center. Through a right atriotomy, the interatrial septum was nearly totally excised and the myxoid mass was identified and excised. Also through aortotomy, a left ventricular myxoma on the interventricular septum below the right coronary cusp was identified and excised. Sixteen years

later, in 2010, the third such operation was performed in the same center. After the dissection of severe adhesion, a myxoma and its stalk on the inferior vena cava and right atrial junction were excised through a right atriotomy.

This patient also had a history of recurrent cutaneous and mucosal tumors, including forearm and nose tumors (diagnosed as myxomas based on excisional biopsies of tumors on her right forearm and right nostril), breast ductal adenoma (fibroadenomas diagnosed in her bilateral breasts through Mammotome excisional biopsies), and a uterine myoma, as well as a basilar artery aneurysm.

Chest computed tomography revealed a large soft tissue mass in the right atrial and ventricular cavities and findings suspicious of pulmonary embolism (Fig. 1A). An echocardiogram showed a 7.3-cm mobile right atrial mass (Fig. 1B).

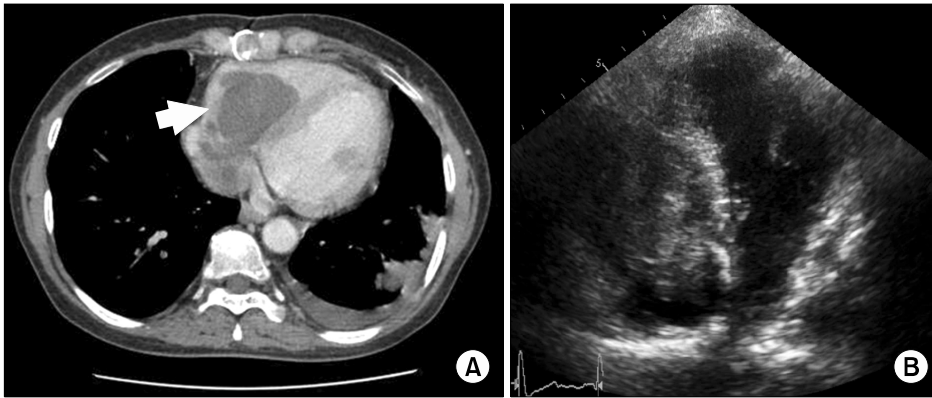
Two days later, with a presumptive diagnosis of recurrent cardiac myxoma, the patient underwent cardiac surgery through a median sternotomy. Aortic and venous cannulation,

Department of Thoracic and Cardiovascular Surgery, Kyungpook National University Hospital, Kyungpook National University School of Medicine  
Received: April 13, 2015, Revised: June 7, 2015, Accepted: June 8, 2015, Published online: April 5, 2016

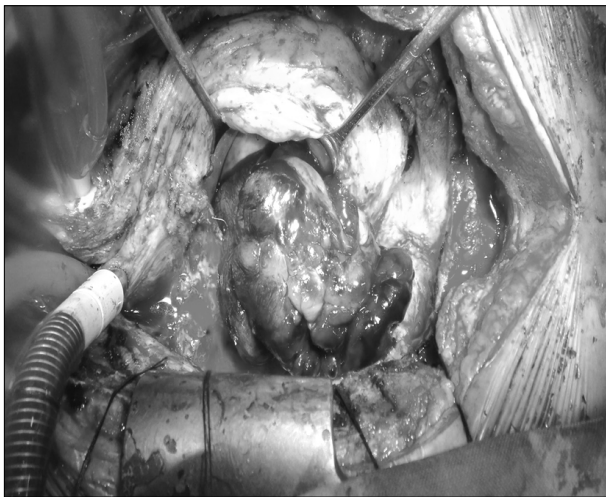
Corresponding author: Gun Jik Kim, Department of Thoracic and Cardiovascular Surgery, Kyungpook National University Hospital, Kyungpook National University School of Medicine, 130 Dongdeok-ro, Jung-gu, Daegu 41944, Korea  
(Tel) 82-53-200-6589 (Fax) 82-53-426-4765 (E-mail) [straightroot@knu.ac.kr](mailto:straightroot@knu.ac.kr)

© The Korean Society for Thoracic and Cardiovascular Surgery. 2016. All right reserved.

© This is an open access article distributed under the terms of the Creative Commons Attribution Non-Commercial License (<http://creativecommons.org/licenses/by-nc/4.0>) which permits unrestricted non-commercial use, distribution, and reproduction in any medium, provided the original work is properly cited.



**Fig. 1.** (A) Chest computed tomography and echocardiography revealed a 7.3-cm recurrent right atrial tumor (white arrow). (B) Two-dimensional echocardiography confirmed the presence of an intra-cardiac mass in the right atrium, extending to the right ventricle.



**Fig. 2.** The gelatinous cardiac tumor occupied the entire right atrial and ventricular cavities and was firmly attached to the right atrium-inferior vena cava junction.

the latter through the superior vena cava and right femoral vein, were performed for cardiopulmonary bypass. The large gelatinous tumor was visualized after right atriotomy; its stalk was located in the right atrium-inferior vena cava junction (Fig. 2) and the tumor occupied the entire right atrial and ventricular cavities. Moreover, the tumor involved part of the distal left pulmonary artery, leading to further pulmonary arteriotomy during surgery. The final pathological diagnosis was recurrent myxoma, with the tumor measuring 10.0×8.5×2.5 cm. Postoperatively, the patient's symptoms of dyspnea and chest discomfort resolved without complications, and the patient was discharged on postoperative day 9.

## DISCUSSION

After resection, cardiac myxoma, the most common benign cardiac tumor, rarely recurs, with a recurrence rate of approximately 3% observed in sporadic cases and a recurrence rate of 22% in patients with the Carney complex [1], an uncommon autosomal dominant hereditary disorder first described by Carney et al. [2] in 1985 [3,4]. The Carney complex, which manifests with cardiac, endocrine, cutaneous, and neural tumors and spotty pigmentation [5], is diagnosed when a patient exhibits either at least two main criteria, reflecting the manifestations of the disease, or one main criterion as well as one supplemental criterion associated with familial or hereditary features (Table 1) [6]. The patient presented in this report had a consistent history of cutaneous myxoma, breast ductal adenoma, and cardiac myxoma. This case of four recurrences of cardiac myxoma, the first of its kind to be reported in Korea, underscores the importance of performing a detailed investigation of patients with recurrent myxoma for the possibility of the Carney complex in order to facilitate better management, prognostication, and patient education regarding this condition.

**Table 1.** Diagnostic criteria for carney complex

	Content
Main criteria	<ol style="list-style-type: none"> <li>1. Spotty skin pigmentation with a typical distribution (lips, conjunctiva and inner or outer canthi, vaginal and penile mucosa)<sup>a)</sup></li> <li>2. Myxoma (cutaneous and mucosal)<sup>a)</sup></li> <li>3. Cardiac myxoma<sup>a)</sup></li> <li>4. Breast myxomatosis<sup>a)</sup> or fat-suppressed magnetic resonance imaging findings suggestive of this diagnosis</li> <li>5. Primary pigmented nodular adrenocortical disease<sup>a)</sup> or paradoxical positive response of urinary glucocorticosteroids to dexamethasone administration during Liddle's test</li> <li>6. Acromegaly due to GH-producing adenoma<sup>a)</sup></li> <li>7. Large-cell calcifying Sertoli cell tumor<sup>a)</sup> or characteristic calcification on testicular ultrasonography</li> <li>8. Thyroid carcinoma<sup>a)</sup> or multiple, hypoechoic nodules on thyroid ultrasonography, in a young patient</li> <li>9. Psammomatous melanotic schwannoma<sup>a)</sup></li> <li>10. Blue nevus, epithelioid blue nevus (multiple)<sup>a)</sup></li> <li>11. Breast ductal adenoma (multiple)<sup>a)</sup></li> <li>12. Osteochondromyxoma<sup>a)</sup></li> </ol>
Supplemental criteria	<ol style="list-style-type: none"> <li>1. Affected first-degree relative</li> <li>2. Inactivating mutation of the <i>PRKARIA</i> gene</li> </ol>

To make a diagnosis of Carney complex, a patient must exhibit either: (1) two of the manifestations of the disease listed or (2) one of these manifestations and meet one of the supplemental criteria (an affected first-degree relative or an inactivating mutation of the *PRKARIA* gene). From Stratakis, et al. *J Clin Endocrinol Metab* 2001;86:4041-6 [6].

<sup>a)</sup>With histologic confirmation.

## CONFLICT OF INTEREST

No potential conflict of interest relevant to this article was reported.

## REFERENCES

1. Mahilmaran A, Seshadri M, Nayar PG, Sudarsana G, Abraham KA. *Familial cardiac myxoma: Carney's complex*. *Tex Heart Inst J* 2003;30:80-2.
2. Carney JA, Gordon H, Carpenter PC, Shenoy BV, Go VL. *The complex of myxomas, spotty pigmentation, and endocrine overactivity*. *Medicine (Baltimore)* 1985;64:270-83.
3. Kirschner LS, Carney JA, Pack SD, et al. *Mutations of the gene encoding the protein kinase A type I-alpha regulatory subunit in patients with the Carney complex*. *Nat Genet* 2000;26:89-92.
4. Marina K, Vasiliki KE, George S, et al. *Recurrent cardiac myxoma in a 25 year old male: a DNA study*. *World J Surg Oncol* 2013;11:95.
5. Wilbring M, Wiedemann S, Kappert U, Matschke K. *A complicated case of Carney complex: fifth reoperative cardiac surgery for resection of recurrent cardiac myxoma*. *J Thorac Cardiovasc Surg* 2013;146:e22-4.
6. Stratakis CA, Kirschner LS, Carney JA. *Clinical and molecular features of the Carney complex: diagnostic criteria and recommendations for patient evaluation*. *J Clin Endocrinol Metab* 2001;86:4041-6.